

2011
Rush
Orthopedics Journal

EVERY ASPECT OF RUSH'S NEW, STATE-OF-THE-ART HOSPITAL, SCHEDULED TO OPEN IN JANUARY 2012, WILL HELP TO ENHANCE THE PATIENT EXPERIENCE AND IMPROVE THE QUALITY OF CARE.



Faculty Editors

Steven Gitelis, MD
Editor in Chief

David Fardon, MD
Brett Levine, MD
Robert W. Wysocki, MD

- 2 **Chairman's Letter**
- 4 **Orthopedic Faculty and Fellows (2010)**
- 9 **Research Faculty and Highlights**
- 14 **Department of Orthopedic Surgery Residents**
- 15 **Human Umbilical Cord Blood–Derived Mesenchymal Stem Cells for Intervertebral Disk Repair**
ANA CHEE, PHD; YEJIA ZHANG, MD, PHD; DESSLAVA MARKOVA, PHD; BIAGIO SAITTA, PHD; VLADIMIR MARKOV, MD; CHANDER GUPTA; HOWARD S. AN, MD
- 20 **Advances in Anterior Cruciate Ligament Reconstruction: A Quarter Century of Innovation at Rush University Medical Center**
MICHAEL B. ELLMAN, MD; RICHARD C. MATHER III, MD; SETH L. SHERMAN, MD; BERNARD R. BACH JR, MD
- 27 **Extranodal Rosai-Dorfman Disease With Isolated Osseous Involvement: An Unusual Case**
RICHARD W. KANG, MD; KEVIN C. MCGILL, MPH; JOHNNY LIN, MD; MICHELLE E. COLLIER, MD; STEVEN GITELIS, MD
- 32 **Idiopathic Glenohumeral Chondrolysis: A Case Report**
SHANE J. NHO, MD, MS; NICOLE A. FRIEL, MD, MS; BRIAN J. COLE, MD, MBA
- 37 **Reduced Scapular Notching Following Reverse Total Shoulder Arthroplasty: Clinical Results of a New Implant Design**
SETH L. SHERMAN, MD; BRETT A. LENART, MD; ERIC STRAUSS, MD; AMAN DHAWAN, MD; ERIC GOCHANOUR, MA; GREGORY P. NICHOLSON, MD
- 42 **Anterior Hip Pain in an Athletic Population: Differential Diagnosis and Treatment Options**
MARK A. SLABAUGH, MD; RACHEL M. FRANK, MD; ROBERT C. GRUMET, MD; PHIL MALLOY, MPT; CHARLES A. BUSH-JOSEPH, MD; WALTER W. VIRKUS, MD; SHANE J. NHO, MD, MS
- 52 **The Technique of Acetabular Distraction for the Reconstruction of Severe Acetabular Defects With an Associated Chronic Pelvic Discontinuity**
SCOTT M. SPORER, MD, MS; ANDREW MICHAEL, MD; WAYNE G. PAPROSKY, MD; MARIO MORIC, MS
- 58 **Select Publications (2010)**
- 65 **Select Research Grants (2009-2010)**
- 66 **Volume and Quality Data**
- 68 **Legacy of Excellence**
AN INTERVIEW WITH RENOWNED SPINE SURGEON GUNNAR B. J. ANDERSSON, MD, PHD, BY CHRISTOPHER DEWALD, MD

Chairman's Letter

2011 RUSH ORTHOPEDICS JOURNAL

From my office window, I've had the pleasure of watching Rush University Medical Center's new hospital building taking shape over the past 2 years. When the new hospital—located across the street from the Orthopedic Building—opens in January 2012, it will greatly enhance our ability to provide the highest quality of care for patients with orthopedic conditions.

The hospital will incorporate a concept called “the interventional platform,” with 3 floors devoted to surgery, imaging, and specialty procedures. It's a concept developed in recent years for academic medical centers where multiple medical and surgical specialists collaborate to treat patients with complex problems using the most advanced technologies available. The interventional platform at Rush features operating-procedure rooms, associated prep and recovery rooms, and support space. Each new and larger operating room—designed based on feedback from surgeons across numerous specialties, including orthopedics—will accommodate more specialized equipment and technology to improve outcomes.

Development has also continued within the Orthopedic Building. A new learning center was completed toward the end of 2010, providing a spacious, state-of-the-art venue for educational activities to complement our already impressive clinical and research facilities.

In the midst of these physical transformations, our physicians and researchers continued to break new ground in orthopedic care and research. Howard S. An, MD, and colleagues in the departments of orthopedic surgery and biochemistry received the prestigious 2011 Kappa Delta Elizabeth Winston Lanier Award from the American Academy of Orthopaedic Surgeons for a paper entitled “Intervertebral Disc Repair or Regeneration by Growth Factor and/or Cytokine Inhibitor Protein Injection.” Craig J. Della Valle, MD, was a co-recipient of the 2011 Frank Stinchfield Award from the Hip Society for investigations into dislocation following total hip replacement. And Gunnar B. J. Andersson, MD, PhD, received the 2010

Freedom of Movement Award from the Arthritis Foundation, Greater Chicago Chapter. See page 68 for an interview with Andersson, who preceded me as department chairman, in which he looks back on his illustrious career.

Members of the department have also recently ascended to key national leadership positions. I joined the presidential line of the American Academy of Orthopaedic Surgeons, serving as the second vice president; Howard S. An, MD, is the current president of the International Society for the Study of the Lumbar Spine; and Charles A. Bush-Joseph, MD, is the incoming president of the Major League Baseball Team Physician Association. In addition, Steven Gitelis, MD, editor in chief of this journal, was recently elected president of the medical staff of Rush University Medical Center.

Finally, I would be remiss if I didn't mention our outstanding residents and fellows, who came to Rush from across the United States and around the world to participate in our highly competitive training programs. Our faculty members value the contributions of residents and fellows to the care of our patients, and we are honored to be sharing our knowledge and skills with the next generation of orthopedic specialists.

I invite you to peruse this issue of the *Rush Orthopedics Journal* and enjoy a sampling of the stellar work produced by our department during the past year.



Joshua J. Jacobs, MD

The William A. Hark, MD/Susanne G. Swift
Professor of Orthopedic Surgery
Chairman, Department of Orthopedic Surgery
Rush University Medical Center

**“IN THE MIDST OF [RUSH’S] PHYSICAL TRANSFORMATIONS, OUR PHYSICIANS AND RESEARCHERS
CONTINUED TO BREAK NEW GROUND IN ORTHOPEDIC CARE AND RESEARCH.”**



Joshua J. Jacobs, MD (right),
with Markus A. Wimmer, PhD,
director of the Tribology Labo-
ratory and co-director of the
Motion Analysis Laboratory

ADULT RECONSTRUCTIVE SURGERY



Aaron Rosenberg, MD
Director, Section of Adult Reconstruction
Professor, Department of Orthopedic Surgery




Joshua J. Jacobs, MD
The William A. Hark, MD/Susanne G. Swift
Chair of Orthopedic Surgery
Chairman and professor, Department of
Orthopedic Surgery



Richard A. Berger, MD
Assistant professor, Department of
Orthopedic Surgery



Brett Levine, MD
Assistant professor, Department of
Orthopedic Surgery




Craig J. Della Valle, MD
Associate professor, Department
of Orthopedic Surgery
Director, Adult Reconstructive
Orthopedic Surgery Fellowship Program



Wayne G. Paprosky, MD
Professor, Department of
Orthopedic Surgery



Jorge O. Galante, MD, DMSc
The Grainger Directorship of the Rush
Arthritis and Orthopedics Institute
Professor, Department of Orthopedic Surgery



Scott M. Sporer, MD, MS
Assistant professor, Department of
Orthopedic Surgery

FELLOWS

Daniel Del Gaizo, MD
Medical school – George Washington University School of
Medicine and Health Sciences
Residency – University of North Carolina

Kurt Hirshorn, MD
Medical school – University of South Florida College of Medicine
Residency – Atlanta Medical Center

Jeremy Kinder, MD
Medical school – Rush Medical College
Residency – Northwestern Memorial Hospital

Trevor Murray, MD
Medical school – Case Western Reserve University Medical Center
Residency – Cleveland Clinic

Brian Pack, MD
Medical school – Wayne State University School of Medicine
Residency – Grand Rapids Medical Education and Research Center

Anand Srinivasan, MD
Medical school – Jefferson Medical College
Residency – Baylor University Medical Center

ELBOW, WRIST, AND HAND SURGERY



Mark S. Cohen, MD

Director, Section of Hand and Elbow Surgery
Professor, Department of Orthopedic Surgery



Robert Goldberg, MD

Instructor, Department of Orthopedic Surgery



John J. Fernandez, MD

Assistant professor, Department of
Orthopedic Surgery



Robert W. Wysocki, MD


Assistant professor, Department of
Orthopedic Surgery

FOOT AND ANKLE SURGERY




George Holmes Jr, MD

Director, Section of Foot and Ankle Surgery
Assistant professor, Department of
Orthopedic Surgery



Johnny L. Lin, MD

Assistant professor, Department of
Orthopedic Surgery



Simon Lee, MD

Assistant professor, Department of
Orthopedic Surgery

ONCOLOGY AND TRAUMA



Steven Gitelis, MD

Director, Section of Orthopedic Oncology
Rush Medical College Endowed Professor
of Orthopedic Oncology
Vice chairman and professor, Department
of Orthopedic Surgery



Walter W. Virkus, MD

Associate professor, Department of
Orthopedic Surgery
Director, Orthopedic Residency Program


PEDIATRIC SURGERY



Monica Kogan, MD

Director, Section of Pediatric Surgery
Assistant professor, Department of
Orthopedic Surgery

SPINE SURGERY



Howard S. An, MD

Director, Division of Spine Surgery
The Morton International Chair of
Orthopedic Surgery
Professor, Department of Orthopedic Surgery
Director, Spine Surgery Fellowship Program



Edward J. Goldberg, MD

Assistant professor, Department of
Orthopedic Surgery



Gunnar B. J. Andersson, MD, PhD

The Ronald L. DeWald, MD, Endowed
Chair in Spinal Deformities
Professor and chairman emeritus,
Department of Orthopedic Surgery



Kim W. Hammerberg, MD

Assistant professor, Department of
Orthopedic Surgery



Christopher DeWald, MD

Assistant professor, Department of
Orthopedic Surgery



Frank M. Phillips, MD

Director, Section of Minimally Invasive
Spine Surgery
Professor, Department of Orthopedic Surgery



David Fardon, MD

Associate professor, Department of
Orthopedic Surgery



Kern Singh, MD

Assistant professor, Department of
Orthopedic Surgery

FELLOWS

Kelley Banagan, MD

Medical school – SUNY Upstate Medical University
Residency – University of Maryland Medical Center

Thomas Cha, MD

Medical school – Drexel University College of Medicine
Residency – Columbia University Medical Center

Safdar Khan, MD

Medical school – Aga Khan University Medical College
Residency – Hospital for Special Surgery (research fellowship);
University of California Davis

Isaac Moss, MD

Medical school – McGill University Faculty of Medicine
Residency – University of Toronto Affiliated Hospitals

SPORTS MEDICINE, SURGERY



Bernard R. Bach Jr, MD

Director, Division of Sports Medicine
The Claude N. Lambert, MD/Helen S.
Thomson Chair of Orthopedic Surgery
Professor, Department of Orthopedic Surgery
Director, Sports Medicine Fellowship Program



Gregory Nicholson, MD

Associate professor, Department of
Orthopedic Surgery



Charles A. Bush-Joseph, MD

Professor, Department of Orthopedic Surgery



Anthony A. Romeo, MD

Director, Section of Shoulder and
Elbow Surgery
Professor, Department of Orthopedic Surgery




Brian J. Cole, MD, MBA

Director, Rush Cartilage Restoration Center
Professor, Department of Orthopedic Surgery



Nikhil N. Verma, MD

Assistant professor, Department of
Orthopedic Surgery



Shane J. Nho, MD, MS

Assistant professor, Department of
Orthopedic Surgery

FELLOWS

Aman Dhawan, MD

Medical school – Albany Medical College
Residency – Walter Reed Army Medical Center

Richard C. Mather III, MD

Medical school – Duke University School of Medicine
Residency – Duke University Medical Center

Neil Ghodadra, MD

Medical school – Duke University School of Medicine
Residency – Rush University Medical Center

Seth L. Sherman, MD

Medical school – Weill Cornell Medical College
Residency – Hospital for Special Surgery

SPORTS MEDICINE, PRIMARY CARE



Krystian Bigosinski, MD
Assistant professor, departments of family
medicine and orthopedic surgery



Jeffrey M. Mjaanes, MD
Assistant professor, departments of
orthopedic surgery and pediatrics



Joshua Blomgren, DO
Assistant professor, departments of family
medicine and orthopedic surgery



Kathleen M. Weber, MD
Director, primary care/sports medicine and
women's sports medicine programs
Assistant professor, Department of
Orthopedic Surgery

FELLOW

Anne Rettig, MD
Medical school – University of Virginia School of Medicine
Residency – Tufts Medical Center

THE ROBBINS AND JACOBS FAMILY BIOCOMPATIBILITY AND IMPLANT PATHOLOGY LABORATORY



Robert M. Urban

Director, the Robbins and Jacobs Family Biocompatibility and Implant Pathology Laboratory
Associate professor, Department of Orthopedic Surgery



Thomas M. Turner, DVM

Assistant professor, Department of Orthopedic Surgery




Deborah J. Hall

Instructor, Department of Orthopedic Surgery

The Robbins and Jacobs Family Biocompatibility and Implant Pathology Laboratory is concerned with the biocompatibility of materials used in reconstruction of bone and soft tissues, including metal alloys, synthetic polymers, and processed allografts and xenografts. The laboratory develops unique animal models to evaluate the efficacy of candidate biomaterials for reconstructions in spine, foot, and ankle, upper extremity, sports medicine, hip and knee replacement, and orthopedic oncologic surgery. Researchers in the lab also study implants and tissues obtained from patients at revision surgery and maintain a repository of many thousands of retrieved devices; these devices are evaluated for evidence of implant degradation, wear, and corrosion products, and their effects on host tissues. As part of the world's largest postmortem retrieval program for joint replacement, the lab focuses on the relationship between implant performance and the response of distant organs to systemic dissemination of degradation products. The laboratory has received numerous awards for its research in these areas.

BIOMATERIALS LABORATORY



Nadim J. Hallab, PhD

Director, Biomaterials Laboratory
Associate professor, Department of Orthopedic Surgery

Not pictured:

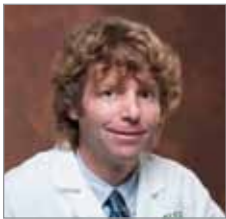Anastasia Skipor, MS, instructor, Department of Orthopedic Surgery

The Biomaterials Laboratory is focused on understanding implant debris and the biologic effects of this debris, including what types of implant debris are produced from implant wear and corrosion, how different types of debris interact with human biology and the immune system, how debris produces an immune response, and why immune reactivity to debris is so different from person to person. Answering these questions is critical to improving the long-term performance of orthopedic implants and is

continued on next page

the central mission of the laboratory. Over the past 10 years, the lab has made strides in 4 areas: establishing the theoretical basis for engineering surfaces for optimizing and directing cell bioreactivity; characterizing implant debris, including metal-protein complexes formed from implant degradation and their different inflammatory potentials; developing successful bench-to-bedside diagnostic testing of immune reactivity to implant debris, facilitating the evaluation of patients and different types of implants; and characterizing debris-specific effects on peri-implant cells—including establishing levels of toxic exposure for different cell types—and discovering new pathways by which implant debris exert proinflammatory effects (ie, inflammasome pathway).

MOTION ANALYSIS LABORATORY



Markus A. Wimmer, PhD
Co-director, Motion Analysis Laboratory
Director, Tribology Laboratory
Associate professor, Department of
Orthopedic Surgery



Hannah J. Lundberg, PhD
Instructor, Department of Orthopedic Surgery



Kharma C. Foucher, MD, PhD
Co-director, Motion Analysis Laboratory
Assistant professor, Department of
Orthopedic Surgery

The Motion Analysis Laboratory seeks, through its research and clinical activities, to improve the physical capabilities of patients with musculoskeletal ailments. The lab studies the functional performance of individuals during activities of daily living, measuring the kinematics and kinetics of natural and artificial joints. Current research foci involve exploring the pathomechanism of abnormal gait on osteoarthritic joints and developing rehabilitation strategies to either delay or halt the progression of cartilage wear. Primary equipment includes 12 optoelectronic cameras, and 5 Bertec force plates to record limb segment movements and moments. A 16-channel wireless electromyographic system helps to obtain insight into muscle activity. Strength- and balance-testing equipment and foot pressure measuring systems complement the state-of-the-art equipment.

SECTION OF ORTHOPEDIC ONCOLOGY



Carl Maki, PhD
Associate professor, Department of
Anatomy and Cell Biology



Qiping Zheng, PhD
Assistant professor, Department of
Anatomy and Cell Biology

A long-term research goal in the Section of Orthopedic Oncology has been to identify molecular mechanisms responsible for therapy resistance in osteosarcoma and other cancers, and then use this information to more effectively target resistant cells. Osteosarcoma is the most common malignant bone cancer in children. Current treatment includes aggressive preoperative and postoperative multidrug chemotherapy. Nonetheless, it is estimated that 30% of patients with localized disease and 80% of patients with

metastatic disease at diagnosis will relapse. Recurrent tumors are thought to arise from therapy-resistant cancer cells that survive the initial treatment. The tumor suppressor protein p53 is activated and triggers cell death pathways in response to DNA-damaging chemotherapeutic drugs. More than 50% of cancers harbor inactivating mutations in the p53 gene, and in many cases mutations in the p53 gene have been linked to a diminished response to chemotherapy. Determining the molecular basis for chemotherapy resistance should allow orthopedic oncologists to more effectively target these therapy-resistant cells.

SECTION OF MOLECULAR MEDICINE



Tibor T. Glant, MD, PhD
Director, Section of Molecular Medicine
The Jorge O. Galante, MD, DMSc, Chair in
Orthopaedic Surgery
Professor, Department of Orthopedic Surgery




Katalin Mikecz, MD, PhD
Professor, Department of Orthopedic Surgery

Not pictured:

Tibor A. Rauch, PhD, associate professor, Department of Orthopedic Surgery

The Section of Molecular Medicine employs state-of-the-art strategies and techniques in basic molecular biology, biochemistry, genetics, cell biology, and immunology to conduct leading-edge research. Current studies focus on the autoimmune mechanisms of rheumatoid arthritis, including the screening, identification, and localization of “disease-susceptible” genes that control autoimmune processes and inflammatory cell migration into the synovium; the autoimmune mechanisms of ankylosing spondylitis, including the screening, identification, and localization of “disease-susceptible” genes in a corresponding animal model; and the immunology/immunopathology and genetics of extracellular matrix components (specifically cartilage macromolecules). Researchers in the section are also studying the functional and pathophysiological importance of specific domains of cartilage aggrecan, link protein, and small proteoglycans using targeted disruption (knockout) and overexpression of these molecules in mice. Based on this work, they have developed a mouse model of osteoarthritis. Another area of interest is the cellular and molecular (signaling) mechanisms of pathological bone resorption in failed total hip arthroplasties, which include (1) particle-induced cellular responses and signaling mechanisms of macrophages, osteoblasts, and periprosthetic fibroblasts and (2) epigenomic alterations of gene expression involved in pathological bone resorption and bone remodeling. Researchers are also looking at myeloproliferative diseases associated directly or indirectly with pyoderma gangrenosum or Sweet’s syndrome, two relatively rare skin diseases with unknown etiology.

SPINE BIOLOGY LABORATORY



Nozomu Inoue, MD, PhD
Professor, Department of Orthopedic Surgery



Yejia Zhang, MD, PhD
Assistant professor, Department of
Orthopedic Surgery

The goal of research in the Spine Biology Laboratory is to improve the understanding of intervertebral disk biology and the pathophysiology of intervertebral disk degeneration so that patients with low back pain can be better diagnosed and treated with

continued on next page

more effective and less invasive methods. Over the past 10-15 years, the lab has tested candidate therapeutic agents using in vitro cell culture models, organ culture models, and in vivo animal models of intervertebral disk degeneration to assess their potential to assist in matrix restoration and perhaps to reduce diskogenic low back pain. Injection of the bone morphogenetic proteins BMP-7 and BMP-14 in a rabbit model was shown to be effective in restoring intervertebral disk height, MRI signals of the disk, biochemical matrix contents, and biomechanical properties. Based on these preclinical data, the FDA has allowed investigational new drug clinical trials to begin in the United States. This groundbreaking work was recognized in 2011 when Howard S. An, MD, and colleagues in the departments of orthopedic surgery and biochemistry received the Kappa Delta Elizabeth Winston Lanier Award for a paper entitled “Intervertebral Disc Repair or Regeneration by Growth Factor and/or Cytokine Inhibitor Protein Injection.” The lab’s ongoing work involves testing other candidate molecules to regenerate degenerated intervertebral disks, while focusing on pain-mediated molecules associated with degeneration.

SPINE BIOMECHANICS LABORATORY




Raghu N. Natarajan, PhD
Professor, Department of Orthopedic Surgery



Alejandro A. Espinoza Orías, PhD
Instructor, Department of Orthopedic Surgery

The Spine Biomechanics Laboratory has developed analysis software to determine subtle and coupled spinal motion patterns that the facet joints and disks exhibit in vivo. CT/MRI data are reconstructed into high-resolution, 3-dimensional models that offer a variety of geometric characterization options. In vitro validation of spinal motion models is carried out at the laboratory using a spine testing frame newly developed in house and driven by a servo-hydraulic materials testing machine. Motion of the cadaveric specimens is captured in real time by infrared cameras, thus fully characterizing the spinal kinematics. The frame is also capable of testing the effects of spinal instrumentation and devices on spinal kinematics. Computer models of the human spine are being used in the lab to understand changes in spinal kinematics due to surgical procedures performed on the lumbar and cervical spines, including fusion and motion preservation systems. Computer models are also being used to understand the effects of various tears and clefts formed during the disk degeneration process.

SPORTS MEDICINE RESEARCH LABORATORY

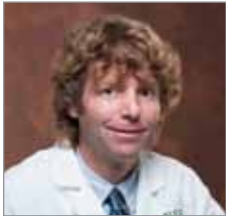

Vincent M. Wang, PhD
Director, Sports Medicine Research Laboratory
Assistant professor, Department of
Orthopedic Surgery

The primary research focus of the Sports Medicine Research Laboratory is the structure, function, injury, and repair of soft connective skeletal tissues (tendon, ligament, cartilage, and meniscus) and diarthrodial joints (particularly knee and shoulder). Ongoing investigations include quantitative, 3-dimensional anatomic studies for the refinement of surgical techniques

(eg, orientation of bone tunnels for anterior cruciate ligament [ACL] reconstruction); comparative biomechanical studies of stability and strength conferred by various surgical techniques (eg, rotator cuff repair, ACL reconstruction); assessment of microscopic, biologic, and biomechanical properties of normal, injured, and healing musculoskeletal soft tissues (eg, to assess roles of specific tissue matrix proteins, surgical repair techniques, or therapeutics on the quality of healing); and development and application of noninvasive imaging techniques for quantitative assessment of tissue integrity.

TRIBOLOGY LABORATORY



Markus A. Wimmer, PhD
Director, Tribology Laboratory
Co-director, Motion Analysis Laboratory
Associate professor, Department of
Orthopedic Surgery



Alfons Fischer, PhD
Visiting professor, Department of
Orthopedic Surgery



Mathew T. Mathew, PhD
Instructor, Department of Orthopedic Surgery

Not pictured:

Michel Laurent, PhD, scientist, Department of Orthopedic Surgery

The goal of the Tribology Laboratory is to contribute to long-lasting treatment solutions for the osteoarthritic joint. Researchers in the lab apply the physical principles of friction, wear, and lubrication to natural and artificial joints to improve both the material properties of implants and the patient's well-being. Although their main focus is artificial implants, researchers in the lab also apply "tribological thinking" to natural tissues in an effort to better understand the effects of loading and motion on living structures. The laboratory is equipped with advanced equipment that includes a knee simulator and a hip/spine simulator for testing prosthetic joint bearing couples under physiological conditions; a custom-built bioreactor to test live cartilage; a pin-on-disk apparatus for screening bearing materials; and specifically dedicated hydraulic, pneumatic, and electromechanical machines to test biomaterial properties. The laboratory also features a retrieval analysis suite with a state-of-the-art interferometric microscope for surface topographical characterization, a coordinate measuring machine with micron-range precision for implant geometrical measurements, and access to a scanning electron microscope with environmental capabilities.

Department of Orthopedic Surgery Residents

2011 RUSH ORTHOPEDICS JOURNAL

□ **Laith M. Al-Shihabi, MD**

Medical school – Medical College of Wisconsin

□ **Christopher Bayne, MD**

Medical school – Harvard Medical School

□ **Sanjeev Bhatia, MD**

Medical school – Northwestern University Feinberg School of Medicine

□ **Debdut Biswas, MD**

Medical school – Yale University School of Medicine

□ **Brian R. Braaksma, MD**

Medical school – Columbia University College of Physicians and Surgeons

□ **Peter N. Chalmers, MD**

Medical school – Columbia University College of Physicians and Surgeons

□ **Cara A. Cipriano, MD**

Medical school – University of Pennsylvania School of Medicine

□ **Michael Ellman, MD**

Medical school – University of Michigan Medical School

□ **Amir-Kianoosh Fallahi, MD**

Medical school – Wayne State University School of Medicine

□ **Jonathan M. Frank, MD**

Medical school – University of California Los Angeles Geffen School of Medicine

□ **Nickolas G. Garbis, MD**

Medical school – University of Illinois College of Medicine at Chicago

□ **James Gregory, MD**

Medical school – University of Pennsylvania School of Medicine

□ **Christopher Gross, MD**

Medical school – Harvard Medical School

□ **Andrew Hsu, MD**

Medical school – Stanford University School of Medicine

□ **Richard W. Kang, MD**

Medical school – Rush Medical College

□ **Brett A. Lenart, MD**

Medical school – Weill Cornell Medical College

□ **Paul B. Lewis, MD**

Medical school – Rush Medical College

□ **Sameer J. Lodha, MD**

Medical school – Washington University School of Medicine

□ **Samuel A. McArthur, MD**

Medical school – Uniformed Services University Hébert School of Medicine

□ **Kevin Park, MD**

Medical school – Tulane University School of Medicine

□ **Sanjai K. Shukla, MD**

Medical school – Duke University School of Medicine

□ **William Slikker III, MD**

Medical school – Stanford University School of Medicine

□ **Geoffrey S. Van Thiel, MD**

Medical school – University of California Los Angeles Geffen School of Medicine

□ **David M. Walton, MD**

Medical school – Case Western Reserve University School of Medicine

□ **Adam Yanke, MD**

Medical school – Rush Medical College ■

Human Umbilical Cord Blood–Derived Mesenchymal Stem Cells for Intervertebral Disk Repair

ANA CHEE, PHD; YEJIA ZHANG, MD, PHD; DESSLAVA MARKOVA, PHD; BIAGIO SAITTA, PHD;
VLADIMIR MARKOV, MD; CHANDER GUPTA; HOWARD S. AN, MD

“OUR INITIAL STUDIES HAVE SHOWN THAT TRANSPLANTED STEM CELLS SURVIVE AND EXPRESS THE HUMAN TYPE II COLLAGEN GENE, A MARKER SHOWING THAT THE STEM CELLS ARE HELPING TO REPAIR THE DISK.”

□ Author Affiliations

Department of Orthopedic Surgery, Rush University Medical Center, Chicago, Illinois (Drs Chee, Zhang, and An); Department of Rehabilitation Medicine, Thomas Jefferson University, Philadelphia, Pennsylvania (Drs Markova and Markov and Mr Gupta); and Department of Cell Biology, School of Osteopathic Medicine, University of Medicine and Dentistry of New Jersey, Stratford, New Jersey (Dr Saitta).

□ Corresponding Author

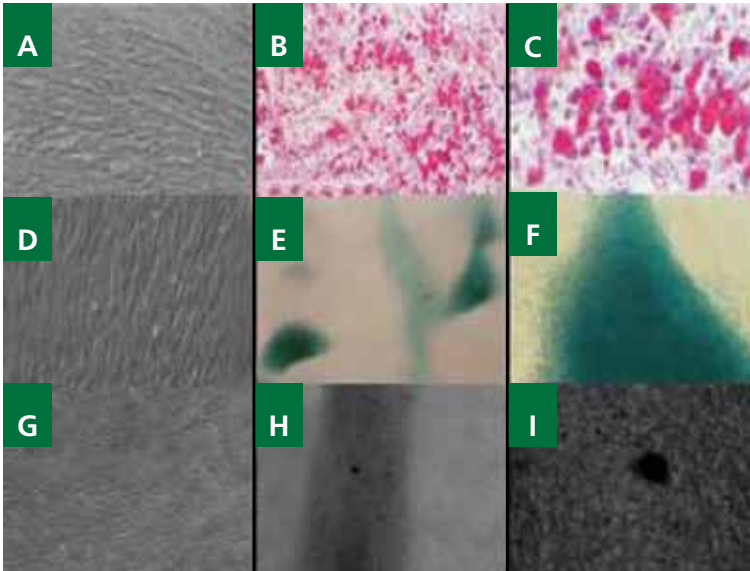
Ana Chee, PhD; Rush University Medical Center, 1653 W Congress Pkwy, Chicago, IL 60612 (ana_chee@rush.edu).

□ Introduction

Scientists and clinicians have found that stem cells can differentiate into a variety of cell types and therefore can provide therapeutic effects for many human diseases. For the last 20 years, research and clinical trials using umbilical cord blood cells have shown promise in treating a large number of hematologic diseases and a smaller number of nonhematologic diseases. Unlike embryonic stem cells, human neonatal umbilical cord blood–derived mesenchymal stem cells (hUCB-MSCs) are taken from donated umbilical cord tissue samples after birth with no harm to the mother or the newborn, and therefore their research is not subject to the ethical

and political debate surrounding embryonic stem cell research. Mesenchymal stem cells (MSCs) are self-renewing cells that exhibit multilineage differentiation into bone, cartilage, fat, and muscle.¹⁻⁵ Studies have shown that classic mesenchymal stem cells are capable of differentiating into cells of connective tissue lineages such as osteogenic, adipogenic, and chondrogenic lineages.⁶⁻⁹ Human UCB-MSCs can be cultured in specialized media and induced to differentiate into classic mesenchymal lineages (adipogenic, chondrogenic, and osteogenic) (Figure 1). Compared to adult mesenchymal stem cell transplantation, umbilical cord blood stem cell transplantation allows for more human leukocyte antigen (HLA) disparity, thus requiring less stringent matching between donor and recipient.^{10,11} Umbilical cord blood stem cells are less mature than adult bone marrow–derived MSCs and thus have a larger capacity to survive and replicate. To date, hUCB-MSCs have become a widely accepted source of hematopoietic stem cells: they have been used in transplants to treat a number of hematopoietic and malignant diseases,¹² including Buerger’s disease and chronic spinal cord injury.^{13,14} Our lab is exploring the use of hUCB-MSCs as a therapy for lower lumbar spondylosis and associated diseases by testing the therapeutic effects of hUCB-MSCs on degenerating rabbit intervertebral disk explant cultures.

Figure 1. Human umbilical cord blood–derived mesenchymal stem cells undergo adipogenic (B, C; fat stained red), chondrogenic (E, F; proteoglycan rich matrix stained blue), and osteogenic differentiation (H, I; calcified matrix stained black). Undifferentiated control cells were negative for staining (A, D, G).



□ Back Pain Therapy

Back pain and neck pain are common clinical problems,¹⁵ and in many affected patients, degenerative disk disease has been identified as a significant contributing factor. The etiology of disk degeneration is complex. Among the risk factors are genetic predisposition and biomechanical properties.¹⁶ Viable disk cells decrease in number in the degenerative disk, most likely due to apoptosis.¹⁷ Proteolytic enzymes are found at higher concentrations in degenerative disks than in normal disks¹⁸⁻²⁰ along with increased levels of proinflammatory cytokines,^{18,19} molecules that promote loss of matrix homeostasis by suppressing matrix synthesis/repair and promoting matrix degradation. Improved extracellular matrix production or decreased matrix degradation can be achieved by a variety of methods, for example, by stimulating disk cells with growth factors, inhibiting proinflammatory cytokines, or inhibiting proteolytic enzymes. However, at late stages of disk degeneration when the number of viable cells is low, repopulating the disk with cells that could produce and maintain extracellular matrix may be desirable.

As an alternative to the surgical removal of the diseased disk, cell therapy may be a promising option to help reduce disk degeneration, restore function, and reduce back pain. As a first step, our research group has studied the therapeutic effects of the transplantation of donated hUCB-MSCs into rabbit degenerating disk explant cultures. Our initial studies have shown that transplanted

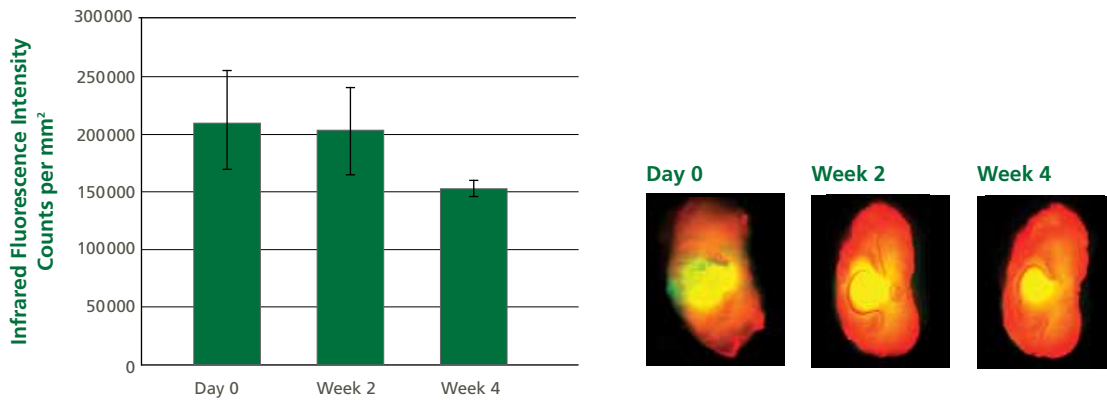
stem cells survive and express the human type II collagen gene, a marker showing that the stem cells are helping to repair the disk. Also, the stem cells can stimulate the resident disk cells to help repair the disk by expressing higher levels of rabbit type II collagen gene and lower levels of the matrix metalloproteinase 13 gene, a marker for disk degeneration. With improved extracellular matrix production and decreased matrix degradation, the stem cells have a positive therapeutic effect on the disk homeostasis.

□ Results

Stem Cell Survival in Rabbit Disk Culture

Human umbilical cord blood stem cells were stained with CellVue NIR815 Fluorescent dye (LI-COR, Lincoln, Nebraska) so they could be tracked within an intervertebral disk explant. Labeled hUCB-MSCs were transplanted into cultured rabbit intervertebral disk explants and continued to fluoresce green after a 1-month culture period (Figure 2, lower panel). When a noninjected rabbit disk is scanned, it typically has red background fluorescence. However, when the images are overlapped, the combination of the green fluorescing stem cells transplanted in red fluorescing rabbit disk has a yellow fluorescent appearance, which is a clear indication that the stem cells are transplanted. The fluorescent color from the same disks diminishes only slightly throughout the 4-week culture period, which may relate to natural fading of the dye or stem cell death (Figure 2, upper panel).

Figure 2. Human umbilical cord stem cells survive after transplantation into rabbit intervertebral disk explant culture for 1 month. **Right panel,** Rabbit disk transplanted with fluorescently labeled human umbilical cord blood cells and cultured and scanned for up to 4 weeks. **Left panel,** Intensity of the fluorescence of cells in the disk. Error bars indicate the standard deviation.



Expression of Disk Repair Genes After Stem Cell Transplantation

We subsequently tested (1) if hUCB-MSC can differentiate into chondrocyte-like cells capable of making extracellular matrix (using reverse transcription PCR) and (2) if hUCB-MSC can stimulate resident disk cells to express higher levels of extracellular matrix genes and lower levels of proteolytic enzymes (using real-time PCR). After a 1-month culture period, total cellular RNA was extracted from disk explant tissues. Stem cells cultured in a mono-

layer do not express human type II collagen mRNA (Figure 3, left panel, lane 1); human type II collagen gene was expressed in rabbit disk explants transplanted with hUCB-MSCs (Figure 3, left panel, lane 3). The ratios of the intensities of human type II collagen bands to glyceraldehyde-3-phosphate dehydrogenase (GAPDH) bands were quantified and are shown in the right panel of Figure 3.

Using real-time PCR, we were able to detect a 2-fold increase in expression of rabbit type II collagen mRNA (Figure 4, left panel)

Figure 3. Human type II collagen gene expression in rabbit organ culture by reverse transcription PCR. **Left panel,** Semiquantitative reverse transcription PCR was performed with custom designed primers for human type II collagen, human glyceraldehyde-3-phosphate dehydrogenase (hGAPDH), and rabbit GAPDH (rGAPDH). **Right panel,** The ratio of intensities of human type II collagen bands to GAPDH bands.

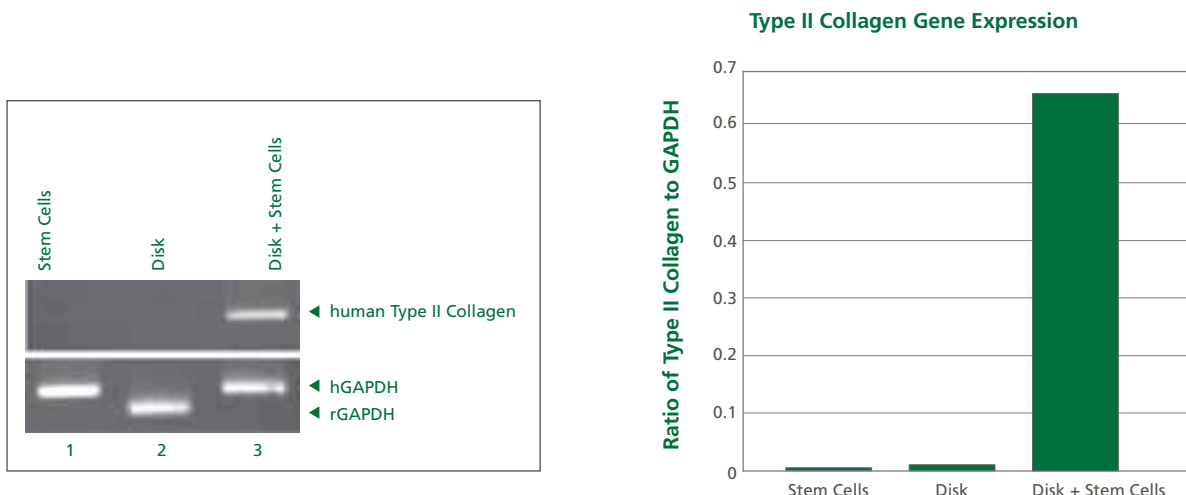
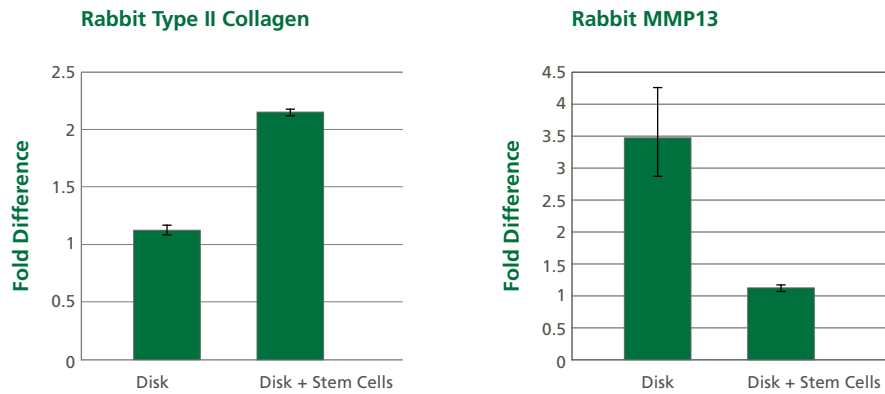


Figure 4. Rabbit type II collagen and matrix metalloproteinase 13 (MMP13) gene expression in rabbit organ culture by real-time PCR. After 1 month of culture, RNA was isolated from rabbit disk transplanted with stem cells and compared to RNA from the noninjected disk. Real-time PCR was performed using Taqman assays specific for rabbit type II collagen (left panel) and rabbit matrix metalloproteinase 13 (right panel). Error bars indicate the standard deviation.



and a 3-fold decrease in expression of rabbit matrix metalloproteinase 13 mRNA (Figure 4, right panel) in stem cell transplanted intervertebral disks when compared to noninjected intervertebral disks. This indicates that the intervertebral disks transplanted with stem cells are undergoing a reparative process.

□ Future Directions

Our research team is in a unique position to develop novel biological treatment strategies for disk degeneration given that we have formed close collaborations between clinicians and molecular and cell biologists. At early and intermediate stages of disk degeneration, growth factor therapy may be sufficient to induce resident cells to repair their own matrix and disk structure. At advanced stages of disk degeneration, disks have a smaller population of resident disk cells, due to cell death, and therefore growth factor therapies may not be effective. In order to reverse disk degeneration and restore function, cell transplantation into the severely degenerative disks would be needed to help repopulate the disk with viable cells. Human umbilical cord blood transplantation has been used to treat a number of hematological malignancies. Our preliminary in vitro studies have shown that cell therapy with hUCB-MSCs for disk degeneration is very promising. We have tracked transplanted hUCB-MSCs in the disk environment, and these cells have been able to survive and differentiate. Cells transplanted into a rabbit disk explant culture express genes to help repair the disk and also stimulate resident disk cells to express genes that will help restore disk function.

Before this therapy can undergo clinical trials, the hUCB-MSC cell therapy would need to be validated in an in vivo animal model. Our group has developed a rabbit disk degeneration model to study the biological mechanisms of disk degeneration and to test therapeutics for disk regeneration, which has become a standard model in the disk degeneration field. Using our expertise in understanding the biology of disk degeneration and the promising tools of cell therapy, we hope these studies will lay the groundwork to make hUCB-MSCs a promising treatment option for patients with severe disk degeneration and back pain. ■

References

1. Friedenstein AJ, Gorskaja JE, Kulagina NN. Fibroblast precursors in normal and irradiated mouse hematopoietic organs. *Exp Hematol.* 1976;4(5):267-274.
2. Pittenger MF, Mackay AM, Beck SC, et al. Multilineage potential of adult human mesenchymal stem cells. *Science.* 1999;284(5411):143-147.
3. Deans RJ, Moseley AB. Mesenchymal stem cells: biology and potential clinical uses. *Exp Hematol.* 2000;28(8):875-884.
4. Baksh D, Song L, Tuan RS. Adult mesenchymal stem cells: characterization, differentiation, and application in cell and gene therapy. *J Cell Mol Med.* 2004;8(3):301-316.
5. Lin Z, Willers C, Xu J, Zheng MH. The chondrocyte: biology and clinical application. *Tissue Eng.* 2006;12(7):1971-1984.
6. Lee OK, Kuo TK, Chen WM, Lee KD, Hsieh SL, Chen TH. Isolation of multipotent mesenchymal stem cells from umbilical cord blood. *Blood.* 2004;103(5):1669-1675.
7. Kogler G, Sensken S, Airey JA, et al. A new human somatic stem cell from placental cord blood with intrinsic pluripotent differentiation potential. *J Exp Med.* 2004;200(2):123-135.

8. Bieback K, Kern S, Klüter H, Eichler H. Critical parameters for the isolation of mesenchymal stem cells from umbilical cord blood. *Stem Cells*. 2004;22(4):625-634.
9. Lee MW, Choi J, Yang MS, et al. Mesenchymal stem cells from cryo-preserved human umbilical cord blood. *Biochem Biophys Res Commun*. 2004;320(1):273-278.
10. Kurtzberg J, Laughlin M, Graham ML, et al. Placental blood as a source of hematopoietic stem cells for transplantation into unrelated recipients. *N Engl J Med*. 1996;335(3):157-166.
11. Wagner JE, Rosenthal J, Sweetman R, et al. Successful transplantation of HLA-matched and HLA-mismatched umbilical cord blood from unrelated donors: analysis of engraftment and acute graft-versus-host disease. *Blood*. 1996;88(3):795-802.
12. Gluckman E. Ten years of cord blood transplantation: from bench to bedside. *Br J Haematol*. 2009;147(2):192-199.
13. Kim SW, Han H, Chae GT, et al. Successful stem cell therapy using umbilical cord blood-derived multipotent stem cells for Buerger's disease and ischemic limb disease animal model. *Stem Cells*. 2006;24(6):1620-1626.
14. Kang KS, Kim SW, Oh YH, et al. A 37-year-old spinal cord-injured female patient, transplanted of multipotent stem cells from human UC blood, with improved sensory perception and mobility, both functionally and morphologically: a case study. *Cytotherapy*. 2005;7(4):368-373.
15. American Academy of Orthopaedic Surgeons. *Burden of Musculoskeletal Diseases in the United States: Prevalence, Societal and Economic Cost*. Rosemont, IL: American Academy of Orthopaedic Surgeons; 2008.
16. Anderson DG, Tannoury C. Molecular pathogenic factors in symptomatic disc degeneration. *Spine J*. 2005;5(6)(suppl):260S-266S.
17. Gruber HE, Hanley EN Jr. Analysis of aging and degeneration of the human intervertebral disc: comparison of surgical specimens with normal controls. *Spine (Phila Pa 1976)*. 1998;23(7):751-757.
18. Kang JD, Georgescu HI, McIntyre-Larkin L, Stefanovic-Racic M, Donaldson WF III, Evans CH. Herniated lumbar intervertebral discs spontaneously produce matrix metalloproteinases, nitric oxide, interleukin-6, and prostaglandin E2. *Spine (Phila Pa 1976)*. 1996;21(3):271-277.
19. Kang JD, Georgescu HI, McIntyre-Larkin L, Stefanovic-Racic M, Evans CH. Herniated cervical intervertebral discs spontaneously produce matrix metalloproteinases, nitric oxide, interleukin-6, and prostaglandin E2. *Spine (Phila Pa 1976)*. 1995;20(22):2373-2378.
20. Gruber HE, Ingram JA, Hanley EN Jr. Immunolocalization of MMP-19 in the human intervertebral disc: implications for disc aging and degeneration. *Biotech Histochem*. 2005;80(3-4):157-162.

Advances in Anterior Cruciate Ligament Reconstruction: A Quarter Century of Innovation at Rush University Medical Center

MICHAEL B. ELLMAN, MD; RICHARD C. MATHER III, MD; SETH L. SHERMAN, MD; BERNARD R. BACH JR, MD

“OVER THE PAST QUARTER CENTURY AT RUSH, ANATOMIC, BIOMECHANICAL, AND CLINICAL STUDIES HAVE PAVED THE WAY FOR VAST IMPROVEMENTS IN DIAGNOSIS, SURGICAL TREATMENT, AND POSTOPERATIVE REHABILITATION OF PATIENTS WITH ACL DEFICIENCY.”

□ Author Affiliations

Department of Orthopedic Surgery (Dr Ellman), and Division of Sports Medicine, Department of Orthopedic Surgery (Drs Mather, Sherman, and Bach), Rush University Medical Center, Chicago, Illinois.

□ Corresponding Author

Bernard R. Bach Jr, MD; Rush University Medical Center, 1611 W Harrison St, Suite 300, Chicago, IL 60612 (bbach@rushortho.com).

□ Introduction

Anterior cruciate ligament (ACL) reconstruction is widely accepted as the treatment of choice for patients with functional instability due to an ACL-deficient knee. It is currently estimated that more than 100,000 primary ACL reconstructions (ACLRs) are performed annually in the United States.¹ Since 1986, the senior author (B.R.B. Jr) has performed over 2,000 primary and revision ACL reconstructions. During this time, research at Rush on ACL injury has resulted in 120 peer-reviewed publications, 46 book chapters, and 12 monographs and textbooks authored on topics specific to the ACL (Table 1). Clinical diagnosis, surgical treatment, and postoperative management of ACL rupture have evolved considerably, resulting in predictably excellent clinical results following ACLR with high patient subjective satisfaction scores.

At Rush, abundant research dedicated to an improved understanding of the basic anatomy, biomechanics, graft characteristics and function (including graft fixation, healing, tensioning, and remodeling), and surgical technique related to the ACL has resulted in improved clinical outcomes and decreased postoperative morbidity. Further, a greater understanding of the optimal timing for surgery, coupled with an emphasis on aggressive postoperative rehabilitation including patellar mobilization, hyperextension recovery, and full weight bearing, has helped provide the framework for ACL treatment today. While a thorough overview of the extensive contributions from Rush to the ACL literature is beyond the scope of this review, we will summarize many of the major advances in ACLR, emphasizing the influence of Rush during the past 25 years (Table 1).

□ From the Laboratory to Clinical Practice

A greater understanding of the ACL at its most basic level has allowed for significant advances in clinical diagnosis and management. Anatomically, the ACL is an intra-articular structure originating from the medial aspect of the posterior lateral femoral condyle and inserting onto the tibial plateau between the anterior horns of the medial and lateral menisci.^{2,3} It is composed of an anteromedial bundle and a posterolateral bundle that function to prevent anteroposterior and rotatory instability, respectively. Early biomechanical gait analysis studies at Rush demonstrated a

Table 1. Summary of Rush Research on ACL Treatment Over 25 Years

Anatomic Footprint Study of the ACL Femoral Insertion	Magnetic Resonance Imaging (MRI) Correlation of Patient Height and Patellar Tendon Length: Implications for Sizing Allografts to Reduce Graft Tunnel Mismatch
Avoiding Complications in ACL Surgery	Neural Anatomy of the ACL
Biomechanical Aspects of Hamstring Graft Fixation	Pearls and Pitfalls of BTB Graft Harvest
Biomechanical Aspects of Interference Screw Diversion	Perioperative Pain and Analgesic Usage Following Outpatient ACL Surgery
Biomechanical Aspects of Interference Screw Fixation	Primary Bone Grafting of the Distal Patellar Defect
Biomechanical Aspects of Low-Dose Irradiated Allografts	Radiographic Observations of Interference Screw Morphologies
Biomechanical Aspects of Multiple Freeze-Thaw Cycles on Bone-Patellar Tendon-Bone (BTB) Allografts	Recognition of Posterior Wall Blowout: Techniques for Avoidance, Recognition, and Treatment
Biomechanical Aspects of Screw Post Versus Free Bone Block Fixation for Graft Tunnel Mismatch	Revision ACL Surgery: Technical Considerations
Biomechanical Comparison of Outside-in and Inside-out Interference Screw Fixation	Strategies for Successful Outpatient Surgery
Biomechanical Comparisons of 1-, 2-, and 4-Strand Hamstring Grafts on Fixation	Surgical Results in the Skeletally Immature Adolescent Using Hamstring Allografts
Charge Comparisons of Outpatient Versus Inpatient ACL Surgery	Surgical Results of ACL Reconstruction in Patients Over the Age of 35
Do Smaller Tibial Tunnel Sizes Impact Ability to Perform Anatomic ACL Reconstruction?	Surgical Results of ACL Reconstruction in the Worker's Compensation Patient Population
Dynamic Function Following ACL Surgery: Biomechanical Gait Analysis	Surgical Results of ACL Reconstruction: Gender Comparisons
Effects of ACL Injury on Gait Analysis	Surgical Results of Endoscopic ACL Reconstruction: Minimum 2-Year Follow-up
Effects of Donor Age on Bone Mineral Density in BTB Allografts	Surgical Results of Revision ACL Reconstruction
Functional Gait Adaptation Over Time	Surgical Results of 2-Incision Arthroscopic ACL Reconstruction: Minimum 2-Year Follow-up
Gait Analysis Following ACL Reconstruction	Surgical Technique of ACL Reconstruction in the Skeletally Immature Adolescent
Illustrated History of ACL Surgery	Surgical Techniques of Arthroscopic-Assisted ACL Reconstruction: 2-Incision Technique
Intra-articular Biochemical Markers in ACL Injury	Surgical Techniques of Endoscopic ACL Reconstruction
KT1000 Assessment of Autografts Versus Allografts: Do Grafts Stretch During the First Year?	Systematic Review of Single-Bundle ACL Reconstruction Outcomes
KT1000 Comparison of ACL-Deficient Patients Awake Versus Examination Under Anesthesia (EUA)	Treatment of Arthrofibrosis Following ACL Surgery
KT1000 Parameters of ACL Reconstruction	Treatment of Patellar Tendon Rupture Following ACL BTB Reconstruction
Management of Partial ACL Injuries	
Management of Tunnel Malposition and Expansion in Revision ACL Surgery	
Meta-analysis of Patellar Tendon Versus Hamstring Grafts	

pivotal role of the ACL in the gait cycle, as ACL-deficient (ACLD) patients develop “quad avoidance” and “hamstring overuse” gait abnormalities.^{4,5} These patterns were found to be increasingly time-dependent and adopted by the contralateral normal knee as well, significantly affecting the patient’s gait cycle. After ACLR, how-

ever, gait patterns returned to normal. Other studies evaluated the dynamic aspects of the ACLD and ACL-reconstructed knee in cutting and crosscutting maneuvers and helped to predict the natural history of ACL rupture over time.^{6,7} Further collaboration with the biomechanical department resulted in extensive research analyzing

several aspects of ACL graft fixation, including the effects of interference screw fixation on failure characteristics,^{8,9} outside-in versus inside-out screw fixation,¹⁰ free bone block fixation compared to traditional screw post fixation,⁸ graft rotation on ultimate and cyclic loading,^{11,12} the use of 1-, 2-, and 4-stranded allografts,¹³ the effects of freeze-thaw cycles on grafts,¹⁴ and the effects of donor age on bone mineral density in irradiated (1 mR) allografts.¹⁵

Clinically, it is widely recognized that the most common reason for ACL failure following primary ACLR is technical error due to improper placement of the tibial or femoral tunnel. Over the past 25 years, a greater emphasis has been placed on precise anatomic tibial and femoral tunnel placement, as well as on achieving the proper orientation of the tunnels in both the coronal and sagittal planes. Failure to re-create native anatomy with proper tunnel position may lead to impingement or rotational instability resulting in loss of motion and/or subsequent graft failure. With the help of the anatomy department, orthopedic researchers at Rush published several studies that more precisely identified the ideal location of the tibial and femoral footprints for proper tunnel placement.^{2,3} Rue et al suggested that the ideal location of the femoral tunnel is in the “over the top” position, laterally rotated with the tip of the aimer at 1:30 or 2 o’clock for the left knee and 10 o’clock or 10:30 for the right knee. In this position, cadaveric studies revealed that a 10-mm femoral tunnel will fill approximately 50% of the posterolateral bundle and 50% of the anteromedial bundle footprints, decreasing the risk of graft failure.^{2,3} More recently, robotic technology has been employed at Rush to study the exact anatomic origin and insertions of the ACL in the femur and tibia, assess the feasibility of “anatomic” transtibial techniques, and determine if smaller tibial tunnels (eg, 7 mm) as used for hamstring ACLR can target the center of the femoral site origin.

□ Advances in Diagnosis of ACL Injury: KT1000 Arthrometer Observations

The KT1000 arthrometer (MEDmetric, San Diego, California), an instrumented device for assessing anterior-posterior translations of the knee, has been used exclusively in ACL-injured and reconstructed knees at Rush. Although this device does not quantitate rotation, it has proven invaluable in the diagnosis of ACLD and has objectified our postoperative outcomes. Using the KT1000, we have demonstrated that 98% of normal knees have less than 10 mm of anterior translation and less than a 3 mm side-to-side difference (STSD) compared to the contralateral knee.¹⁶ In contrast, the vast majority of ACL-injured patients have greater than 10 mm of translation and more than a 3-mm STSD, allowing for more accurate diagnosis of ACL injury clinically. Further, in clinical

studies following both autograft and allograft ACLR at Rush, highly significant reductions in these abnormal parameters were noted such that at follow-up, less than 4% of patients had arthrometric characteristics of failure (>5-mm STSD).¹⁷ We have also demonstrated that there is no significant time-related attenuation in translations between 6 weeks and 1 year postoperatively among bone–patellar tendon–bone (BTB) allograft and autograft.¹⁷

□ Graft Choice in the ACL-Deficient Patient at Rush

Since 1986, the central third of the patellar tendon, or BTB autograft, has been the benchmark graft choice for ACLR in young, active patients at Rush. It is readily available, allows stable fixation with bone-to-bone healing within the graft tunnel for interference screw fixation, is stronger than the normal ACL, and allows for early and more aggressive postoperative rehabilitation.^{18,19} In addition, allografts have gained tremendously in popularity over the past decade and are used in certain circumstances, such as for multiple ligament injuries, after previous failed surgery (revisions), and in older patients with or without degenerative joint disease.²⁰ Improvements in allograft safety, availability, and durable clinical results, coupled with minimum morbidity and a quicker recovery, led to the significant increase in its usage, particularly in older patients. Despite the risk of disease transmission and increased costs, allograft use in the elderly has increased significantly due to high rates of satisfaction, decreased donor site morbidity, and a quicker postoperative rehabilitation course. From 1986 to 1991, 1% of all primary ACL patients received an allograft at Rush. At subsequent 5-year intervals, the rates of allograft usage have increased from 1% to 3%, 13%, 34%, and over 50%, respectively.²⁰ Age, patient size, and activity level impact our graft recommendations. In patients under 20, the vast majority receive a BTB autograft, whereas about 50% of patients in their 20s, 65% of patients in their 30s, and nearly all patients over 40 years of age receive an ACL allograft for reconstruction. Using autografts in older patients has resulted in increased donor site morbidity and exacerbation of pain in patients with preexisting patellofemoral disease or degenerative joint disease, as well as a more difficult postoperative rehabilitation course; therefore, we prefer to use allografts in this patient population.

□ Arthroscopic-Assisted Transtibial Approach: Clinical Studies

Beginning in the early 1980s with the advent of arthroscopy, ACLR surgical techniques quickly evolved from open arthrotomies to less invasive arthroscopic-assisted intra-articular ACLR utilizing free BTB and hamstring grafts passed through appropriate bone tunnels. Many of the principles that have become standard reconstruction techniques today were developed in the 1980s

and 1990s, and surgeons at Rush were at the forefront of this evolution. Between 1986 and 1991, surgeons at Rush performed arthroscopic-assisted ACLRs using a 2-incision approach. One incision was made over the anterior tibia for drilling of the tibial tunnel from outside in, and a second incision was made over the lateral aspect of the lateral femoral condyle for drilling of the femoral tunnel from outside in. Bach and colleagues published both short-term (2-4 years)²¹ and intermediate-term (5-9 years)²² results in clinical outcome studies of patients who underwent ACLR with this technique. At a minimum 5-year follow-up, 90% of patients had clinically stable knees on examination (Lachman test, pivot shift test), 95% had objectively stable knees (KT1000 arthrometer testing), and 94% had subjective satisfaction with the operative result.²² Functional testing demonstrated less than 2% difference compared to the contralateral side, with a 2% reoperation rate. Interestingly, this group of patients had a reported 15% incidence of flexion contracture within 2-4 years with a 10% reoperation rate, and this incidence increased to 28% when they were reevaluated at 5- and 9-year follow-up with a 12% reoperation rate.²²

The high rates of knee flexion contractures and the additional surgical morbidity of a second incision in the 2-incision approach led to the development of a single-incision arthroscopic-assisted endoscopic technique allowing for intra-articular drilling of the femoral tunnel. This technique, initially performed at Rush in 1991, utilizes an obliquely oriented transtibial approach in an effort to place a lateralized femoral tunnel within the intercondylar notch.²³ Using this novel approach, Bach et al reported a greater than 90% success rate for knee stability by physical examination and 95% by objective quantification (KT1000 arthrometer testing) using patellar tendon autograft without extra-articular augmentation after 2 years.²⁴ Functional tests showed 4% to 6% differences in side-to-side comparisons for functional testing, and there was a 5% reoperation rate for minor motion problems (flexion contracture, retears). Most recently, with the emphasis on early extension of the knee and aggressive postoperative motion protocols, this reoperation rate decreased to 2%.¹ Additional clinical follow-up studies have evaluated subgroups of ACLR patients including those over the age of 35,²⁵ male versus female patients,²⁶ skeletally immature patients,²⁷ revision ACL patients,²⁸ and primary allograft ACL patients,²⁹ all with excellent clinical results. The transtibial technique has been the preferred approach to ACLR at Rush, as well as nationally and internationally, for nearly 20 years.

Researchers at Rush have authored myriad manuscripts, book chapters, and monographs focusing on surgical techniques of 2-incision, single-incision, and allograft reconstructions, as well as ACLR of the skeletally immature patient.

□ The Rush Influence on ACL Graft Tunnel Placement

Anterior femoral tunnel placement risks impingement of the graft in extension, causing loss of motion and subsequent graft failure. Vertical femoral tunnel placement provides equivalent anterior-posterior stability on simulated Lachman testing but is less able to control rotational stability than those tunnels drilled at a more oblique angle. Therefore, we hypothesized that a posterior and oblique orientation of the graft in the sagittal and coronal planes, respectively, is preferable. To achieve this goal, we created an accessory transpatellar portal to allow for a more oblique tibial tunnel, permitting the placement of the femoral tunnel farther down on the lateral wall to avoid vertical tunnel placement and creating a longer tibial tunnel to avoid graft-tunnel mismatch.³⁰ Recent robotic technology has also been used to assess the feasibility of the transtibial technique to place a graft anatomically and revealed that using a smaller tibial tunnel (eg, hamstring 7-mm tibial tunnel) may preclude anatomic placement when drilling in a transtibial fashion.

□ Early Pioneers in Outpatient ACL Surgery

Researchers at Rush were among the first to elucidate whether significant health care savings could result from a quicker postoperative recovery period enabled when using the endoscopic transtibial technique in an outpatient setting. Novak et al³¹ and Nogalski et al³² at Rush analyzed the correlation between hospital costs, procedure setting, and length of stay for ACLR. In a matched comparison of 2 patient groups assessing the relationship between health care costs and procedure setting, surgeons at Rush reported a significant charge difference between identical procedures performed in 2 different settings, the main hospital and the outpatient surgicenter, as charges for the surgicenter group averaged \$7390 (range, \$3679 to \$12202) less than the hospital group. Consistent performance of ACLR on an outpatient basis at Rush since 1993 has created considerable cost savings, allowing the medical center to optimize societal resource utilization.

□ Postoperative ACL Rehabilitation at Rush

Perhaps the greatest change in the management of ACL injuries over the past 30 years involves rehabilitation. In the early 1980s, rehabilitation protocols after ACLR involved prolonged periods of immobilization and limited weight bearing on the operative extremity. From 1986 to 1993 at Rush, continuous passive motion machines were a routine part of our rehabilitation protocol but resulted in a high incidence of postoperative arthrofibrosis. Beginning in the late 1970s and early 1980s, Noyes et al first recognized the adverse effects of postoperative immobilization on knee ligaments in humans.³³ In the late 1980s, Shelbourne and

Nitz reported on a protocol of immediate full weight bearing and unrestricted range of motion (“accelerated rehabilitation”), as well as return to sports by as early as 4 to 6 months postoperatively.³⁴ Subsequently, Beynnon et al reported the results of a prospective, randomized, double-blind trial of accelerated versus traditional postoperative rehabilitation protocols following autogenous BTB ACLR.³⁵ This study showed no differences between the 2 groups

at any time point regarding KT1000 measurements, subjective outcome scores, or single-legged hop test and demonstrated a statistically significant reduction in time required for unrestricted return to play in the accelerated group.

At Rush, we have observed that the greatest predictor of postoperative range of motion is preoperative motion, so surgery is typically delayed until full preoperative motion is achieved.

Table 2. Authors’ ACLR Rehabilitation Protocol

Time Period	Protocol
Preoperative	Goals: Communicate expectations, normalize range of motion (ROM), reduce inflammation and edema, eliminate antalgic gait.
Weeks 1-6 (period of protection)	<p>Weight bearing as tolerated without assist by postoperative day 10. Hinged knee braces</p> <ul style="list-style-type: none"> - BTB or hamstring graft: Locked in extension when sleeping/ambulating until week 6. - Allograft: May discontinue immobilizer after 10-14 days. <p>ROM: Progress through passive, active, and resisted ROM as tolerated. Extension board and prone hang with ankle weights (up to 10 lb) recommended. Stationary bike with no resistance for knee flexion (alter set height as ROM increases). Goal: Full extension by 2 weeks, 120 degrees of flexion by 6 weeks. Patellar mobilization: 5-10 minutes daily. Strengthening: Quad sets, straight leg raises (SLRs) with knee locked in extension. Begin closed chain work (0-45 degrees) when full weight bearing. No restrictions to ankle/hip strengthening.</p>
Weeks 6-12	<p>Transition to custom ACL brace if ordered by the physician. ROM: Continue with daily ROM exercises. Goal: Increase ROM as tolerated. Strengthening: Increase closed chain activities to 0-90 degrees. Add pulley weights, bands, etc. Monitor for anterior knee pain symptoms. Add core strengthening exercises. Add side lunges and/or slideboard. Add running around 8 weeks when cleared by physician. Continue stationary bike and biking outdoors for ROM, strengthening, and cardio.</p>
Weeks 12-18	<p>Advance strengthening as tolerated, continue closed chain exercises. Increase resistance on equipment. Initiate agility training (figure 8s, cutting drills, quick start/stop, etc.). Begin plyometrics and increase as tolerated. Begin to wean patient from formal supervised therapy, encouraging independence with home exercise program.</p>

Postoperatively, our patients participate in an early, aggressive rehabilitation program that graduates patients in a logical fashion over a 4- to 6-month period. While we understand that an ACLR may take 6 months to 1 year (dependent upon graft source) before complete graft incorporation and remodeling, we have also shown that rigid initial graft fixation allows for immediate, full weight bearing, range of motion as tolerated with an emphasis on complete hyperextension recovery, and early initiation of closed kinetic chain exercises instead of isokinetic exercises (Table 2). This type of accelerated rehabilitation program has proven both safe and efficacious, returning the majority of our athletes to unrestricted play by 4-6 months postoperatively. We have recently observed that the personal revision rate for our surgeons performing ACLR was 1.8% (43/2400) over an 8-year time period.

□ Conclusion

Over the past quarter century at Rush, anatomic, biomechanical, and clinical studies have paved the way for vast improvements in diagnosis, surgical treatment, and postoperative rehabilitation of patients with ACL deficiency. These changes have resulted in predictably excellent functional and clinical results that have withstood the test of time. As we transition into the next decade, ongoing research will guide surgeons at Rush as leaders in the management of ACL deficiency for years to come. ■

References

- Lewis PB, Parameswaran AD, Rue JP, Bach BR Jr. Systematic review of single-bundle anterior cruciate ligament reconstruction outcomes: a baseline assessment for consideration of double-bundle techniques. *Am J Sports Med.* 2008;36(10):2028-2036.
- Rue JP, Ghodadra N, Bach BR Jr. Femoral tunnel placement in single-bundle anterior cruciate ligament reconstruction: a cadaveric study relating transtibial lateralized femoral tunnel position to the anteromedial and posterolateral bundle femoral origins of the anterior cruciate ligament. *Am J Sports Med.* 2008;36(1):73-79.
- Rue JP, Ghodadra N, Lewis PB, Bach BR Jr. Femoral and tibial tunnel position using a transtibial drilled anterior cruciate ligament reconstruction technique. *J Knee Surg.* 2008;21(3):246-249.
- Wexler G, Hurwitz DE, Bush-Joseph CA, Andriacchi TP, Bach BR Jr. Functional gait adaptations in patients with anterior cruciate ligament deficiency over time. *Clin Orthop Relat Res.* 1998;(348):166-175.
- Patel RR, Hurwitz DE, Bush-Joseph CA, Bach BR Jr, Andriacchi TP. Comparison of clinical and dynamic knee function in patients with anterior cruciate ligament deficiency. *Am J Sports Med.* 2003;31(1):68-74.
- Hurwitz DE, Andriacchi TP, Bush-Joseph CA, Bach BR Jr. Functional adaptations in patients with ACL-deficient knees. *Exerc Sport Sci Rev.* 1997;25:1-20.
- Berchuck M, Andriacchi TP, Bach BR, Reider B. Gait adaptations by patients who have a deficient anterior cruciate ligament. *J Bone Joint Surg Am.* 1990;72(6):871-877.
- Novak PJ, Wexler GM, Williams JS Jr, Bach BR Jr, Bush-Joseph CA. Comparison of screw post fixation and free bone block interference fixation for anterior cruciate ligament soft tissue grafts: biomechanical considerations. *Arthroscopy.* 1996;12(4):470-473.
- Dworsky BD, Jewell BF, Bach BR Jr. Interference screw divergence in endoscopic anterior cruciate ligament reconstruction. *Arthroscopy.* 1996;12(1):45-49.
- Bryan JM, Bach BR Jr, Bush-Joseph CA, Fisher IM, Hsu KY. Comparison of "inside-out" and "outside-in" interference screw fixation for anterior cruciate ligament surgery in a bovine knee. *Arthroscopy.* 1996;12(1):76-81.
- Berkson E, Lee GH, Kumar A, Verma N, Bach BR Jr, Hallab N. The effect of cyclic loading on rotated bone-tendon-bone anterior cruciate ligament graft constructs. *Am J Sports Med.* 2006;34(9):1442-1449.
- Verma N, Noerdlinger MA, Hallab N, Bush-Joseph CA, Bach BR Jr. Effects of graft rotation on initial biomechanical failure characteristics of bone-patellar tendon-bone constructs. *Am J Sports Med.* 2003;31(5):708-713.
- Park DK, Fogel HA, Bhatia S, et al. Tibial fixation of anterior cruciate ligament allograft tendons: comparison of 1-, 2-, and 4-stranded constructs. *Am J Sports Med.* 2009;37(8):1531-1538.
- Lee GH, Kumar A, Berkson E, Verma N, Bach BR Jr, Hallab N. A biomechanical analysis of bone-patellar tendon-bone grafts after repeat freeze-thaw cycles in a cyclic loading model. *J Knee Surg.* 2009;22(2):111-113.
- Kang RW, Strauss EJ, Barker JU, Bach BR Jr. Effect of donor age on bone mineral density in irradiated bone-patellar tendon-bone allografts of the anterior cruciate ligament. *Am J Sports Med.* 2011;39(2):380-383.
- Bach BR Jr, Warren RF, Flynn WM, Kroll M, Wickiewicz TL. Arthrometric evaluation of knees that have a torn anterior cruciate ligament. *J Bone Joint Surg Am.* 1990;72(9):1299-1306.
- Bach BR Jr, Jones GT, Hager CA, Sweet FA, Luergans S. Arthrometric results of arthroscopically assisted anterior cruciate ligament reconstruction using autograft patellar tendon substitution. *Am J Sports Med.* 1995;23(2):179-185.
- Piasecki DP, Bach BR Jr. Anatomical single-bundle anterior cruciate ligament reconstruction with a transtibial technique. *Am J Orthop (Belle Mead NJ).* 2010;39(6):302-304.
- Nedeff DD, Bach BR Jr. Arthroscopic anterior cruciate ligament reconstruction using patellar tendon autografts: a comprehensive review of contemporary literature. *Am J Knee Surg.* 2001;14(4):243-258.
- Busam ML, Rue JP, Bach BR Jr. Fresh-frozen allograft anterior cruciate ligament reconstruction. *Clin Sports Med.* 2007;26(4):607-623.
- Bach BR Jr, Jones GT, Sweet FA, Hager CA. Arthroscopy-assisted anterior cruciate ligament reconstruction using patellar tendon substitution: two- to four-year follow-up results. *Am J Sports Med.* 1994;22(6):758-767.
- Bach BR Jr, Tradonsky S, Bojchuk J, Levy ME, Bush-Joseph CA, Khan NH. Arthroscopically assisted anterior cruciate ligament reconstruction using patellar tendon autograft: five- to nine-year follow-up evaluation. *Am J Sports Med.* 1998;26(1):20-29.
- Hardin GT, Bach BR Jr, Bush-Joseph CA, Farr J. Endoscopic single-incision anterior cruciate ligament reconstruction using patellar tendon autograft: surgical technique. 1992 [classical article]. *J Knee Surg.* 2003;16(3):135, 144; discussion 145-147.

24. Bach BR Jr, Levy ME, Bojchuk J, Tradonsky S, Bush-Joseph CA, Khan NH. Single-incision endoscopic anterior cruciate ligament reconstruction using patellar tendon autograft: minimum two-year follow-up evaluation. *Am J Sports Med.* 1998;26(1):30-40.
25. Novak PJ, Bach BR Jr, Hager CA. Clinical and functional outcome of anterior cruciate ligament reconstruction in the recreational athlete over the age of 35. *Am J Knee Surg.* 1996;9(3):111-116.
26. Ferrari JD, Bach BR Jr, Bush-Joseph CA, Wang T, Bojchuk J. Anterior cruciate ligament reconstruction in men and women: an outcome analysis comparing gender. *Arthroscopy.* 2001;17(6):588-596.
27. Pavlovich R Jr, Goldberg SH, Bach BR Jr. Adolescent ACL injury: treatment considerations. *J Knee Surg.* 2004;17(2):79-93.
28. Fox JA, Pierce M, Bojchuk J, Hayden J, Bush-Joseph CA, Bach BR Jr. Revision anterior cruciate ligament reconstruction with nonirradiated fresh-frozen patellar tendon allograft. *Arthroscopy.* 2004;20(8):787-794.
29. Bach BR Jr, Aadalen KJ, Dennis MG, et al. Primary anterior cruciate ligament reconstruction using fresh-frozen, nonirradiated patellar tendon allograft: minimum 2-year follow-up. *Am J Sports Med.* 2005;33(2):284-292.
30. Bach BR Jr, Aadalen KJ, Mazzocca AD. An accessory portal for posterior cruciate ligament tibial insertion visualization. *Arthroscopy.* 2004;20(suppl 2):155-158.
31. Novak PJ, Bach BR Jr, Bush-Joseph CA, Badrinath S. Cost containment: a charge comparison of anterior cruciate ligament reconstruction. *Arthroscopy.* 1996;12(2):160-164.
32. Nogalski MP, Bach BR Jr, Bush-Joseph CA, Luergans S. Trends in decreased hospitalization for anterior cruciate ligament surgery: double-incision versus single-incision reconstruction. *Arthroscopy.* 1995;11(2):134-138.
33. Noyes FR, Mangine RE, Barber S. Early knee motion after open and arthroscopic anterior cruciate ligament reconstruction. *Am J Sports Med.* 1987;15(2):149-160.
34. Shelbourne KD, Nitz P. Accelerated rehabilitation after anterior cruciate ligament reconstruction. *Am J Sports Med.* 1990;18(3):292-299.
35. Beynon BD, Uh BS, Johnson RJ, et al. Rehabilitation after anterior cruciate ligament reconstruction: a prospective, randomized, double-blind comparison of programs administered over 2 different time intervals. *Am J Sports Med.* 2005;33(3):347-359.

Extranodal Rosai-Dorfman Disease With Isolated Osseous Involvement: An Unusual Case

RICHARD W. KANG, MD; KEVIN C. MCGILL, MPH; JOHNNY LIN, MD;
MICHELLE E. COLLIER, MD; STEVEN GITELIS, MD

“THIS IS THE ONLY CASE IN THE LITERATURE OF [ROSAI-DORFMAN DISEASE] OF THE TALUS WITHOUT INVOLVEMENT OF LYMPH NODES AND ADJACENT STRUCTURES. IT IS ALSO THE ONLY CASE IN THE LITERATURE TREATED WITH SURGICAL EXCISION OF THE LESION.”

□ Author Affiliations

Section of Orthopedic Oncology, Department of Orthopedic Surgery, Rush University Medical Center, Chicago, Illinois.

□ Corresponding Author

Richard W. Kang, MD; Rush University Medical Center, 1611 W Harrison St, Suite 300, Chicago, IL 60612 (rw_kang@yahoo.com).

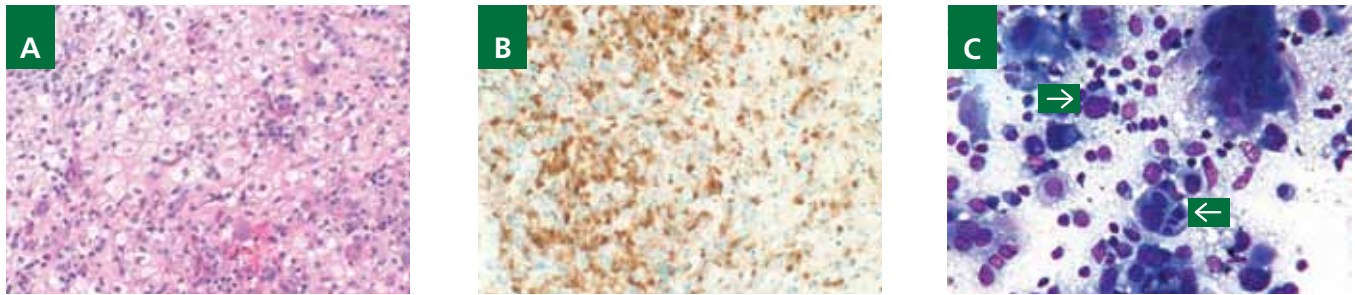
□ Introduction

In 1969 Rosai and Dorfman described sinus histiocytosis with massive lymphadenopathy (SHML), a rare non-neoplastic disorder involving histiocytes, of unknown etiology.¹ The term sinus histiocytosis refers to histiocytosis that occurs in the distended sinuses of lymph nodes. Most of the literature refers to SHML as Rosai-Dorfman disease (RDD), a convention we follow in this paper. RDD most commonly presents as bilateral, nontender, painless enlarged lymph nodes in the neck, which may be accompanied by fever, elevated sedimentation rate, weight loss, and immunological abnormalities such as leukocytosis, polyclonal hypergammaglobulinemia, and anemia. Less frequently involved nodal sites are mediastinal, hilar, retroperitoneal, axillary, and inguinal (all in the 30%-50% range).²⁻⁵ Extranodal RDD occurs in 43% of patients, with 23% experiencing isolated extranodal disease.⁶

Of the approximately 1000 patients reported in the literature,^{2,3,5} less than 3% presented with isolated osseous involvement.⁶ In the registry of 423 patients reported by Foucar et al, 8% had bone involvement, 2% had bone involvement without lymphadenopathy, and approximately 0.5% had isolated bone involvement.⁶ The skull is the most common location of a solitary bone lesion.⁷

Histiocyte cells, part of the immune system, are sometimes referred to as tissue macrophages. They have an eosinophilic cytoplasm and have a number of lysosomes. Their main functions involve phagocytosis and antigen presentation. Other diseases that have histiocytosis include Langerhans cell histiocytosis (which may also be referred to as one of the following variants: eosinophilic granuloma, Hand-Schüller-Christian disease, or Letterer-Siwe disease) and hemophagocytic lymphohistiocytosis. Clinical manifestations of Langerhans cell histiocytosis may include single or multiple bone lesion(s), exophthalmos, diabetes insipidus, visceral or skin lesions, fever, hepatosplenomegaly, anemia, bacterial infections, or lymphadenopathy. The histologic appearance of Langerhans cell histiocytosis includes an eosinophilic cytoplasm, a polymorphous mix of inflammatory cells, and Langerhans histiocytes (cells with “bean-shaped” nuclei, crisp nuclear membrane, finely stippled chromatin pattern, abundant pale/eosino-

Figure 1. A, Histologic section shows sheets of histiocytes with abundant foamy cytoplasm admixed with small lymphocytes (hematoxylin and eosin). B, S-100 protein immunostain shows numerous positively staining histiocytes. C, Cytologic touch preparations stained with Diff-Quik. Numerous histiocytes are intermixed with lymphocytes and plasma cells. Two histiocytes demonstrate emperipolesis (white arrows). An osteoclast-like giant cell is also present.



philic cytoplasm, and Birbeck granules, which are “racket-shaped” inclusion bodies seen in the cytoplasm with electron microscopy). Hemophagocytic lymphohistiocytosis clinically manifests as fever, splenomegaly, and jaundice. The histopathology of this disease will demonstrate stromal macrophages with numerous red blood cells in their cytoplasm.

Achieving a definitive diagnosis of RDD, as initially described by Goel et al,⁸ is accomplished through detection of CD68 and S-100 protein-positive histiocytes and by microscopic analysis demonstrating emperipolesis, a phenomenon characterized by phagocytosis of intact lymphocytes or plasma cells by histiocytes (Figure 1). CD68 is a stain for monocytes and macrophages, while S-100 is a stain for a variety of cells including neural crest cells, chondrocytes, adipocytes, myoepithelial cells, macrophages, Langerhans cells, dendritic cells, and keratinocytes. Compared to the presentation in lymph nodes, osseous RDD has less pronounced lymphohistiocytosis and has more fibrosis.⁹

RDD is often benign and has a high rate of spontaneous remission; therefore, management by conservative means is usually adequate. In a review by Pulsoni et al,¹⁰ 83% of the cases not involving or compressing vital organs had complete spontaneous remission. A more aggressive approach may be recommended when the location of the lesion threatens major complications, such as cord compression. Persistent cases requiring therapy have been treated with steroids, surgical excision, radiation therapy, and/or chemotherapy.^{11,12}

□ Case Report

Clinical History

A 25-year-old woman had experienced ankle pain and swelling for 2 months. She attempted ankle bracing and anti-inflammatory medication, which decreased but did not eliminate the pain. She

had not been injured and had always been healthy. She was markedly tender over the lateral border of the talus. Laboratory studies revealed a normal hematocrit, hemoglobin, and platelet count and a mildly decreased concentration of white blood cells. There was no evidence of lymphadenopathy and thus fine needle aspiration was not performed.

Her physician referred her to our orthopedic oncology clinic because x-rays of her ankle had revealed a bone lesion in her talus (Figure 2). Her MRI (Figure 3), performed with and without gadolinium contrast, showed a large lesion in the lateral aspect of the talus extending to the articular surface of the lateral talar dome. This heterogeneous mass demonstrated low signal intensity on T1-weighted images and mixed intensity on T2-weighted images with mild to moderate heterogeneous postcontrast enhancement. While there was a mild perifocal edema surrounding the lesion, we identified no areas of erosion of bone or discrete destruction of cortex by MRI.

We recommended computed tomography (CT) to assess for intralesional calcification and more subtle evidence of bony destruction. Her CT scan (Figure 4) showed an intraosseous lesion measuring 3.2 cm × 2.5 cm × 2.0 cm occupying approximately 40% of the talus. Some of the borders appeared to be slightly irregular and sclerotic.

The differential diagnosis of a solitary lesion of the talus causing chronic ankle pain and swelling may include osteomyelitis, bone cyst, lymphoma, giant cell tumor, metastatic disease, plasmacytoma, lipoidosis, and Rosai-Dorfman disease.

Although osteomyelitis was a possibility, it was unlikely given the patient’s uneventful medical history and lack of local trauma near the talus. Although there was swelling, she did not have any warmth, erythema, fevers, or chills. Her laboratory values were normal, which also was not consistent with osteomyelitis.

Figure 2. Anteroposterior (AP), mortise, and lateral preoperative ankle radiographs demonstrating a large cystic lesion in the lateral talus.

Figure 3. Coronal, sagittal, and axial T2-weighted MRI images of ankle demonstrating large mixed signal intensity lesion in the lateral talus.

Figure 4. Coronal, sagittal, and axial CT images of ankle demonstrating a large cystic lesion of the lateral talus with sclerotic margins.

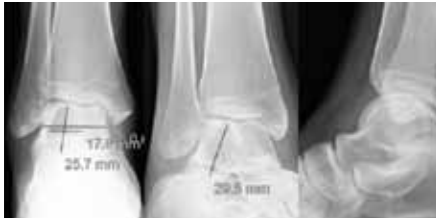

Figure 2

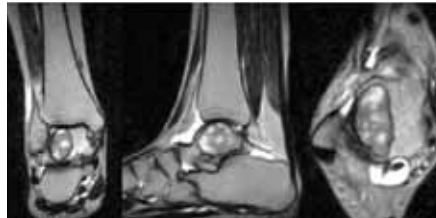

Figure 3

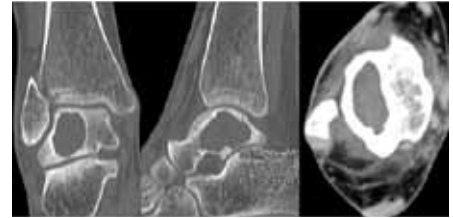


Figure 4

Aneurysmal and unicameral bone cysts were also plausible, given the lucent appearance of the lesion on radiographs. However, the lesion was not expansile. Typically, unicameral bone cysts are mildly expansile and aneurysmal bone cysts are more expansile. The MRI of aneurysmal bone cysts will also have fluid-fluid levels, which was not consistent with our findings for this patient.

Lymphoma was unlikely as it is associated with radiographs that consist of a permeative lesion and areas of cortical thickening, which were not seen in this patient.

Giant cell tumor was higher on the differential, given the age and sex of the patient, as well as the juxta-articular location of the lesion.

Metastatic disease was very unlikely given the young age of this patient. She also had no history of a primary cancer nor did she have pain outside of her ankle. Also, her imaging demonstrated a lesion that was well marginated, which is uncharacteristic of metastasis.

Plasmacytoma is more common in the 50- to 60-year-old age group. It usually presents in the vertebra, ribs, or pelvis. The patient denied any pain in these locations. She also did not have any systemic manifestations associated with plasmacytoma including anemia, renal insufficiency, hypercalcemia, or peripheral neuropathy.

Lipoidosis is a disorder of metabolism of a particular type of lipids that leads to hepatosplenomegaly, lymphadenopathy, anemia, mental retardation, and physical deterioration. Some neurologic manifestations include seizures, ophthalmoplegia, and ataxia. The patient did not have any of these manifestations.

In our case, we considered RDD as a possibility, but there was uncertainty as it is a rare diagnosis. The next step was to be an intralesional biopsy, a procedure best done by an orthopedic

oncologist so as to maximize diagnostic accuracy, minimize morbidity, and provide continuity with the care to follow.

Intralesional Biopsy

After being fully informed of the possibilities, the patient agreed to surgical biopsy. We exposed the talus through an anterolateral incision and blunt dissection. With fluoroscopic guidance, we placed a guidewire directly into the lytic lesion, followed by a cannulated drill and a Craig needle sleeve. With a pituitary rongeur we sampled tissue from the lesion. Frozen sections were equivocal; therefore, we decided to wait for permanent sections.

Histopathology

Microscopic analysis of the mass revealed a heterogeneous infiltrate of histiocytes, lymphocytes, and plasma cells with some histiocytes showing intact lymphocytes within their cytoplasm (emperipolesis) (Figure 1). The finding of emperipolesis is essentially diagnostic for RDD. The histiocytes in RDD, as opposed to reactive histiocytes that could be seen in an infectious process, are characteristically positive for S-100 protein as was seen in this case. The CD68 stain was not performed as it was deemed unnecessary at this point.

Operative Debridement

After further discussion, the patient consented to arthroscopic evaluation of her right tibiotalar joint followed by an open intralesional debridement and filling of the talus with bone graft substitute. Through a standard anteromedial portal of the ankle, diagnostic arthroscopy revealed only a moderate amount of reactive synovium in the anterior aspect of the ankle, with no evidence of a proliferative synovial disease. The anterior synovium was then sampled using a lateral arthroscopic incision, which was created through the previous biopsy incision. This specimen was taken off the field and saved for pathology.

Once we finished the arthroscopy, we extended the prior anterolateral skin incision and exposed the talus. With a high-speed burr we opened a nonarticular portion of the bone (Figure 5). The talus had a defect filled with brown pigmented tissue. We debulked the lesion and submitted the tissue to the pathologist. The margins were extended with a high-speed burr followed by electrocautery. Complete excision of the tumor was confirmed using the arthroscope to visualize the borders of the remaining cavitory defect in the talus (Figure 6). The wound was lavaged and packed with bone graft substitute (PRO-DENSE Injectable Regenerative Graft; Wright Medical Technology, Arlington, Tennessee).

Follow-up

The patient did well in the postoperative period, and by 24 weeks she had fully recovered and was back to normal activities. Radiographs at her 24-week follow-up revealed near complete consolidation of the defect with bone (Figure 7). Given her marked progress, her prognosis is excellent, and she will follow up with us on an annual basis. We felt that the operative debridement was thorough and the chances of recurrence are minimal.

Discussion

RDD is a rare self-limited disorder that can present with isolated osseous involvement, which has been reported in the skull, spine, femur, radius, ulna, metacarpals, and talus.^{1,13} Because presentations often include enlarged lymph nodes and histopathology of proliferations of lymphoid cells, but a benign and self-limited course, RDD is sometimes called a “pseudolymphomatous”

disorder. The condition is often misdiagnosed, leading to delays in treatment.

The differential diagnosis of a solitary lesion of the talus causing chronic ankle pain and swelling may include osteomyelitis, aneurysmal bone cyst, unicameral bone cyst, giant cell tumor, metastatic disease, plasmacytoma, lymphoma, and lipoidosis. The histopathology confirmed the exclusion of the possibilities in the differential diagnosis other than RDD. Osteomyelitis was ruled out by the lack of reactive histiocytes. There were no cystic areas seen on histology; thus we eliminated aneurysmal and unicameral bone cysts from the differential diagnosis. The histology of giant cell tumors demonstrates multinucleated giant cells dispersed throughout a sea of mononuclear cells, which we did not see in our patient’s biopsy. Metastatic disease would not have benign-appearing histology as was seen in our patient. There were no plasma cells observed; thus we removed plasmacytoma from the differential diagnosis. Also, the patient’s histology did not have a large proliferation of blue round cells, which is typically seen in lymphoma. Finally, lipoidosis was disregarded from the differential diagnosis because of the lack of any lipid cells.

In the published literature, there are no other cases of solitary osseous RDD involving only the talus. There are, however, 2 similar cases of extranodal RDD with primary lesions located in the talus and extending to adjacent bones. The first case, published by Abdelwahab et al⁷ in 2004, involved a 63-year-old woman who complained of progressive pain in her left ankle and, after a biopsy early in the course of the disease, was misdiagnosed with osteomy-

Figure 5. View of an opening into the nonarticular portion of the talus seen via anterolateral incision of the ankle.

Figure 6. Clean margins observed inside the talus after aggressive debridement, high-speed burring, and electrocautery.

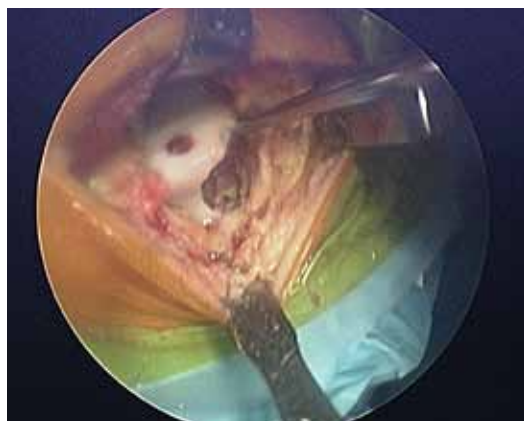


Figure 5

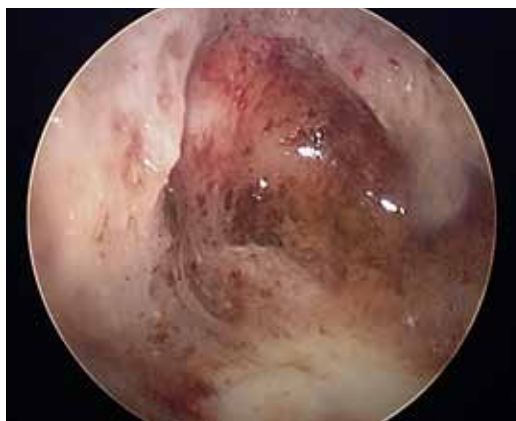
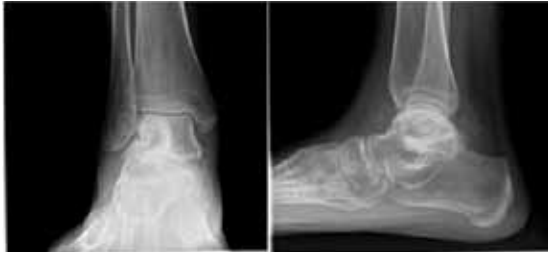
Figure 6

Figure 7. Radiographs taken at the 24-week follow-up demonstrating near complete consolidation of the defect with bone.



elitis and given antibiotics. She presented 25 years later on crutches with progressive swelling and intermittent flares of pain. MRI revealed a heterogeneous low-intensity signal on T1-weighted image of the talus with extension into the calcaneus, navicular bone, and surrounding soft tissue.

The second similar case, reported by Gupta et al,¹⁴ is of a 64-year-old woman with a 6-8 month history of left ankle pain and swelling following a relapsing and remitting course. After the initial evaluation, she was lost to follow-up for 4.5 years and then presented once again with continued pain and swelling. An MRI at baseline, 4.5 years, and 7 years showed progressive growth of multiple lesions with heterogeneous low-intensity signal on T1-weighted images eventually replacing the marrow of talus, navicular bone, calcaneus, and portions of the cuboid and lateral cuneiform with extension into adjacent soft tissue.

Our patient, just 25 years old when she began having symptoms, is much younger than most reported cases. The tissue from her lesion demonstrated emperipolesis and an S-100 protein positive immunostain, diagnostic of RDD. This is the only case in the literature of RDD of the talus without involvement of lymph nodes and adjacent structures. It is also the only case in the literature treated with surgical excision of the lesion. RDD, while rare, needs to be considered when evaluating a lytic bone lesion. ■

References

1. Rosai J, Dorfman RF. Sinus histiocytosis with massive lymphadenopathy: a newly recognized benign clinicopathological entity. *Arch Pathol.* 1969;87(1):63-70.
2. Bernácer-Borja M, Blanco-Rodríguez M, Sanchez-Granados JM, Benitez-Fuentes R, Cazorla-Jimenez A, Rivas-Manga C. Sinus histiocytosis with massive lymphadenopathy (Rosai-Dorfman disease): clinico-pathological study of three cases. *Eur J Pediatr.* 2006;165(8):536-539.
3. Chopra D, Svensson WE, Forouhi P, Poole S. A rare case of extranodal Rosai-Dorfman disease. *Br J Radiol.* 2006;79(946):e117-e119.

4. McAlister WH, Herman T, Dehner LP. Sinus histiocytosis with massive lymphadenopathy (Rosai-Dorfman disease). *Pediatr Radiol.* 1990;20(6):425-432.
5. Sodhi KS, Suri S, Nijhawan R, Kang M, Gautam V. Rosai-Dorfman disease: unusual cause of diffuse and massive retroperitoneal lymphadenopathy. *Br J Radiol.* 2005;78(933):845-847.
6. Foucar, E, Rosai J, Dorfman R. Sinus histiocytosis with massive lymphadenopathy (Rosai-Dorfman disease): review of the entity. *Semin Diagn Pathol.* 1990;7(1):19-73.
7. Abdelwahab IF, Klein MJ, Springfield DS, Hermann G. A solitary lesion of talus with mixed sclerotic and lytic changes: Rosai-Dorfman disease of 25 years' duration. *Skeletal Radiol.* 2004;33(4):230-233.
8. Goel MM, Agarwal PK, Agarwal S. Primary Rosai-Dorfman disease of bone without lymphadenopathy diagnosed by fine needle aspiration cytology: a case report. *Acta Cytol.* 2003;47(6):1119-1122.
9. Walker PD, Rosai J, Dorfman RF. The osseous manifestations of sinus histiocytosis with massive lymphadenopathy. *Am J Clin Pathol.* 1981;75(2):131-139.
10. Pulsoni A, Anghel G, Falcucci P, et al. Treatment of sinus histiocytosis with massive lymphadenopathy (Rosai Dorfman disease): report of a case and literature review. *Am J Hematol.* 2002;69(1):67-71.
11. Lasak JM, Mikaelian DO, McCue P. Sinus histiocytosis: a rare cause of progressive pediatric cervical adenopathy. *Otolaryngol Head Neck Surg.* 1999;120(5):765-769.
12. Horneff G, Jürgens H, Hort W, Karitzky D, Göbel U. Sinus histiocytosis with massive lymphadenopathy (Rosai-Dorfman disease): response to methotrexate and mercaptopurine. *Med Pediatr Oncol.* 1996;27(3):187-192.
13. Lehnert M, Eisenschenk A, Dienemann D, Linnarz M. Sinus histiocytosis with massive lymphadenopathy: skeletal involvement. *Arch Orthop Trauma Surg.* 1993;113(1):53-56.
14. Gupta S, Finzel KC, Grubber BL. Rosai-Dorfman disease masquerading as chronic ankle arthritis: a case report and review of the literature. *Rheumatology (Oxford).* 2004;43(6):811-812.

Idiopathic Glenohumeral Chondrolysis: A Case Report

SHANE J. NHO, MD, MS; NICOLE A. FRIEL, MD, MS; BRIAN J. COLE, MD, MBA

“GLENOHUMERAL CHONDROLYSIS HAS GAINED INTEREST IN THE PAST FEW YEARS AND HAS BEEN REPORTED IN MULTIPLE CASE REPORTS AND CASE SERIES AS A POTENTIAL POSTOPERATIVE COMPLICATION.”

□ Author Affiliations

Division of Sports Medicine, Department of Orthopedic Surgery, Rush University Medical Center, Chicago, Illinois.

□ Corresponding Author

Brian J. Cole, MD, MBA; Rush University Medical Center, 1611 W Harrison St, Suite 300, Chicago, IL 60612 (bcole@rushortho.com).

□ Introduction

Chondrolysis is the disappearance of articular cartilage resulting from dissolution of the cartilage matrix and cells. It is accompanied by progressive loss of joint space and increased stiffness in the involved joint.^{1,2} Chondrolysis has been documented in the hip, knee, ankle, and shoulder. The cause is often unknown. Recently, there have been a number of published reports of glenohumeral joint chondrolysis.^{1,3-13} Although the etiology has been postulated to be multifactorial, associations with arthroscopy, pain pumps,^{1,7,11} radiofrequency energy devices,^{6,8} infection,^{4,9} and suture anchors³ have been documented. In the present article, we describe the first reported case of idiopathic glenohumeral chondrolysis not associated with any known risk factor.

□ Case Report

A 32-year-old man complained of shoulder pain and stiffness beginning in his early twenties. He reported no injury or traumatic event. His primary care physician treated him with 3

steroid injections over the course of 4 years. The exact location of the injections, the drug type and dose, and the timing between injections are unknown. With worsening pain, he was evaluated by an orthopedic surgeon approximately 7 years after the onset. He complained of anterior shoulder pain and also had feelings of shoulder instability. His range of motion was 80° of forward flexion, 70° of abduction, and 45° of external rotation. He did not have a history of severe acne or other known sources of potential infection. Radiographs demonstrated a concentrically located glenohumeral joint with a well-preserved joint space and a normal acromiohumeral index. Magnetic resonance imaging revealed osteochondritic changes of the humeral head with bony erosions and synovitis of the glenohumeral joint, a partial-thickness tear of the supraspinatus tendon, and fraying of the superior glenoid labrum. Laboratory evaluation included complete blood count (white blood cell [WBC] count 9.7), C-reactive protein (0.13), rheumatoid factor (<4), and antinucleotide antibody (<80), all within normal limits.

His shoulder pain required chronic pain management with narcotic analgesia. His local orthopedic surgeon examined him under anesthesia and found no instability but significant tightness. His passive range of motion was 90° of forward flexion, 90° of abduction, 30° of external rotation, and 25° of internal rotation. Diagnostic arthroscopy revealed a global chondrolysis with a 1.0 cm × 1.5 cm × 3.5 cm area of full-thickness cartilage defect, loose

bodies, synovitis, and degenerative fraying of the superior labrum and long head of the biceps (Figure 1). He underwent global capsular release, debridement of the superior labrum and long head of the biceps, chondroplasty, extensive synovectomy, loose body removal, subacromial decompression, and distal clavicle excision. A pain pump was inserted at the conclusion of the surgery.

One month after surgery, his forward flexion had increased to 150°, abduction to 155°, internal rotation to 60°, and external rotation to 55°. His pain dramatically decreased and only affected him at night and during physical therapy. Seventeen months after the initial surgery, he had another surgery performed by the same orthopedic surgeon because of continued activity-related pain. Arthroscopic evaluation demonstrated progressive glenohumeral joint chondrolysis, synovitis, and a thickened subacromial bursitis. The operative procedure was chondroplasty of the glenohumeral joint, extensive synovectomy, and subacromial bursectomy. After the second surgery, he experienced persistent pain and diminished range of motion.

Subsequently, he consulted the senior author (B.J.C.). He described “a sensation that there is always a knife in my shoulder.” On exam, he had forward flexion to 60°, abduction to 40°, external rotation to 10°, and internal rotation to the buttock. Radiographs confirmed joint space narrowing without evidence of sclerosis or osteophytes (Figure 2). His activities of daily living were severely restricted, and he was taking 80 mg of OxyContin up to 10 times a day for pain relief. Repeat steroid injection did not improve symptoms.

The patient underwent shoulder hemiarthroplasty and biceps tenodesis. The glenoid was pristine and did not require a glenoid component. The thickened and flattened biceps tendon was released and tenodesed distally (Figure 3). Three months after the last surgery, he had an improved range of motion with 140° forward flexion, 140° abduction, and 60° external rotation and

described minimal pain, occurring only at night. He was no longer taking pain medication. At the time of preparation of this report, 20 months after his last surgery, we have been unable, in spite of multiple attempts, to locate him in order to document his current status.

□ Discussion

The present report is the only case in the published literature of idiopathic glenohumeral chondrolysis. The patient presented with insidious onset of progressive shoulder pain and diminished global range of motion refractory to nonoperative treatment. At the initial presentation, the magnetic resonance imaging study demonstrated glenohumeral joint chondrolysis and synovitis. The patient also underwent laboratory evaluation for infectious or inflammatory etiology for his shoulder pathology, but these studies were unremarkable. Although the patient had 3 steroid injections early in his nonoperative management, single injections (as opposed to continuous infusion pain pumps) of Marcaine or lidocaine have not demonstrated chondrotoxicity.¹⁴ The initial arthroscopic inspection demonstrated dramatic glenohumeral joint chondrolysis, and an indwelling pain pump was inserted following the procedure. The second arthroscopy also demonstrated severe glenohumeral joint chondrolysis.

Glenohumeral chondrolysis has gained interest in the past few years and has been reported in multiple case reports and case series as a potential postoperative complication. Although causes of postoperative chondrolysis have not been identified definitely, potential associated factors include thermal treatment,^{6,8} continuous infusion of local anesthetics,^{1,7,11} infection with *Propionibacterium acnes*,^{4,9} high arthroscopic irrigation fluid temperatures,^{5,10,15} injection of gentian violet,¹² anchor loosening and subsequent trauma,³ and iatrogenic injury.

Postoperative shoulder chondrolysis is a rare but devastating complication. Patients are usually young, presenting with an un-

Figure 1. Arthroscopic images from the patient’s initial surgery, displaying chondrolysis of the humeral head.

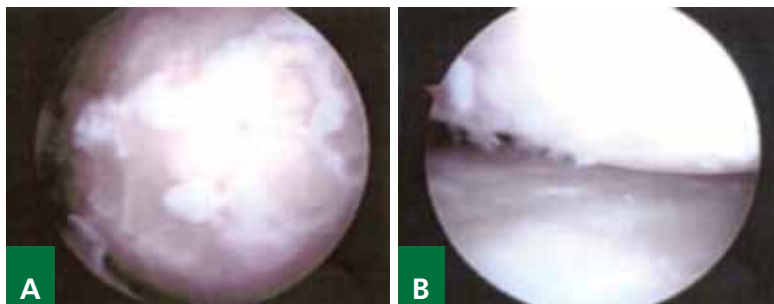


Figure 2. Preoperative anteroposterior and axillary radiographs prior to evaluation for hemiarthroplasty. The patient has joint space narrowing but does not display sclerosis or osteophytes.

Figure 3. Postoperative anteroposterior and axillary radiographs.

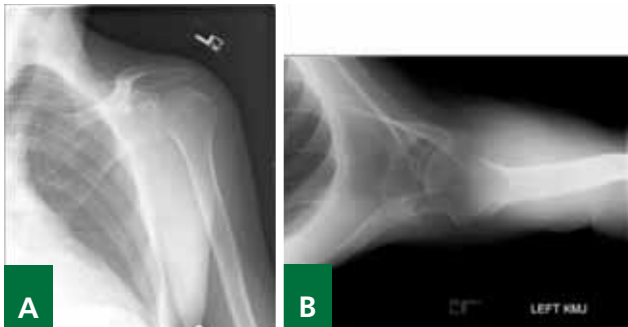


Figure 2

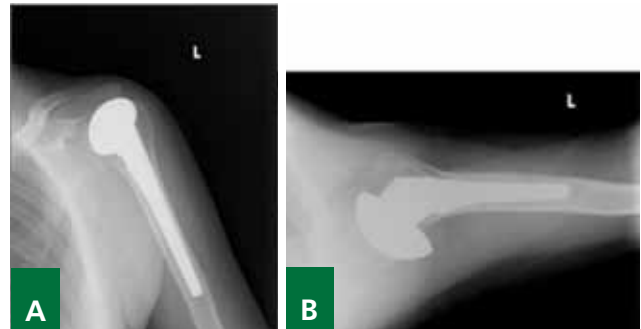


Figure 3

eventful postoperative course followed by rapid onset of shoulder pain at 6-12 months after the index surgery.^{1,7} There have been no reliable treatments once glenohumeral chondrolysis is diagnosed. Bailie and Ellenbecker report on 23 cases of shoulder chondrolysis that were treated with oral and intra-articular steroids, nonsteroidal anti-inflammatory drugs, debridement, and hyaluronic acid injections.¹ Nine patients of 23 underwent shoulder arthroplasty. In a series of 20 patients with glenohumeral chondrolysis, patients were treated with a variety of biologic procedures, including microfracture, autologous chondrocyte implantation, allografts of the humeral head, concomitant humeral head allograft and lateral meniscal interposition, and capsular release.¹¹ In both case series, patients demonstrated improvement in the short term.

Chondrolysis has been described in multiple joints, including the knee, the ankle, and most commonly the hip (Table 1). Chondrolysis of the hip is well documented, with causes including sequelae of untreated slipped capital femoral epiphysis (SCFE),^{13,22-24} penetration of the articular surface by pins during surgical treatment,²⁵ extended immobilization, exposure to methacrylate,²⁶ and septic arthritis. Idiopathic chondrolysis of the hip (ICH) is characterized by a rapid course of progressive chondrolysis that commonly occurs in adolescents.²⁷ ICH presents as pain and stiffness in the joint, with loss of articular space. Eisenstein and Rothschild suggest that chondrolysis is linked with an immune abnormality that makes the cartilage susceptible to articular cartilage damage.²⁸ Adib et al, in a case series of children presenting with painful stiff joints, discuss 14 patients with chronic hip arthritis in which juvenile idiopathic arthritis (JIA), septic hip, and reactive arthritis had been ruled out.²⁹ The authors suggest that the patients' arthritis is a result of chronic inflammatory arthritis and may even represent a separate subtype of JIA.

Regardless of the cause, chondrolysis of the hip in young patients is difficult to treat. Korula et al present a case series of patients (average age, 13 years) with idiopathic chondrolysis of the hip.²³ Patients were treated with capsulectomy, and the results report a less-than-satisfactory outcome for patients. Carney et al found chondrolysis in 16% of patients with SCFE, and most patients had poor outcomes.²²

Chondrolysis of the knee, although uncommon, has been described following meniscectomy.^{16,17} Charrois et al state that knee chondrolysis of the lateral compartment had been reported in young athletes following meniscectomy.¹⁷ Alford et al present two cases of severe chondral damage within 1 year of meniscectomy.¹⁶ The rapid presentation of chondrolysis in these cases suggests a cause other than mechanical wear. Furthermore, knee chondrolysis has been associated with radiofrequency procedures,¹⁸ exposure to chlorhexidine,¹⁹ and physical and surgical trauma.²⁰

In a case report by Bojescul et al,² the authors report a case of idiopathic ankle chondrolysis. The patient presented with chronic (5 years) lateral ankle instability, and arthroscopic findings included moderate synovitis, grade II anterolateral chondrolysis, and an anterior talar osteophyte. Following reconstruction of the ligament, the patient reported stiffness and pain at 11 months postoperatively and had radiographic evidence of chondrolysis. Of note, this patient had a pain pump after the first scope.

□ Conclusions

We present the case of a young patient with long-standing shoulder pain and stiffness. Our patient had none of the factors reported as possible etiologies in cases of chondrolysis of the glenohumeral and other joints. He had had 3 intra-articular steroid injections prior to the diagnosis of chondrolysis, leading us to consider whether some

Table 1. Summary of Described Chondrolysis Etiologies

Affected Joint	Etiology
Knee	Following meniscectomy ^{16,17} Radiofrequency procedures ¹⁸ Exposure to chlorhexidine ¹⁹ Physical and surgical trauma ²⁰ Idiopathic ²¹
Shoulder (glenohumeral)	Thermal treatment ^{6,8} Intra-articular pain pumps ^{1,7,11} Infection ^{4,9} High-temperature irrigation fluid ^{5,10,15} Gentian violet ¹² Anchor loosening and subsequent trauma ³
Hip	Untreated slipped capital femoral epiphysis (SCFE) ^{13,22-24} Incorrect pin placement ²⁵ Extended immobilization Exposure to methacrylate ²⁶ Septic arthritis Idiopathic ^{23,27} Immune abnormality ²⁸

idiosyncratic reaction to the injected material or unrecognized infection from the injections could have occurred and caused the chondrolysis. However, he had symptoms prior to the injections, the materials injected were short-acting, shoulder joint injections are exceedingly common and not known to be associated with chondrolysis, laboratory testing showed no evidence of infection, and the pristine condition of the glenoid cartilage found at the last surgery suggested a pathologic process originating in the humeral head as opposed to the joint space. For all these reasons, we concluded that, though the possibility of a relationship between the injections and the chondrolysis could not be eliminated, it is probable that there was no causal relationship, and therefore the etiology, in this case, is best considered idiopathic. ■

References

- Bailie DS, Ellenbecker T. Severe chondrolysis after shoulder arthroscopy: a case series. *J Shoulder Elbow Surg.* 2009;18(5):742-747.
- Bojescul JA, Wilson G, Taylor DC. Idiopathic chondrolysis of the ankle. *Arthroscopy.* 2005;21(2):224-227.

- Athwal GS, Shridharani SM, O'Driscoll SW. Osteolysis and arthropathy of the shoulder after use of bioabsorbable knotless suture anchors: a report of four cases. *J Bone Joint Surg Am.* 2006;88(8):1840-1845.
- Delyle LG, Vittecoq O, Bourdel A, Duparc F, Michot C, Le Loët X. Chronic destructive oligoarthritis associated with *Propionibacterium acnes* in a female patient with acne vulgaris: septic-reactive arthritis? *Arthritis Rheum.* 2000;43(12):2843-2847.
- Good CR, Shindle MK, Griffith MH, Wanich T, Warren RF. Effect of radiofrequency energy on glenohumeral fluid temperature during shoulder arthroscopy. *J Bone Joint Surg Am.* 2009;91(2):429-434.
- Good CR, Shindle MK, Kelly BT, Wanich T, Warren RF. Glenohumeral chondrolysis after shoulder arthroscopy with thermal capsulorrhaphy. *Arthroscopy.* 2007;23(7):797.e1-797.e5.
- Hansen BP, Beck CL, Beck EP, Townsley RW. Postarthroscopic glenohumeral chondrolysis. *Am J Sports Med.* 2007;35(10):1628-1634.
- Levine WN, Clark AM Jr, D'Alessandro DE, Yamaguchi K. Chondrolysis following arthroscopic thermal capsulorrhaphy to treat shoulder instability: a report of two cases. *J Bone Joint Surg Am.* 2005;87(3):616-621.
- Levy PY, Fenollar F, Stein A, et al. *Propionibacterium acnes* postoperative shoulder arthritis: an emerging clinical entity. *Clin Infect Dis.* 2008;46(12):1884-1886.
- Lu Y, Edwards RB III, Nho S, Cole BJ, Markel MD. Lavage solution temperature influences depth of chondrocyte death and surface contouring during thermal chondroplasty with temperature-controlled monopolar radiofrequency energy. *Am J Sports Med.* 2002;30(5):667-673.

11. McNickle AG, L'Heureux DR, Provencher MT, Romeo AA, Cole BJ. Postsurgical glenohumeral arthritis in young adults. *Am J Sports Med.* 2009;37(9):1784-1791.
12. Tamai K, Higashi A, Cho S, Yamaguchi T. Chondrolysis of the shoulder following a "color test"-assisted rotator cuff repair: a report of 2 cases. *Acta Orthop Scand.* 1997;68(4):401-402.
13. Warner WC Jr, Beaty JH, Canale ST. Chondrolysis after slipped capital femoral epiphysis. *J Pediatr Orthop B.* 1996;5(3):168-172.
14. Chu CR, Izzo NJ, Coyle CH, Papas NE, Logar A. The in vitro effects of bupivacaine on articular chondrocytes. *J Bone Joint Surg Br.* 2008;90(6):814-820.
15. Yang CY, Cheng SC, Shen CL. Effect of irrigation fluids on the articular cartilage: a scanning electron microscope study. *Arthroscopy.* 1993;9(4):425-430.
16. Alford JW, Lewis P, Kang RW, Cole BJ. Rapid progression of chondral disease in the lateral compartment of the knee following meniscectomy. *Arthroscopy.* 2005;21(12):1505-1509.
17. Charrois O, Ayrat X, Beaufils P. Rapid chondrolysis after arthroscopic external meniscectomy: apropos of 4 cases [in French]. *Rev Chir Orthop Reparatrice Appar Mot.* 1998;84(1):88-92.
18. Vangsness CT Jr. Radiofrequency use on articular cartilage lesions. *Orthop Clin North Am.* 2005;36(4):427-431.
19. van Huyssteen AL, Bracey DJ. Chlorhexidine and chondrolysis in the knee. *J Bone Joint Surg Br.* 1999;81(6):995-996.
20. Jay GD, Elsaid KA, Chichester CO. Early damage to the articular cartilage matrix occurs following traumatic knee injuries without fracture. *Acad Emerg Med.* 2003;10(5):496.
21. Slabaugh MA, Friel NA, Cole BJ. Rapid chondrolysis of the knee after anterior cruciate ligament reconstruction: a case report. *J Bone Joint Surg Am.* 2010;92(1):186-189.
22. Carney BT, Weinstein SL, Noble J. Long-term follow-up of slipped capital femoral epiphysis. *J Bone Joint Surg Am.* 1991;73(5):667-674.
23. Korula RJ, Jebaraj I, David KS. Idiopathic chondrolysis of the hip: medium- to long-term results. *ANZ J Surg.* 2005;75(9):750-753.
24. Lubicky JP. Chondrolysis and avascular necrosis: complications of slipped capital femoral epiphysis. *J Pediatr Orthop B.* 1996;5(3):162-167.
25. Stambough JL, Davidson RS, Ellis RD, Gregg JR. Slipped capital femoral epiphysis: an analysis of 80 patients as to pin placement and number. *J Pediatr Orthop.* 1986;6(3):265-273.
26. Leclair A, Gangi A, Lacaze F, et al. Rapid chondrolysis after an intra-articular leak of bone cement in treatment of a benign acetabular subchondral cyst: an unusual complication of percutaneous injection of acrylic cement. *Skeletal Radiol.* 2000;29(5):275-278.
27. Rachinsky I, Boguslavsky L, Cohen E, Hertzanu Y, Lantsberg S. Bilateral idiopathic chondrolysis of the hip: a case report. *Clin Nucl Med.* 2000;25(12):1007-1009.
28. Eisenstein A, Rothschild S. Biochemical abnormalities in patients with slipped capital femoral epiphysis and chondrolysis. *J Bone Joint Surg Am.* 1976;58(4):459-467.
29. Adib N, Owers KL, Witt JD, Owens CM, Woo P, Murray KJ. Isolated inflammatory coxitis associated with protrusio acetabuli: a new form of juvenile idiopathic arthritis? *Rheumatology (Oxford).* 2005;44(2):219-226.

Reduced Scapular Notching Following Reverse Total Shoulder Arthroplasty: Clinical Results of a New Implant Design

SETH L. SHERMAN, MD; BRETT A. LENART, MD; ERIC STRAUSS, MD; AMAN DHAWAN, MD;
ERIC GOCHANOUR, MA; GREGORY P. NICHOLSON, MD

“WE STRONGLY BELIEVE THAT THE COMBINATION OF IMPLANT DESIGN MODIFICATIONS, CAREFUL PATIENT SELECTION AND PREOPERATIVE WORKUP, AND METICULOUS SURGICAL TECHNIQUE HAVE LED TO THE LOW INCIDENCE OF NOTCHING IN THIS SERIES.”

□ Author Affiliations

Division of Sports Medicine, Department of Orthopedic Surgery, Rush University Medical Center, Chicago, Illinois.

□ Corresponding Author

Seth L. Sherman, MD; Rush University Medical Center, 1611 W Harrison St, Suite 300, Chicago, IL 60612 (dr.seth.sherman@gmail.com).

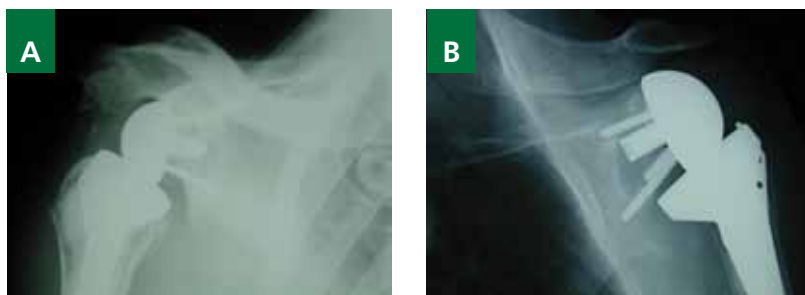
□ Introduction

Total shoulder arthroplasty (TSA) has revolutionized the treatment of symptomatic glenohumeral arthritis, significantly decreasing pain and improving shoulder function in patients with severe disease. However, in patients with a deficient rotator cuff, conventional TSA has provided suboptimal results leading to a decrease in subjective patient satisfaction, an increased complication rate, and poor radiographic outcomes.¹ The reverse ball-and-socket prosthesis was developed in an attempt to compensate for the nonfunctioning rotator cuff in patients requiring TSA.² Implant design, meticulous surgical technique, and careful patient selection have led to successful outcomes for the majority of patients undergoing reverse TSA.²⁻⁴ However, the increase in demand for and popularity of this technique has led to the recognition of novel complications such as scapular notching, inherent to the unique design of reverse TSA.

Scapular notching is seen radiographically inferior to the glenosphere and is a potential complication of reverse TSA. This entity most likely represents repetitive mechanical abutment of the humeral component with the inferior portion of the neck of the scapula, resulting in glenoid neck osseous erosion over time, and with its potential polyethylene wear that could compromise results. Scapular notching typically occurs within the first few months after reverse TSA, with a reported incidence ranging from 44% to 96%.^{3,5} Many factors contribute to the development of scapular notching, including preoperative diagnosis, prosthetic design, surgical approach, positioning of the glenoid component, and the pattern of glenoid wear in the degenerative process.⁶⁻¹⁰ Initial short-term studies did not demonstrate a negative impact of scapular notching on postoperative pain and Constant scores.⁷ However, results from longer-term studies suggest that scapular notching may be a progressive finding, and it has been associated with a loss of range of motion, loss of strength, decreased shoulder outcome scores, and increased polyethylene wear with the potential for implant loosening.^{4,9}

The indications for reverse TSA continue to expand and now include rotator cuff arthropathy, rheumatoid arthritis, proximal humerus fractures, fracture malunions/nonunions, and revision procedures. The high reported rates of scapular notching are

Figure 1. A, Grade 3 scapular notch according to the Nerot/Sirveaux classification. Note the extension of the bone loss over the lower fixation screw on this AP radiograph. B, Grade 4 scapular notch according to the Nerot/Sirveaux classification. Note the progression of the defect to the undersurface of the baseplate.



alarming, especially in light of evidence suggesting its negative impact on patient outcomes. This study presents a large consecutive series of Trabecular Metal Reverse (Zimmer, Inc, Warsaw, Indiana) total shoulder arthroplasties performed by two experienced shoulder surgeons. Our hypothesis is that scapular notching can be minimized through proper patient selection, meticulous surgical technique, and implant design modifications.

□ Materials and Methods

A consecutive series of 144 Trabecular Metal Reverse total shoulder arthroplasties performed by 2 experienced shoulder arthroplasty surgeons (G.P.N. and Anand M. Murthy, MD) provided the study population. The reverse shoulder was approved for use in the United States in 2004. The Trabecular Metal Reverse was introduced in early 2006. Both surgeons had 2 years of experience utilizing Grammont-style implants prior to using the Trabecular Metal Reverse. All shoulders were radiographically evaluated with true anteroposterior (AP) and axillary views during their postoperative follow-up visits. Each surgeon was blinded to patient-specific information and evaluated the AP and axillary radiographs from his own cases. The first evaluation had a minimum follow-up of 6 months and an average of 14 months (range, 6-24 months). A second evaluation of the same 144 shoulders was performed by the same 2 surgeons in an identical fashion an average of 8 months later. Thus the minimum follow-up became 14 months and the average follow-up was 22 months (range, 14-32 months).

Scapular notching, when present on the postoperative radiographs, was graded using the Nerot/Sirveaux classification.^{10,11} A grade 1 notch describes a defect contained within the inferior pillar of the scapular neck. A grade 2 notch involves erosion of the scapular neck to the level of the inferior fixation screw of the glenosphere baseplate. A grade 3 scapular notch indicates extension of the bone loss over the lower fixation screw. A grade 4

defect describes progression to the undersurface of the baseplate (Figure 1). Although the primary endpoint of this study was a radiographic evaluation, instability events and complication rates were also documented.

This study was approved by the institutional review board.

□ Results

The mean age of patients in this series was 68 years (range, 39-87 years). We have radiographic follow-up on all 144 patients. Chart review was also performed on all patients. Female patients accounted for 58% of the cases. All procedures were performed through a deltopectoral approach. In this series, the preoperative diagnoses were rotator cuff arthropathy (50%), failed rotator cuff repairs (20%), fracture sequelae (16%), and failed prior implants (14%). Forty-eight patients (33%) had previous surgery on the operative shoulder. In 126 patients (87.5%), a 36-mm glenosphere was used, and in 18 (12.5%) a 40-mm glenosphere was used.

Analysis after the first evaluation revealed a 0% scapular notch rate. There were no glenoid lucencies or loosening. There were 5 (3.5%) instability events that occurred early (less than 2 months postoperatively). Two required closed reduction, and 3 required a revision with polyethylene liner exchange. None of these patients went on to have any evidence of scapular notching or periosteal reaction on final follow-up.

At the second evaluation, there were no additional patients with instability events. A scapular notch was noted in 12 of 144 (8.3%), all diagnosed on the AP radiograph. Nine of the 12 (75%) were grade 1, 2 (17%) were grade 2, and 1 (8%) was grade 3. There were no grade 4 notches (Table 1).

Of the cases that were found to have a postoperative scapular notch, 8 were for a diagnosis of primary cuff tear arthropathy, 2 were revision cases, and 2 were for treatment of surgical neck

Table 1. Distribution of Scapular Notching by Nerot/Sirveaux Classification at an Average of 22 Months Follow-up

Figure 2. Design features of the Zimmer Trabecular Metal Reverse prosthesis. The prosthesis is a low-profile humeral component with a 3-mm trabecular metal glenoid baseplate. The humeral component incorporates a 150-degree neck-shaft angle, 143 degrees from the humeral component and 7 degrees from the polyethylene component.

Grade	Number (%)
1	9 (75)
2	2 (17)
3	1 (8)
4	0 (0)
Total	12 (100)

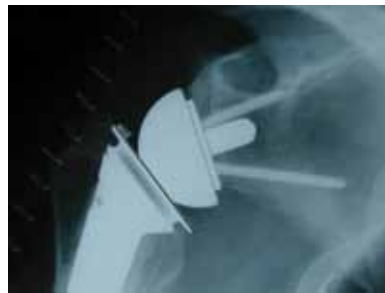

Table 1

Figure 2

nonunions. Only one of the glenospheres was felt to be placed in neutral position without an inferior tilt when evaluated by the operating surgeon analyzing the AP radiograph.

No case with a notch or periosteal reaction had documentation of clinical symptoms, instability, or radiographic evidence of glenoid baseplate loosening. There was no screw breakage or implant dissociation.

□ Discussion

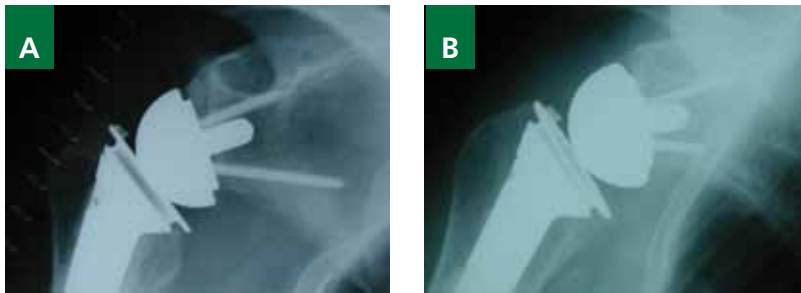
Scapular notching is defined as erosion of bone of the scapular neck secondary to mechanical abutment of the humeral implant with adduction of the upper extremity.^{3,7,8} Repetitive mechanical contact between the polyethylene cup of the humeral component and the inferior scapular neck with subsequent wear of the polyethylene may invoke a biologic response, leading to chronic inflammation of the joint capsule, local osteolysis, and the potential for implant loosening.^{8,12} Additionally, scapular notching may lead to loss of joint constraint, creating the potential for joint instability.²

The implant used exclusively in this series is a Trabecular Metal Reverse prosthesis (Figure 2). While maintaining an inferior and medial position of the glenoid center of rotation, the prosthesis has several unique design features that may aid in the prevention of scapular notching. The metallic neck-shaft angle is 143 degrees, and the polyethylene component has a 7-degree angle, thus creating a total neck-shaft angle of 150 degrees. This 5-degree

difference from other reverse arthroplasty designs allows for better adduction of the arm without mechanical abutment. Additionally, this implant design has a low profile with no metallic material above the humeral osteotomy. The glenoid baseplate has a 3-mm trabecular metal pad on the back side. This creates a small lateral offset when implanted onto the glenoid surface. We believe that these unique design parameters are, at least, partially responsible for the decreased incidence of notching appreciated in the current series (Figure 3).

The incidence of scapular notching in the present study is 8.3%, which is significantly decreased from the incidence found in previous reports. We believe that several factors including surgical approach, implant position, and implant design are responsible for the reduced incidence of notching in the current series. These factors will be discussed in detail below. In the literature, the incidence of scapular notching ranges from 44% to 96%.^{2,4,7,9,10,12,13} Simovitch et al noted postoperative scapular notching in 44% of cases.⁹ In that series, notching was radiographically evident at a mean of 4.5 months postoperatively, with no cases demonstrating new onset scapular erosion after 14 months of follow-up. Clinical series published by Lévine et al,⁷ Sirveaux et al,¹⁰ and Boileau et al³ reported scapular notching with a slightly higher incidence of 62%, 63.6%, and 74% respectively. Another series, by Werner et al,⁴ demonstrated near universal presence of notching, finding evidence of inferior scapular neck erosion in 96%, with 54% of the

Figure 3. A, Initial postoperative AP radiograph demonstrating implantation of the Zimmer Trabecular Metal Reverse prosthesis with the appropriate amount of inferiorization, medialization, and inferior tilt. B, A 2-year follow-up AP radiograph of the same patient shows no evidence of scapular notching. We believe that the unique design features of the Zimmer Trabecular Metal Reverse prosthesis and strict adherence to Grammont principles have led to this successful radiographic outcome.



notches classified as either grade 1 or grade 2 and 46% as grade 3 or grade 4.

There remains no consensus in the literature regarding the time of onset of scapular notching, or the presence of radiographic progression. Scapular notching tends to first appear early in the postoperative period, with most reports describing radiographic evidence of scapular neck erosion between 6 weeks and 14 months postoperatively.³ Simovitch et al reported no new cases of scapular notching recognized past the 14-month time point.⁹ For this reason, we believe that the time course used in the present study was sensitive enough to capture the majority of patients who would develop scapular notching in our series. Studies by Werner et al⁴ and Simovitch et al⁹ demonstrate that the extent of the scapular notching plateaus over time with stabilization at 2-3 years, while Lévine et al⁷ reported progression at 2 and 3 years follow-up with evidence of worsening of grade. The topic of progression remains controversial. Our series does not currently add insight to this debate. Longer-term follow-up of several years is necessary before drawing any meaningful conclusions.

The impact of scapular notching on postoperative shoulder function, instability, and implant survivorship is also controversial. In the present study, we did not find any impact of scapular notching on these parameters at a mean of 22 months postoperative. The instability rate of the current study was 3.5%. These instability events occurred early within the postoperative period (less than 2 months) and were not associated with the presence of or subsequent development of scapular notching. In all the cases in our series, including the 12 with scapular notches, there was no evidence of implant dissociation, glenoid loosening, screw breakage, or catastrophic polyethylene wear. The data from the literature is mixed with regard to the clinical impact of scapular

notching. Delloye et al¹⁴ and Vanhove and Beugnies¹² identified glenosphere loosening in a small series of patients with scapular notching. Lévine et al⁷ reported a correlation between the presence and size of a notch with the development of radiolucencies around both the humeral and glenoid components as follow-up time increased. The clinical relevance of these findings remains unclear. Some authors reported the absence of any correlation between the presence or grade of scapular notching and any objective or subjective clinical measure or postoperative complication.^{2,7,4} In contrast, other studies have shown a relationship between the presence and extent of scapular notching and lower Constant-Murley and subjective shoulder scores. Sirveaux et al¹⁰ found that patients with grade 3 and grade 4 notching had lower postoperative Constant-Murley scores. Similarly, Simovitch et al⁹ found lower mean Constant-Murley scores, lower subjective shoulder scores, inferior shoulder strength, and worse postoperative range of motion in patients with scapular notches compared with those with normal radiographs. Longer follow-up studies will help to shed light on this controversial topic.

Technique-dependent factors may also play a role in the decreased incidence of scapular notching in our series. A deltopectoral surgical approach was used in all cases in this series. A higher incidence of scapular notching has been shown with the anterosuperior approach as compared with a deltopectoral approach (86% versus 56%).⁷ Intraoperatively, during exposure and preparation of the glenoid, the glenosphere baseplate is implanted as inferior on the native glenoid as possible to foster inferior overhang of the glenosphere component. Reaming was performed to promote a slight inferior tilt to the implanted glenosphere baseplate (10 to 20 degrees). Neutral or superiorly tilted baseplates increase the risk of scapular notching compared with inferior glenoid tilt.

Several studies demonstrate that allowing inferior overhang of the glenosphere improved impingement-free adduction and abduction angles.^{6,8,9,10} It has also been shown that baseplates implanted with a slight (15-degree) inferior tilt had the most compressive forces under the baseplate during loading with the least amount of tensile forces and the smallest amount of micromotion.^{6,8,9,10} The senior author (G.P.N.) uses hand reamers on the glenoid, reaming until a “subchondral smile” of cancellous bone can be seen on the inferior aspect of the glenoid. Superior defects that remain subsequent to hand reaming can be bone grafted, ensuring the glenosphere baseplate is not placed with a superior tilt. The glenosphere can be sized appropriately to allow for 2 to 3 mm of inferior overhang, which will promote postoperative range of motion, stability, and minimization of notch development with humeral adduction.

The primary objective of this radiographic study was to determine the incidence of scapular notching with this unique implant design. Future follow-up of this cohort will be necessary to comment on radiographic progression and its long-term impact on clinical stability and implant longevity. This was not a clinical outcome study, but we were able to review and report on 100% of our patients’ records documenting clinical parameters including instability events; implant lucency, loosening, or failure; and presence or absence of major complications.

In conclusion, this study demonstrates a significant decrease in the incidence of scapular notching with the use of a unique implant design and consistent surgical technique. This implant still respects the proven Grammont design principles. We strongly believe that the combination of implant design modifications, careful patient selection and preoperative workup, and meticulous surgical technique have led to the low incidence of notching in this series and the shift toward lower-grade (1 or 2) notches when present. While the true clinical impact of scapular notching is yet to be revealed, minimization of scapular notching may prove essential in reducing morbidity and preventing complications in patients undergoing reverse TSA. ■

References

1. Edwards TB, Boulahia A, Kempf JF, Boileau P, Nemoz C, Walch G. The influence of rotator cuff disease on the results of shoulder arthroplasty for primary osteoarthritis: results of a multicenter study. *J Bone Joint Surg Am.* 2002;84-A(12):2240-2248.
2. Boileau P, Watkinson DJ, Hatzidakis AM, Balg F. Grammont reverse prosthesis: design, rationale, and biomechanics. *J Shoulder Elbow Surg.* 2005;14(1)(suppl S):147S-161S.
3. Gerber C, Pennington SD, Nyffeler RW. Reverse total shoulder arthroplasty. *J Am Acad Orthop Surg.* 2009;17(5):284-295.
4. Werner CM, Steinmann PA, Gilbert M, Gerber C. Treatment of painful pseudoparesis due to irreparable rotator cuff dysfunction with the Delta

III reverse-ball-and-socket total shoulder prosthesis. *J Bone Joint Surg Am.* 2005;87(7):1476-1486.

5. Roche C, Flurin PH, Wright T, Crosby LA, Mauldin M, Zuckerman JD. An evaluation of the relationships between reverse shoulder design parameters and range of motion, impingement, and stability. *J Shoulder Elbow Surg.* 2009;18(5):734-741.
6. Gutiérrez S, Levy JC, Frankle MA, et al. Evaluation of abduction range of motion and avoidance of inferior scapular impingement in a reverse shoulder model. *J Shoulder Elbow Surg.* 2008;17(4):608-615.
7. Lévine C, Boileau P, Favard L, et al. Scapular notching in reverse shoulder arthroplasty. In: Walch G, Boileau P, Molé D, Favard L, Lévine C, Sirveaux F, eds. *Reverse Shoulder Arthroplasty: Clinical Results, Complications, Revision.* Paris, France: Sauramps Médical; 2006:353-372.
8. Nyffeler RW, Werner CM, Simmen BR, Gerber C. Analysis of a retrieved Delta III total shoulder prosthesis. *J Bone Joint Surg Br.* 2004;86(8):1187-1191.
9. Simovitch RW, Zumstein MA, Lohri E, Helmy N, Gerber C. Predictors of scapular notching in patients managed with the Delta III reverse total shoulder replacement. *J Bone Joint Surg Am.* 2007;89(3):588-600.
10. Sirveaux F, Favard L, Oudet D, Huquet D, Walch G, Molé D. Grammont inverted total shoulder arthroplasty in the treatment of glenohumeral osteoarthritis with massive rupture of the cuff: results of a multicentre study of 80 shoulders. *J Bone Joint Surg Br.* 2004;86(3):388-395.
11. Sirveaux F. *La prothèse de Grammont dans le traitement des arthropathies de l'épaule à coiffe détruite: à propos d'une série multi-centrique de 42 cas* [thesis]. Nancy, France: Faculté de Médecine de Nancy; 1997:245.
12. Vanhove B, Beugnies A. Grammont's reverse shoulder prosthesis for rotator cuff arthropathy: a retrospective study of 32 cases. *Acta Orthop Belg.* 2004;70(3):219-225.
13. Boulahia A, Edwards TB, Walch G, Baratta RV. Early results of a reverse design prosthesis in the treatment of arthritis of the shoulder in elderly patients with a large rotator cuff tear. *Orthopedics.* 2002;25(2):129-133.
14. Delloye C, Joris D, Colette A, Eudier A, Dubuc JE. Mechanical complications of total shoulder inverted prosthesis [in French]. *Rev Chir Orthop Reparatrice Appar Mot.* 2002;88(4):410-414.

Anterior Hip Pain in an Athletic Population: Differential Diagnosis and Treatment Options

MARK A. SLABAUGH, MD; RACHEL M. FRANK, MD; ROBERT C. GRUMET, MD; PHIL MALLOY, MPT; CHARLES A. BUSH-JOSEPH, MD; WALTER W. VIRKUS, MD; SHANE J. NHO, MD, MS

“TECHNOLOGIC ADVANCES . . . HAVE ALLOWED CONDITIONS THAT WERE PREVIOUSLY TREATED CONSERVATIVELY NOW TO BE TREATED MORE AGGRESSIVELY, ALLOWING FOR EARLIER RETURN TO SPORTS AND RESULTING IN HIGH PATIENT SATISFACTION.”

□ Author Affiliations

Division of Sports Medicine, Department of Orthopedic Surgery (Drs Slabaugh, Frank, Grumet, Bush-Joseph, Virkus, and Nho), and Healthy Hip Program (Drs Bush-Joseph, Virkus, and Nho), Rush University Medical Center, Chicago, Illinois; and Athletico Physical Therapy, Chicago, Illinois (Mr Malloy).

□ Corresponding Author

Shane J. Nho, MD, MS; Rush University Medical Center, 1611 W Harrison St, Suite 300, Chicago, IL 60612 (snho@hotmail.com).

□ Introduction

Athletic injuries around the hip have been poorly understood and often were lumped into the diagnosis of “hip pointer.” Patients with hip injuries were frequently treated conservatively for long periods of time until many either gave up their sport of choice or limited their activities.

Since the advent of hip arthroscopy, there has been an increasing interest in the diagnosis and treatment of patients with athletic hip injuries. Just in the past 10 years there has been increasing research interest and publication regarding conditions that affect the hip and their treatment. Advances in imaging modalities have allowed physicians and surgeons to better grasp soft-tissue injuries around the hip and their natural history. Additionally, technologic

advances in hip arthroscopy equipment and repair devices have allowed conditions that were previously treated conservatively now to be treated more aggressively, allowing for earlier return to sports and resulting in high patient satisfaction.

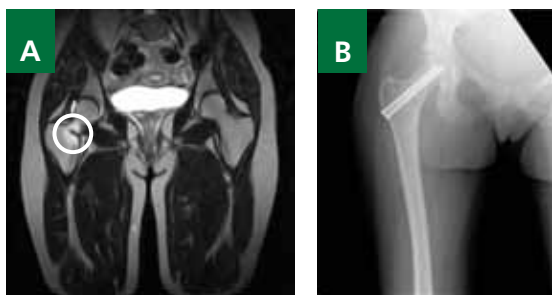
With all these recent advances, physicians are gaining a better understanding of the complex anatomy and pathology of the hip and surrounding areas. Often hip conditions can be categorized into an anatomical location depending upon where the hip pain predominantly occurs. This review will focus on the causes of anterior hip pain in an athletic population.

□ Anatomy

Knowledge of the functional anatomy of the hip and its surrounding structures is necessary in order to arrive at a conclusive diagnosis regarding hip conditions. The anatomy of the anterior portion of the hip is complex, with several muscle groups crossing the hip and many more arising from the hip area and the lower abdominal wall.

A discussion of hip anatomy has to include key structures in the pelvis since these structures, when injured, often radiate pain into the anterior hip. The anterior pelvis consists of several structures that play a role in conditions that affect the hip. Osseous morphology includes the anterior superior iliac spine (ASIS), which serves

Figure 1. Femoral neck stress fracture of right femur. **A**, MRI, frontal view. **B**, Postoperative radiograph showing percutaneous screw fixation.



as the origin of the sartorius muscle and the ilioinguinal ligament. The anterior inferior iliac spine (AIIS) serves as the attachment of the rectus femoris, one of the key hip flexors and knee extenders. The muscles collectively known as the adductors of the hip all originate in the anterior pelvic region. The pectineus and the adductor longus originate on the superior pubic ramus, while the adductor magnus, the adductor brevis, and the gracilis originate on the inferior pubic ramus. All these muscles collectively adduct the thigh. The rectus abdominis inserts on the pubic bone just lateral to the symphysis. Finally, the iliopsoas, the major hip flexor, crosses under the ilioinguinal ligament to insert on the lesser tuberosity after crossing over the anterior capsule of the hip. This tendon has a large bursa surrounding it that helps it glide smoothly over the hip with range of motion.

The inguinal area is unfamiliar territory for many orthopedic surgeons since general surgeons treat the majority of conditions arising in this area. It is helpful to think of the inguinal canal as a box composed of six sides. The posterior opening is the deep inguinal ring. The posterior wall of the box is composed of this ring, the transversalis fascia, and the conjoint tendon with Cooper's ligament. The superior wall (roof) consists of the internal oblique and transversus abdominis muscles. The anterior wall is composed of the aponeurosis of the internal and external obliques as well as the superficial inguinal ring. The inferior wall (floor) is made up of the inguinal ligament, the lacunar ligament, and the iliopubic tract. The inguinal canal contains the spermatic cord in males and the round ligament in females along with the ilioinguinal nerve (responsible for radiation of pain to the anterior hip). The clinical significance of these structures will be discussed further under the respective disorders.

The hip itself is a spheroidal joint composed of the femoral head and the acetabulum, which is deepened by the labrum.

Intra-articular pathology is often manifested by anterior hip or groin pain due to the innervation of the hip capsule. The majority of the articular hip is innervated by the femoral and obturator nerves, both of which have anterior/medial innervation and radiation patterns. Therefore, most intra-articular conditions radiate to the anterior groin or hip.

□ Physical Examination

Knowledge of the anatomy of the anterior part of the hip will allow the astute clinician to focus the physical examination to elucidate the location and type of pathology in each patient. Physical examination should begin with a gait assessment. Patients who have a stress fracture will have difficulty bearing weight on the affected side, and an antalgic gait will be observed. Furthermore, patients with femoroacetabular impingement (FAI) will often have an increased foot progression angle with the affected limb exhibiting more external rotation. Patients with severe osteoarthritis, in addition to those with a variety of other conditions, can have a Trendelenburg gait and sign if the abductors are sufficiently weak to cause pelvic tilt to the affected side when bearing weight solely on the affected extremity.

Careful examination of the hip at rest with the patient sitting over the side of the bed can elucidate causes of hip impingement. In patients with acetabular retroversion, the affected extremity must externally rotate in order for the femoral neck to avoid impingement on the anterior acetabular rim. The range of motion is then assessed and compared with that of the opposite, noninvolved extremity. This assessment includes flexion and extension, with rotation assessed at 90 degrees of hip flexion. Patients who have both FAI and osteoarthritis will often have limited motion, especially internal rotation, with pain at the ends of the range of motion. Crepitation can occasionally be felt with circumduction in this patient population. In patients with FAI, the impingement

Figure 2. Radiograph showing mild dysplasia of the hips.

Figure 3. A, B, Intraoperative arthroscopic images of right hip showing a hypertrophic labrum with contusion.

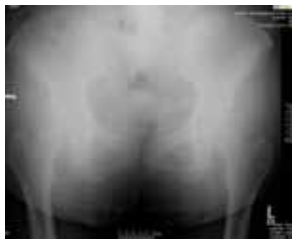

Figure 2

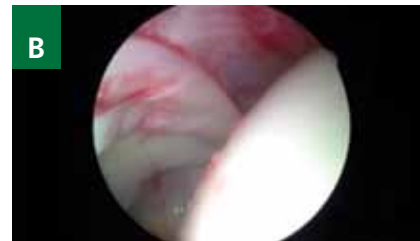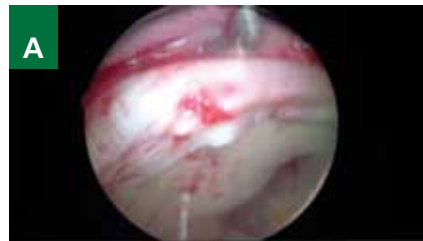


Figure 3

test consisting of adduction and internal rotation will elicit pain. This maneuver can be tested starting at 45 degrees of hip flexion, increasing to around 120 degrees. Patients with more severe impingement will have more pain with less hip flexion.

During the range of motion examination, the hip is brought into maximal flexion/abduction and external rotation and quickly brought back to neutral rotation with the hip straight. Patients with internal snapping of the hip due to bursitis in the iliopsoas will have snapping with this maneuver as the iliopsoas snaps over the iliopectineal eminence or the femoral head. Often downward pressure in this area is needed to feel the snapping of this tendon.

A log-roll examination is performed to determine if intra-articular pathology is causing synovitis of the hip. This examination is performed by internally and externally rotating the hip with the hip relaxed and the knee fully extended. Muscular strength testing is performed to assess the presence of any tendinopathy of the tendons around the hip. Strength testing of the internal and external rotators as well as the adductors is performed with the patient in the seated position. Abductor strength testing is done with the patient in the lateral position. Hip flexion strength testing is performed with the patient in the supine and seated position. The patient with rectus femoris/quadriceps tendonitis will have much more pain with resisted hip flexion in the supine position than in the seated position, whereas the opposite will be true in iliopsoas tendonitis. While the patient is in the supine position, a straight leg examination is performed to help rule out any back conditions that might radiate into the anterior hip. Also in a supine position, the patient is asked to perform a sit-up against resistance to ascertain whether any abdominal wall pathology is present.

Palpation of the hip is extremely important for identifying all hip conditions but especially those in the anterior hip. Palpation

begins on the ASIS and in thin patients over the AIIS to determine if injury to the sartorius or rectus femoris has occurred. In patients with osteitis pubis, palpation just lateral to the symphysis will reveal tenderness.

The above stepwise physical examination will allow the surgeon to formulate a differential diagnosis that can be confirmed by plain radiography, magnetic resonance imaging (MRI), or computed tomography (CT). The specific causes of anterior hip pain are presented in the following section.

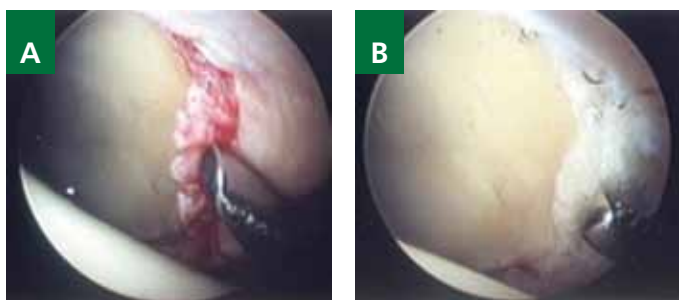
□ Specific Conditions

Stress Fracture

A stress fracture is an insufficient bony healing response caused by an abnormal amount of force acting on a normal bone. The fracture results from either abnormal muscular forces or gait patterns that distribute excessive stress to the underlying bone.¹ Patients typically are long-distance runners who change their frequency, duration, or intensity of training.^{2,3} Additionally, military recruits have typically been shown to have a higher incidence due to their rapid onset of intense training. Patients with a femoral neck stress fracture present with activity-related anterior groin pain that is relieved by rest and often corresponds to an increasing training regimen. These patients will initially be only mildly affected, but as they continue to work through the pain, they become much more symptomatic. Patients who have delayed their presentation almost always have pain with weight bearing and an antalgic gait.

The diagnosis of a femoral neck stress fracture begins with plain radiography, which frequently will be negative. However, with careful inspection increased sclerosis at the inferior neck or a fracture line at the superior neck can occasionally be visualized. In patients where radiographs are negative, the study of choice is MRI to diagnose the stress fracture.⁴ MRI will reveal decreased

Figure 4. A, B, Intraoperative arthroscopic images of right hip labral debridement.



signal intensity on T1 images (black line) or increased intensity on T2 images (Figure 1A).

The location of pathologic changes determines the classification of femoral neck stress fractures.⁵ Inferior neck changes are termed compression-sided stress fractures, whereas superior neck changes indicate a tension-sided stress fracture. If the fracture line extends all the way from the superior to the inferior femoral neck, the fracture is classified as complete. Complete fractures portend impending displacement and require emergent evaluation.

Treatment of femoral neck stress fractures is dictated by the fracture location. Tension-sided fractures are commonly thought to have an increased risk of propagation to the inferior neck and thus are treated much more urgently with percutaneous screw fixation⁴ (Figure 1B). Compression-sided stress fractures are treated with restricted weight bearing and activity modification until symptoms cease. Gradual resumption of activity is allowed only after the patient is completely asymptomatic for a period of time. Any recurrent pain indicates residual stress reaction, and activities need to be ceased. With both of these regimens, treatment for stress fractures is generally successful.⁶

Osteonecrosis

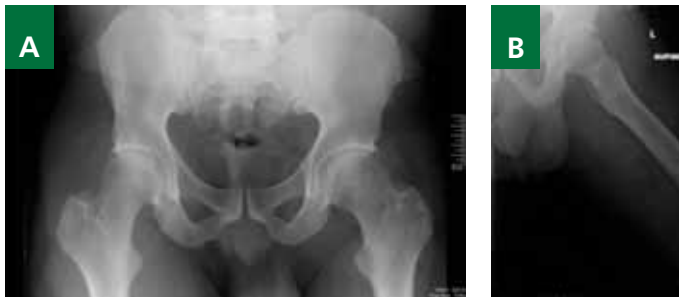Osteonecrosis of the hip can be caused by a variety of derangements. The end state of the hip is collapse due to loss of the structural integrity of the subchondral bone most likely thought to be from decreased blood flow. This necrosis of the femoral head is a debilitating condition since it typically is progressive and affects patients early in life, between 20 and 50 years of age.⁷ Many causes of osteonecrosis have been elucidated, such as trauma, steroids, alcohol, smoking, lupus, sickle-cell anemia, diving, and coagulopathies; however, around 20% of cases have no apparent cause and are identified as idiopathic.^{8,9}

Patients with osteonecrosis of the hip typically present with pain in the groin, which they relate as a deep, intermittent ache. Usually there is no history of trauma, and patients have pain with routine daily activities. Examination findings depend upon the stage of presentation. In patients with early disease, pain will be present only at the extremes of the range of motion; however, in patients with severe disease, a restricted range of motion is evident and most planes of motion are painful.

Plain radiography is frequently diagnostic of osteonecrosis because patients frequently present with advanced disease. Ficat¹⁰ classified osteonecrosis based upon radiographic findings. Stage I is characterized by negative radiographs; stage II, by cystic changes in the femoral head not affecting its shape; stage III, by subchondral collapse; and stage IV, by collapse or deformation of the femoral head. MRI is frequently beneficial in determining the stage and extent of osteonecrosis, as well as the presence of signs of collapse, since it is very sensitive in detecting subtle abnormalities in the bone. Steinberg et al¹¹ developed a classification that is based upon MRI and uses the percentage of the hip involved to further subclassify osteonecrotic lesions.

The treatment of osteonecrosis is controversial since no single intervention has been shown to prevent progression of the disease in all patients.⁹ In addition, the poor results of many interventions for osteonecrosis have further contributed to the controversy regarding treatment for this condition. Generally, treatment is dictated by the stage of the disease. Watchful waiting with conservative management is typically not indicated for progressive symptomatic osteonecrosis since the natural history of osteonecrosis is progressive worsening and ultimate collapse in 80% of patients.⁹ Patients in the early stages without collapse or cartilage damage can be treated with core decompression with or without additional vascularized bone grafting. Effectiveness of these procedures is better for patients in the early stages of disease with good results in

Figure 5. A, B, Radiographs of FAI. The left hip demonstrates combined lesion with crossover sign and ossified labrum with cam lesion of the femoral head-neck junction.



84%-96% of cases in stage I and 47%-74% of cases in stage II.^{12,13} Patients in stage IV of the disease typically require total hip replacement at a young age. Results of total hip replacement in osteonecrosis are typically thought to be inferior to those of hip replacement for osteoarthritis, but comparing results in these 2 different populations is difficult because of age and activity differences.^{14,15}

Labral Tears

Acetabular labral tears have recently been recognized as an increasing cause of hip pain in an active population.¹⁶ Initially, labral tears were thought to be isolated entities¹⁷; however, increasingly they have been associated with structural abnormalities on either the acetabular or the femoral side of the hip such as FAI.¹⁸ In isolation, they have been associated with athletic participation that requires repetitive hip flexion and/or pivoting, such as in hockey, soccer, football, and even running.^{17,19} Other causes of labral tears include dysplasia (Figure 2), instability, trauma, and degeneration.

Patients with labral tears typically present with anterior hip pain radiating to the groin that is associated with activities such as twisting motions, running, walking, and often sitting for prolonged periods. Mechanical symptoms are often variable. Byrd has described the “C” sign in which patients grip their hip just above the greater trochanter with their hand in a “C” shape indicating the site of pathology.²⁰ Examination of the hip reveals a positive impingement sign where the hip is taken into flexion, adduction, and internal rotation and reproduces groin pain.¹⁸ This test relies on the femoral neck impinging on the anterosuperior labrum, where most labral tears occur. Posterior labral tears will have pain reproduced when the patient lies with both legs hanging off the table as the contralateral leg is brought to the patient’s chest while the affected limb is maximally extended. The examiner then forcefully externally rotates the hip, and pain is referred to the posterior hip/buttock.¹⁸

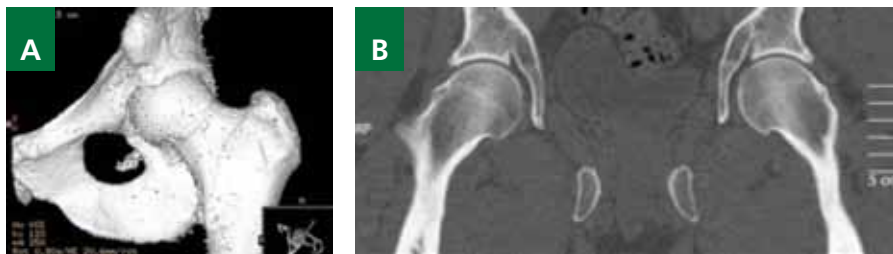
The workup includes radiographs and typically magnetic resonance arthrography (MRA). Radiographs will be helpful only in the case of dysplasia or FAI. MRA is nearly 100% specific for labral tears with the contrast extending into the normally dark labrum on T2 images.²¹ Occasionally, perilabral cysts are seen in association with the labral tear.

The treatment for labral tears continues to be surgical since conservative treatment has shown poor results in restoring function. Despite good results with surgical intervention (Figures 3 and 4), there exists controversy over whether labral tears should be debrided or repaired.¹⁷ A systematic review indicates that good results are possible with labral debridement for up to 3.5 years.²² However, the long-term results of labral debridement are unknown, and it is unclear whether there is an increased risk of arthritis in patients who have labral debridement only. Some authors prefer an anatomic repair over debridement in order to restore normal hip kinematics and hopefully long-term function of the hip.^{23,24} In patients who have a structural abnormality of the hip such as dysplasia or FAI, the structural abnormality needs to be addressed at the time of surgery in order to prevent recurrent tears or failure of the repair.

Femoral Acetabular Impingement

Femoral acetabular impingement exists when there is abnormal contact between the femoral neck and the acetabular rim. Pathology can exist on either the femoral side (cam impingement) or the acetabular side (pincer impingement)²⁵; however, most commonly a combination of abnormal anatomy on both sides is found in patients with FAI.²⁶ In pure cam impingement, the anterior femoral neck loses its normal concave anatomy and has a “bump” that impinges on the anterosuperior labrum, with flexion causing labral tears and delamination of the adjacent cartilage. Pure pincer impingement arises from a prominent acetabular rim causing over-coverage of the femoral head. In pincer impingement, acetabular

Figure 6. A, B, CT scans of left hip with FAI demonstrating both cam and pincer pathologies. B, Note the excess bone along the femoral neck.



labral tears result from the repetitive impaction with flexion and internal rotation.

Patients with FAI report an insidious onset of groin pain that is exacerbated by flexion activities. Squatting, tying shoes, driving, and prolonged sitting all exacerbate the symptoms. FAI can be found in athletes involved in sports that require repetitive flexion and twisting, such as hockey, football, and golf.²⁷ In patients with cartilage damage, even walking or running can cause symptoms without the mechanical irritation of the impingement. Physical examination of patients with FAI reveals findings similar to those found in patients with acetabular labral tears. Severe cases of abnormally large cam lesions or overcoverage result in restriction of the range of motion of the hip, especially internal rotation and flexion, due to a mechanical block. The impingement test is positive in patients with either type of FAI.

Radiographs (Figure 5) are essential to diagnose FAI and distinguish this condition from an isolated labral tear.²⁸ Cam impingement is best demonstrated on a cross-table radiograph, which will show an asphericity of the femoral head/neck junction anteriorly. Pincer impingement will show overcoverage of the femoral head (increased center-edge angle) or retroversion of the acetabulum (cross-over sign) on an anteroposterior (AP) radiograph. MRI or MRA frequently is used to quantify the extent of the pathology, especially to determine if any cartilage deterioration has occurred in association with cam impingement. CT, and in particular 3-dimensional CT, is also extremely helpful as it provides a clear evaluation of the femoral head/neck and acetabulum osseous structure (Figure 6).

Surgical intervention (Figure 7) is often needed since FAI is an abnormal mechanical abutment between the femur and the acetabulum and treatment is aimed at correcting or removing the abnormal anatomy. Currently, both arthroscopic and open

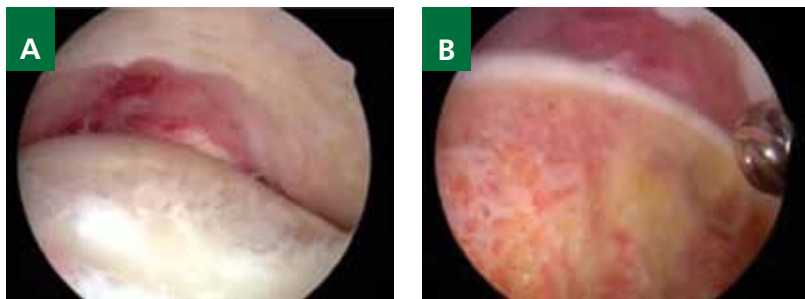
approaches have been recommended to treat both types of FAI.²⁸ For cam impingement, both methods rely on removing bone by osteoplasty at the femoral head/neck junction to allow the femoral neck to clear the labrum with flexion and internal rotation.²⁹ Pincer impingement is treated with detachment of the labrum and removal of the acetabular rim that hangs over the femoral head/neck junction. The labrum is then fixed back to the normally contoured acetabular rim with suture anchors.³⁰ In both types of impingement, labral tears are addressed with fixation or debridement, and cartilage damage is addressed with debridement or microfracture.

Results of both open and arthroscopic osteoplasty of the femur and acetabulum are still preliminary with only a few studies reporting midterm results. Philippon et al reported results at 2 years after arthroscopic osteoplasty.³⁰ Patients had an average satisfaction of 9 (out of 10) with better results in patients with labral fixation. Beck et al reported improvement in 13 of 18 patients with open dislocation.³¹ Open surgeries are associated with longer recovery times and rehabilitation periods than arthroscopic treatment, but advocates relate better ability to contour the femur or acetabulum. It remains to be seen which surgery will result in improved results and, more importantly, less progression to arthritis and the need for hip replacement. Both open and arthroscopic procedures currently have around an 8%-13% rate of revision to hip arthroplasty in short-term follow-up.²⁵

Iliopsoas Tendonitis

Often referred to as internal snapping of the hip or internal coxa saltans, iliopsoas tendonitis/bursitis can be a recalcitrant cause of anterior hip pain. Snapping of the iliopsoas leading to bursitis or tendonitis can occur at 3 different anatomic sites: the iliopectineal eminence, the femoral head, or the lesser trochanter.³² Although the presence of snapping is necessary to cause pathology, its presence is not indicative of pathology. Runners and ballet dancers

Figure 7. Intraoperative arthroscopic images of left hip cam osteoplasty. A, Cam lesion in the peripheral compartment. B, Osteoplasty of the cam lesion.



are frequently noted to have issues with iliopsoas tendonitis.^{33,34} The chronicity of the symptoms will indicate what pathology is present. In patients with relatively acute symptoms, only a bursitis will be present; however, longer duration of symptoms will lead to tendonitis or tendinopathy.³⁵

Patients who have symptomatic iliopsoas tendonitis relate anterior pain that is associated with snapping of the hip. The provocative maneuver that elicits pain is taking the hip from a flexed and externally rotated position to an extended and internal rotated position.³⁴ Most often, the examiner can hear a snap or pop, but occasionally, pressure with one's hand over the iliopsoas tendon is needed to feel the internal snapping. Tenderness in this same area is also diagnostic of tendonitis.

In patients for whom conservative treatment (rest, anti-inflammatories, and physical therapy) has failed, ultrasound is employed to guide a therapeutic and often diagnostic injection of cortisone.³⁶ Because of the ability of ultrasound to detect dynamic differences, the snapping of the iliopsoas can be seen with the above provocative maneuver.³⁷ If a cortisone injection fails, surgical fractional lengthening of the iliopsoas tendon can be performed to eliminate snapping and relieve pain at either the joint or the lesser trochanter (Figure 8).³⁸

Muscular Strains/Avulsion Fractures

Muscular strains can occur in any of the anteriorly located muscles that insert around or cross the hip. In the adult athletic population, the adductor muscle group is most commonly affected. However, in skeletally immature patients, avulsion fractures at the origin of the sartorius and the rectus femoris are more common than muscular strains.

Athletes who have adductor strains typically are involved in either rotational or kicking sports such as soccer, football, hockey, and rugby, where changes in direction are frequently seen in some

position players.³⁹ Typically, an inciting event such as a fall or excessive eccentric contraction during a pivoting maneuver is related as the beginning of the pain. Physical examination reveals quite focal findings with swelling and tenderness confined to the antero-medial aspect of the hip along the adductor muscle group. The patient has tenderness along the adductors and decreased strength with resisted adduction compared with the contralateral side. Very rarely will the patient have a rupture of the adductors off of the pubis, where a defect may be felt.⁴⁰ In patients who have a questionable history or a vague exam, MRI is helpful to determine the true site of pathology.⁴¹ Treatment of adductor strains continues to be nonoperative with rest, ice, and activity modification until tendon healing can occur. In those rare complete tendon avulsions, surgical reattachment is needed if retraction is significant; however, how much retraction is too much is not known.

Avulsions of the sartorius or rectus femoris (Figure 9) in skeletally immature patients are typically seen after a traumatic sporting injury. Sports that require rapid acceleration and deceleration of the hip in an extended position such as soccer, hockey, gymnastics, and track frequently are associated with such avulsion fractures. Adolescents age 14 to 17 are most frequently at risk due to the inherent weakness of the apophysis at the muscular attachments.⁴²

Patients present with a traumatic history and pain, swelling, and tenderness in the affected muscular group. Stretching of the affected muscle also reproduces characteristic pain. Radiographs are diagnostic and will typically show minimal displacement of the apophysis at the ASIS or AIIS.

Treatment is typically conservative with rest, ice, anti-inflammatories, and occasionally physical therapy. Surgical intervention is rarely needed and is indicated only with significant displacement (>2 cm).⁴³ Depending upon the fracture size, use of either suture anchors or screw fixation is warranted.

Figure 8. Intraoperative arthroscopic image showing iliopsoas release at the lesser tuberosity.

Figure 9. Image showing rupture of the left rectus femoris.

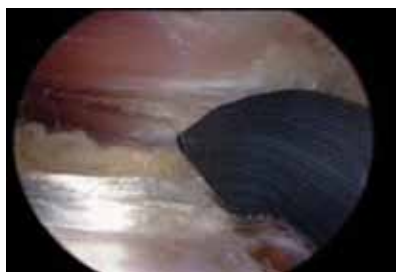


Figure 8

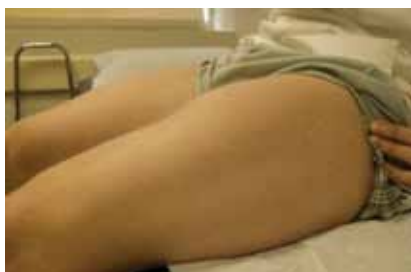

Figure 9

Osteitis Pubis

Osteitis pubis is an infrequent cause of anterior hip pain that affects males much more commonly than females. The term *osteitis pubis* has been used to describe a number of conditions that affect the area surrounding the symphysis pubis. Injuries to the rectus muscles or pubic symphysis, infection, and hormonal conditions that affect pre- or postpartum females have been known to cause this condition. As with most injuries around the hip, twisting or rotation sports are frequently associated with this condition in athletes, making the diagnosis difficult.^{44,45}

Patients with osteitis pubis present with pain over the anterior aspect of the pelvis that is worse with sit-ups, rising from a chair, or any activity where contraction of the rectus muscles occurs.³² Pain radiates into the rectus muscles, and occasionally spasm in the muscles surrounding the pubis is encountered. Tenderness is elicited directly over and just lateral to the symphysis. Radiographs are frequently negative, but occasionally chronic degenerative changes at the symphysis are present in addition to symphyseal narrowing. If instability is present, 1-legged stance images will show diastasis or superior migration of one ramus in relationship to the other. Additional imaging is often necessary for diagnosis; MRI and bone scans are used to localize the pathology to the symphysis pubis. MRI and bone scans will show localized pathology to the pubis just adjacent to the symphysis; however, MRI is frequently nonspecific.⁴⁶

The treatment of osteitis pubis is nearly always nonsurgical with rest, anti-inflammatories, and physical therapy to gently stretch the musculature around the pelvis and work on core strengthening. If conservative measures fail, a localized steroid injection can be considered. Surgical management of refractory cases includes curettage, mesh placement, or stabilization, all of which have varied results and none of which has shown superiority over

others.⁴⁷ Radic and Annear recently published results showing a good return to sport in athletes treated with curettage.⁴⁵

Sports Hernia

Sports hernia, also referred to as athletic pubalgia, continues to be an enigmatic condition causing anterior hip pain in the athlete. Arriving at this diagnosis can be challenging, and patients can have lingering symptoms for years before receiving the diagnosis of sports hernia.⁴⁸ Unlike other hernias (inguinal, abdominal, etc), a sports hernia typically does not involve a bulge of tissue protruding through one body part into another. In contrast, a sports hernia occurs when the oblique abdominal muscles strain or completely tear away from their attachment to the pubis. A recent systematic review of the literature has shown that the underlying etiology of sports hernias involves posterior inguinal wall weakening, which can be a result of poorly balanced hip adductor and abdominal muscle activation.⁴⁹

Patients with sports hernia will typically present with anterior hip and/or groin pain, especially with hip extension, twisting, and turning. In addition, patients can have pain in the lower abdomen and (for males) in the testicles. Physical examination will usually show pubic point tenderness, which is exacerbated by resisted hip adduction.⁵⁰ MRI and ultrasound⁴⁹ are extremely helpful in assisting with diagnosis and forming a treatment plan.⁵¹

The initial treatment of choice for sports hernias is conservative, and the first step is always activity modification or temporary absence from symptom-producing activities. Additional modalities include anti-inflammatories, ice, and physical therapy to strengthen the surrounding muscles. While controversy exists regarding appropriate surgical treatment,⁵² surgical intervention with an internal oblique flap reinforced with mesh has proven to be successful.^{50,52}

□ General Rehabilitation Considerations

Rehabilitation following a hip injury that results in anterior hip pain will be determined by injury location, type and mechanism of injury, and severity of the pathology. Restriction of weight bearing through use of an assistive device may be utilized to prevent excessive stress on bony and supporting soft-tissue structures during the early stages of healing. Physical therapy initially should focus on early controlled range of motion of the hip joint to prevent both intra- and extra-articular adhesions and excessive scar tissue formation.⁵³ Postoperatively, tightness of the posterior hip capsule as well as the anterior and posterior musculature is a common finding in this population. Soft-tissue and joint mobilization may be utilized to address areas of soft-tissue restriction and capsular tightness in order to restore mobility and symmetrical range of motion.⁵⁴ Improvements in muscle firing patterns have also been observed following manual therapy techniques. Strengthening of the supporting hip joint musculature should focus on the hip abductor group, the anterior and posterior thigh musculature, and the core stabilizing muscles. Neuromuscular reeducation should be utilized to promote normal biomechanics and minimize compensatory movement patterns. A cardiovascular training program may be used to restore fitness to competitive athletes, and a return-to-sport program should be implemented before return to unrestricted training and full competition.⁵³⁻⁵⁵

□ Conclusions

Anterior hip pain is often poorly understood yet remains a common complaint in the athletic population. The location of pathology ranges from to the underlying bony anatomy of the hip to the supporting soft-tissue structures and can be difficult to assess clinically. In the athletic population, anterior hip pain covers a broad spectrum of conditions, including stress fractures, osteonecrosis, labral tears, femoral acetabular impingement, iliopsoas tendonitis, osteitis pubis, muscle strains/avulsion fractures, and sports hernia. Although many of these conditions can be alleviated with non-surgical management, the clinician should have a low threshold to refer athletes with persistent hip and groin pain to an orthopedic surgeon specializing in hip joint preservation surgery. The workup should begin with plain radiographs, but advanced imaging with MRI, MRA, or CT may be appropriate. An intra-articular injection with local anesthetics and steroid can be both diagnostic and therapeutic. The treatment options depend on the diagnosis and vary from activity modification to surgical intervention. With an improved understanding of athletic hip pathology, health care providers will be better equipped to handle anterior hip and groin injuries. ■

References

1. Stanitski CL, McMaster JH, Scranton PE. On the nature of stress fractures. *Am J Sports Med.* 1978;6(6):391-396.
2. Fredericson M, Jennings F, Beaulieu C, Matheson GO. Stress fractures in athletes. *Top Magn Reson Imaging.* 2006;17(5):309-325.
3. Matheson GO, Clement DB, McKenzie DC, Taunton JE, Lloyd-Smith DR, MacIntyre JG. Stress fractures in athletes: a study of 320 cases. *Am J Sports Med.* 1987;15(1):46-58.
4. Shin AY, Gillingham BL. Fatigue fractures of the femoral neck in athletes. *J Am Acad Orthop Surg.* 1997;5(6):293-302.
5. Fullerton LR Jr, Snowdy HA. Femoral neck stress fractures. *Am J Sports Med.* 1988;16(4):365-377.
6. Aro H, Dahlström S. Conservative management of distraction-type stress fractures of the femoral neck. *J Bone Joint Surg Br.* 1986;68(1):65-67.
7. Mont MA, Hungerford DS. Non-traumatic avascular necrosis of the femoral head. *J Bone Joint Surg Am.* 1995;77(3):459-474.
8. Lavernia CJ, Sierra RJ, Gomez-Marin O. Smoking and joint replacement: resource consumption and short-term outcome. *Clin Orthop Relat Res.* 1999;(367):172-180.
9. Lavernia CJ, Sierra RJ, Grieco FR. Osteonecrosis of the femoral head. *J Am Acad Orthop Surg.* 1999;7(4):250-261.
10. Ficat P. Vascular pathology of femoral head necrosis [in German]. *Orthopade.* 1980;9(4):238-244.
11. Steinberg ME, Hayken GD, Steinberg DR. A quantitative system for staging avascular necrosis. *J Bone Joint Surg Br.* 1995;77(1):34-41.
12. Fairbank AC, Bhatia D, Jinnah RH, Hungerford DS. Long-term results of core decompression for ischaemic necrosis of the femoral head. *J Bone Joint Surg Br.* 1995;77(1):42-49.
13. Smith SW, Fehring TK, Griffin WL, Beaver WB. Core decompression of the osteonecrotic femoral head. *J Bone Joint Surg Am.* 1995;77(5):674-680.
14. Chandler HP, Reineck FT, Wixson RL, McCarthy JC. Total hip replacement in patients younger than thirty years old: a five-year follow-up study. *J Bone Joint Surg Am.* 1981;63(9):1426-1434.
15. Wei SY, Klimkiewicz JJ, Lai M, Garino JB, Steinberg ME. Revision total hip arthroplasty in patients with avascular necrosis. *Orthopedics.* 1999;22(8):747-757.
16. Byrd JW, Jones KS. Traumatic rupture of the ligamentum teres as a source of hip pain. *Arthroscopy.* 2004;20(4):385-391.
17. Burnett RS, Della Rocca GJ, Prather H, Curry M, Maloney WJ, Clohisy JC. Clinical presentation of patients with tears of the acetabular labrum. *J Bone Joint Surg Am.* 2006;88(7):1448-1457.
18. Shindle MK, Voos JE, Nho SJ, Heyworth BE, Kelly BT. Arthroscopic management of labral tears in the hip. *J Bone Joint Surg Am.* 2008;90(suppl 4):2-19.
19. Bare AA, Guanche CA. Hip impingement: the role of arthroscopy. *Orthopedics.* 2005;28(3):266-273.
20. Byrd JW, Jones KS. Diagnostic accuracy of clinical assessment, magnetic resonance imaging, magnetic resonance arthrography, and intra-articular injection in hip arthroscopy patients. *Am J Sports Med.* 2004;32(7):1668-1674.
21. Toomayan GA, Holman WR, Major NM, Kozlowicz SM, Vail TP. Sensitivity of MR arthrography in the evaluation of acetabular labral tears. *AJR Am J Roentgenol.* 2006;186(2):449-453.

22. Robertson WJ, Kadmas WR, Kelly BT. Arthroscopic management of labral tears in the hip: a systematic review of the literature. *Clin Orthop Relat Res.* 2007;455:88-92.
23. Larson CM, Giveans MR. Arthroscopic debridement versus refixation of the acetabular labrum associated with femoroacetabular impingement. *Arthroscopy.* 2009;25(4):369-376.
24. Larson CM, Guanche CA, Kelly BT, Clohisy JC, Ranawat AS. Advanced techniques in hip arthroscopy. *Instr Course Lect.* 2009;58:423-436.
25. Bedi A, Chen N, Robertson W, Kelly BT. The management of labral tears and femoroacetabular impingement of the hip in the young, active patient. *Arthroscopy.* 2008;24(10):1135-1145.
26. Guanche CA, Bare AA. Arthroscopic treatment of femoroacetabular impingement. *Arthroscopy.* 2006;22(1):95-106.
27. Philippon M, Schenker M, Briggs K, Kuppersmith D. Femoroacetabular impingement in 45 professional athletes: associated pathologies and return to sport following arthroscopic decompression. *Knee Surg Sports Traumatol Arthrosc.* 2007;15(7):908-914.
28. Sierra RJ, Trousdale RT, Ganz R, Leunig M. Hip disease in the young, active patient: evaluation and nonarthroplasty surgical options. *J Am Acad Orthop Surg.* 2008;16(12):689-703.
29. Byrd JW, Jones KS. Prospective analysis of hip arthroscopy with 10-year followup. *Clin Orthop Relat Res.* 2010;468(3):741-746.
30. Philippon MJ, Kuppersmith DA, Wolff AB, Briggs KK. Arthroscopic findings following traumatic hip dislocation in 14 professional athletes. *Arthroscopy.* 2009;25(2):169-174.
31. Beck M, Leunig M, Parvizi J, Boutier V, Wyss D, Ganz R. Anterior femoroacetabular impingement, part II: midterm results of surgical treatment. *Clin Orthop Relat Res.* 2004;(418):67-73.
32. Tibor LM, Sekiya JK. Differential diagnosis of pain around the hip joint. *Arthroscopy.* 2008;24(12):1407-1421.
33. Holmich P. Long-standing groin pain in sportspeople falls into three primary patterns, a "clinical entity" approach: a prospective study of 207 patients. *Br J Sports Med.* 2007;41(4):247-252; discussion 252.
34. Winston P, Awan R, Cassidy JD, Bleakney RK. Clinical examination and ultrasound of self-reported snapping hip syndrome in elite ballet dancers. *Am J Sports Med.* 2007;35(1):118-126.
35. Blankenbaker DG, De Smet AA, Keene JS. Sonography of the iliopsoas tendon and injection of the iliopsoas bursa for diagnosis and management of the painful snapping hip. *Skeletal Radiol.* 2006;35(8):565-571.
36. Adler RS, Buly R, Ambrose R, Sculco T. Diagnostic and therapeutic use of sonography-guided iliopsoas peritendinous injections. *AJR Am J Roentgenol.* 2005;185(4):940-943.
37. Pelsser V, Cardinal E, Hobden R, Aubin B, Lafortune M. Extraarticular snapping hip: sonographic findings. *AJR Am J Roentgenol.* 2001;176(1):67-73.
38. Anderson SA, Keene JS. Results of arthroscopic iliopsoas tendon release in competitive and recreational athletes. *Am J Sports Med.* 2008;36(12):2363-2371.
39. Maffey L, Emery C. What are the risk factors for groin strain injury in sport? a systematic review of the literature. *Sports Med.* 2007;37(10):881-894.
40. Vogt S, Ansah P, Imhoff AB. Complete osseous avulsion of the adductor longus muscle: acute repair with three fiberwire suture anchors. *Arch Orthop Trauma Surg.* 2007;127(8):613-615.
41. Verrall GM, Slavotinek JP, Fon GT, Barnes PG. Outcome of conservative management of athletic chronic groin injury diagnosed as pubic bone stress injury. *Am J Sports Med.* 2007;35(3):467-474.
42. Kocher MS, Tucker R. Pediatric athlete hip disorders. *Clin Sports Med.* 2006;25(2):241-253, viii.
43. Pointinger H, Munk P, Poeschl GP. Avulsion fracture of the anterior superior iliac spine following apophysitis. *Br J Sports Med.* 2003;37(4):361-362.
44. Johnson R. Osteitis pubis. *Curr Sports Med Rep.* 2003;2(2):98-102.
45. Radic R, Annear P. Use of pubic symphysis curettage for treatment-resistant osteitis pubis in athletes. *Am J Sports Med.* 2008;36(1):122-128.
46. Paaanen H, Hermunen H, Karonen J. Pubic magnetic resonance imaging findings in surgically and conservatively treated athletes with osteitis pubis compared to asymptomatic athletes during heavy training. *Am J Sports Med.* 2008;36(1):117-121.
47. Choi H, McCartney M, Best TM. Treatment of osteitis pubis and osteomyelitis of the pubic symphysis in athletes: a systematic review. *Br J Sports Med.* 2011;45(1):57-64.
48. Unverzag CA, Schuemann T, Mathisen J. Differential diagnosis of a sports hernia in a high-school athlete. *J Orthop Sports Phys Ther.* 2008;38(2):63-70.
49. Caudill P, Nyland J, Smith C, Yerasimides J, Lach J. Sports hernias: a systematic literature review. *Br J Sports Med.* 2008;42(12):954-964.
50. Ahumada LA, Ashruf S, Espinosa-de-los-Monteros A, et al. Athletic pubalgia: definition and surgical treatment. *Ann Plast Surg.* 2005;55(4):393-396.
51. Meyers WC, McKechnie A, Philippon MJ, Horner MA, Zoga AC, Devon ON. Experience with "sports hernia" spanning two decades. *Ann Surg.* 2008;248(4):656-665.
52. Anderson K, Strickland SM, Warren R. Hip and groin injuries in athletes. *Am J Sports Med.* 2001;29(4):521-533.
53. Ensekri KR, Martin RL, Draovitch P, Kelly BT, Philippon MJ, Schenker ML. The hip joint: arthroscopic procedures and postoperative rehabilitation. *J Orthop Sports Phys Ther.* 2006;36(7):516-525.
54. Stalzer S, Wahoff M, Scanlan M. Rehabilitation following hip arthroscopy. *Clin Sports Med.* 2006;25(2):337-357, x.
55. Voight M, Robinson K, Gill L, Griffin K. Postoperative rehabilitation guidelines for hip arthroscopy in an active population. *Sports Health.* 2010;2(3):222-230.

The Technique of Acetabular Distraction for the Reconstruction of Severe Acetabular Defects With an Associated Chronic Pelvic Discontinuity

SCOTT M. SPORER, MD, MS; ANDREW MICHAEL, MD; WAYNE G. PAPROSKY, MD; MARIO MORIC, MS

“PELVIC DISCONTINUITY RESULTS IN A MORE CHALLENGING ENVIRONMENT IN WHICH TO OBTAIN INITIAL COMPONENT FIXATION DUE TO THE POSSIBILITY OF PERSISTENT MOTION BETWEEN THE SUPERIOR AND INFERIOR HALVES OF THE PELVIS.”

□ Author Affiliations

Department of Orthopedic Surgery, Rush University Medical Center, Chicago, Illinois (Drs Sporer and Paprosky); Drexel University, Philadelphia, Pennsylvania (Dr Michael); Rush University Medical Center, Chicago, Illinois (Mr Moric).

□ Corresponding Author

Andrew Michael, MD; Drexel University, 629 Carroll Dr, Hummelstown, PA 17036 (DrDrew83@gmail.com).

□ Introduction

The prevalence of pelvic discontinuity, a condition resulting in separation of the superior and inferior portions of the pelvis, will likely increase due to total joint replacement being utilized in younger and more active patients. Well-fixed cementless acetabular components can create a situation in which osteolysis and stress shielding can progress asymptotically.¹ The severity of bone loss can be pronounced by the time the cup migrates or the patient begins to have symptoms. Similarly, migration of a cemented acetabular component over a period of time can result in a large amount of bone destruction.² A successful acetabular reconstruction requires either a stable mechanical construct that gains its

stability solely through supplemental fixation (screws, spikes, flange) or a biologic construct that will allow bone ingrowth into the acetabular component. In order to achieve bone ingrowth into an acetabular component, the initial reconstruction must minimize micromotion and the surrounding milieu must remain biologically active.

Pelvic discontinuity results in a more challenging environment in which to obtain initial component fixation due to the possibility of persistent motion between the superior and inferior halves of the pelvis. Several authors have suggested compression plating of the posterior column with the use of a hemispherical acetabular component.²⁻⁴ The goal of this surgical technique is to rigidly fix the discontinuity in order to obtain bony union between the superior and inferior hemipelvis and to minimize micromotion of a hemispherical component in order to allow bone ingrowth. Adequate posterior column bone to allow both stable plate fixation as well as direct bone apposition is a prerequisite for this method of reconstruction. However, in certain situations where the amount of bone loss along the posterior column is severe, rigid stability and direct bony apposition cannot be obtained. In these situations, an acetabular cage can be used to bridge the defect and obtain

Figure 1. Tantalum elliptical cup spanning the pelvic discontinuity. A superior augment was used in this case.

Figure 2. Well-fixed porous tantalum metal cup. No cup migration or hardware failure can be seen at 6 years postoperatively.

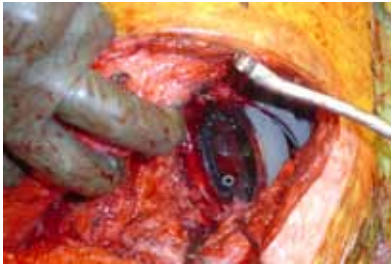


Figure 1

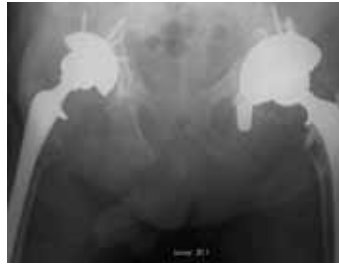


Figure 2

relative fixation along the iliac wing and ischium. The results of this mechanical solution for a chronic pelvic discontinuity are poor because bone ingrowth into the acetabular cage will not occur and prolonged micromotion and stress upon the mechanical construct persist.⁵ The purpose of this review is to describe a technique of acetabular distraction using a porous tantalum acetabular component with or without a porous tantalum augment in patients with a chronic pelvic discontinuity. We hypothesized that a reconstruction using porous tantalum components placed into a distracted acetabular pelvis would provide enough initial mechanical stability for bone ingrowth to occur into the prosthesis and/or augment both superiorly and inferiorly in order to bridge and stabilize the pelvic discontinuity.

□ Materials and Methods

Twenty-eight consecutive patients undergoing revision total hip arthroplasty treated with a porous tantalum acetabular component with or without augments in the setting of a chronic pelvic discontinuity between 2002 and 2006 were identified through our institutional data repository. These patients' medical records were retrospectively reviewed following study approval by our institutional review board. This cohort of patients represents an unselected series of patients treated for a chronic pelvic discontinuity as no other patient during this time underwent posterior column plating or was treated with an acetabular cage.

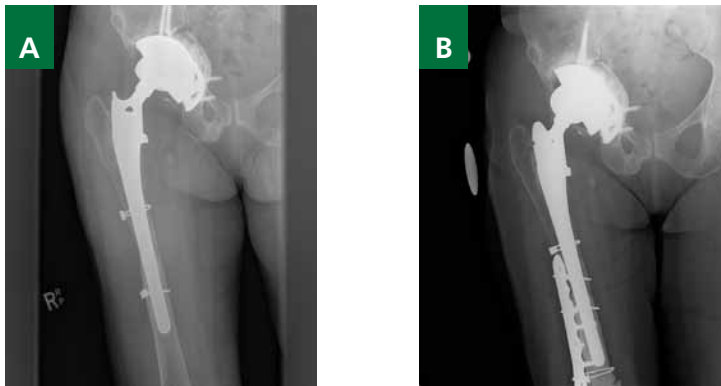
At the time of most recent follow-up, 5 patients had been lost to follow-up and 3 additional patients had died from causes unrelated to the revision procedure prior to minimum 2-year follow-up. These 8 patients were excluded from the study cohort. The remaining 20 patients had an average follow-up of 54 months (range, 24 to 84 months). Of these patients, 15 were female while

5 were male. The average age at the time of the revision procedure was 67.5 years (range, 46 to 86 years), and the average number of previous surgeries was 2.6 (range, 0 to 6). Of the patients in the follow-up group, the original diagnosis was osteoarthritis in 10 patients, rheumatoid arthritis in 9 patients, and developmental dysplasia of the hip in 1 patient. The reason for revision in all 20 patients in the follow-up group was aseptic loosening. The acetabular defects were classified using the system described by one of the senior authors (W.P.).⁶ Four of the acetabula were classified as Paprosky type IIC, 3 were type IIIA, and the remaining 13 were type IIIB. All patients had an associated pelvic discontinuity that was verified intraoperatively.

Surgical Technique

The surgery was performed by one of the senior authors (W.P., S.S.) through a posterior approach. After the acetabular component was explanted, the lower portion of the ischium was stressed with a Cobb elevator, and motion between the superior and inferior portions of the acetabulum confirmed the presence of a discontinuity. All fibrous tissue and granulation tissue was cleared between the discontinuity in order to uncover viable host bone. Full hemispherical reamers were then placed in the acetabular defect at the level of the native hip center in order to determine the anterior-posterior dimension of the pelvic defect. Sequentially larger reamers were utilized until the reamers engaged the anterior-superior and posterior-inferior margins of the acetabulum. The type and position of the augments was dictated by the location and severity of bone loss. Augments were frequently used to reconstruct portions of the anterior-superior acetabulum as well as the posterior-inferior acetabulum to provide secure points of fixation for the acetabular component cephalad and caudal to the discontinuity (Figure 1). Attempts were made to maximize the amount of host

Figure 3. A, Well-fixed cup 39 months after surgery. B, Same patient seen 50 months after surgery; migration of the cup is noted.



bone contact with the porous tantalum augments and acetabular component. The superior and inferior hemipelvis was distracted by placing a porous tantalum acetabular component that was 6 to 8 mm larger than the hemispherical reamer that had previously engaged to anterior and posterior columns. Ligamentotaxis was used to provide initial stability to the cup while multiple screws were placed into the remaining ilium and ischium. The augments when used were secured to the porous tantalum acetabular component with the use of polymethyl methacrylate. A polyethylene liner was cemented into the acetabular component in all cases in order to provide screws with a fixed angle.⁷ Tantalum metal augments were used in 11 of the 20 hips. In 3 of the 11 patients, 2 augments were used. The femoral head size was maximized in all patients. Two patients with deficient abductors had a constrained liner, 9 patients had a tripolar articulation due to a retained femoral component, 6 had a 40-mm head size, 1 had a 36-mm head size, and 2 had a 32-mm head size.

All patients were examined clinically and radiographically at 2 weeks, 6 weeks, 3 months, 6 months, and yearly thereafter for a minimum of 2 years. The assessment of clinical improvement was done with the modified Postel–Merle d’Aubigné score by one of the authors (A.M., S.S., W.P.). Clinical outcome measures included the Merle d’Aubigné walking and pain scores. The preoperative and postoperative scores were compared using a paired *t* test to test for a significant improvement in ambulation and pain scores.

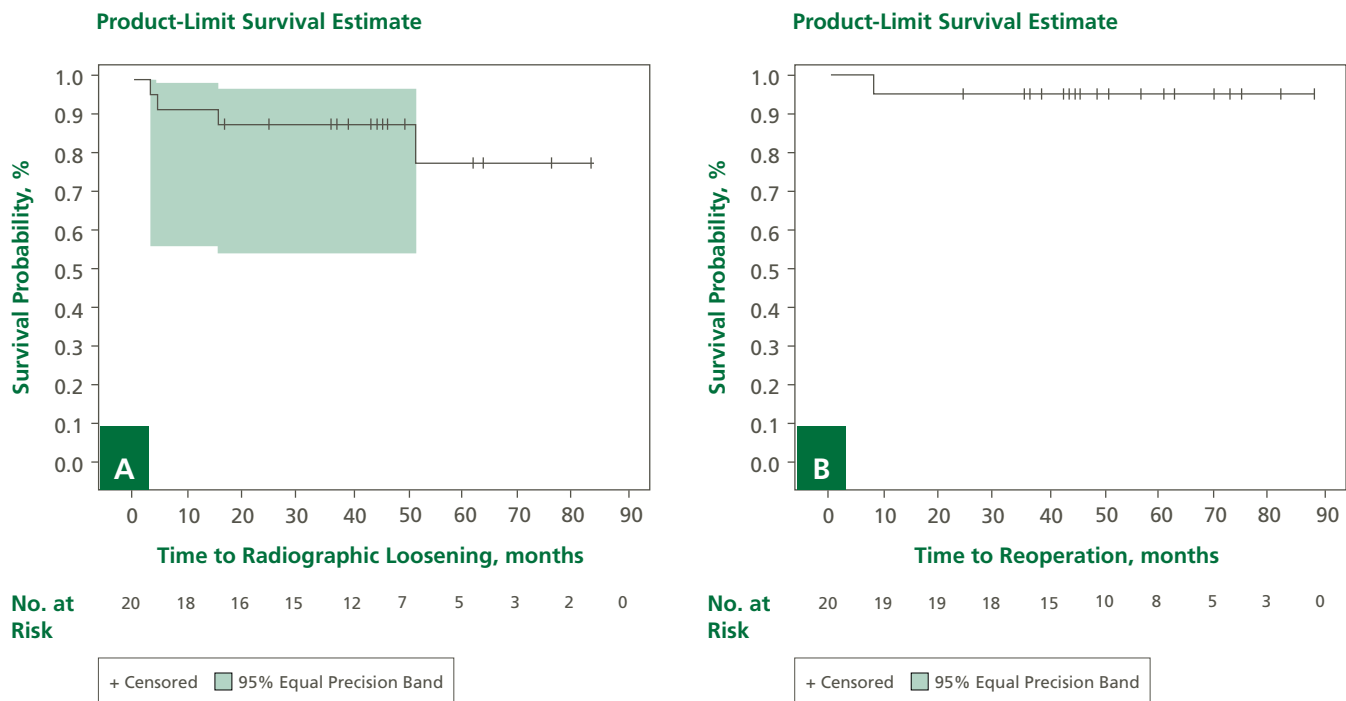
Radiographic review consisted of standard anteroposterior (AP) radiographs of the pelvis, AP radiographs of the femur, and Lowenstein lateral radiographs. Radiographs taken preoperatively, immediately postoperatively, and at the most recent follow-up

were reviewed and the findings were consensually agreed upon by 2 reviewers (S.S. and A.M.) (Figure 2). The AP radiographs taken preoperatively were graded according to the acetabular defect classification described by Bradford and Paprosky.⁸ The most recent radiographs were compared with the initial postoperative radiographs. Loosening was defined radiographically as a change in the component abduction angle of greater than 10 degrees or a change in the horizontal or vertical position of greater than 6 mm after correcting for magnification (Figure 3). Kaplan–Meier curves showing time to failure for radiographic loosening as well as reoperation for clinical failure were created (Figure 4).

□ Results

Among the 20 patients with a minimum of 2-year follow-up, 1 construct failed, necessitating revision surgery (Figure 5). Upon radiographic review of the 19 clinically stable patients, 4 acetabular components were classified as loose due to component migration at an average of 18 months follow-up. All loose acetabular components were in patients with a type IIIB acetabular defect. All radiographs considered to be loose demonstrated increased vertical inclination, superior migration, and loss of fixation into the ischium. Two radiographic cases demonstrating loosening were identified within the first year of follow-up, 1 was identified within 2 years of follow-up, and 1 was noted at the 4-year follow-up. Two of these 4 also had fracture of the screws that were placed in the inferior augments or into the inferior portion of the acetabular component (Figure 6). All the implants classified as loose have since remained stable over an average period of 49 months, showing well-ingrown cup with no further migration.

Figure 4. Kaplan-Meier curves. **A,** Time elapsed from date of surgery to diagnosis of radiographic loosening. **B,** Time elapsed from date of surgery to reoperation for clinical failure.



Clinically, 17 of 19 patients reported having no pain on the operative hip, 1 patient reports minimal pain after walking 6 blocks or more, and 1 patient reports pain with sitting for long periods of time. Seven patients are walking without assistive devices, 5 patients use a cane all the time to ambulate, 4 patients use a cane only for long distances, and 3 patients use a walker at all times. None of the patients in this study used wheelchairs as of the most recent follow-up. The average improvement using the modified Merle d'Aubigné pain and ambulation score was from 3.3 preoperatively to 9.6 postoperatively ($P < .0001$, standard deviation 1.2). The 4 patients with radiographically loose components at most recent follow-up were pain free and functioning well with an average Merle d'Aubigné score improvement of 3 preoperatively to 8.75 postoperatively ($P < .0012$, standard deviation 0.96). Associated perioperative complications included a colon rupture requiring general surgical intervention, an intraoperative femoral artery injury requiring repair by a vascular surgeon, a greater trochanteric fracture that was treated nonoperatively, and a superficial infection successfully treated with irrigation and debridement. At the time of most recent follow-up, there were no postoperative dislocations.

□ Discussion

There are few studies evaluating the treatment and outcomes of chronic pelvic discontinuities encountered at the time of revision acetabular surgery. Most of the available literature on the subject is in the form of an analysis of these difficult cases as a subset of a large, diverse revision series. Berry et al identified pelvic discontinuities in 31 of 3505 patients (0.9%) requiring revision hip surgery.² The use of a posterior column pelvic reconstruction plate with an associated cementless acetabular component was shown to provide the highest rate of healing across the discontinuity assuming the discontinuity was not a result of radiation necrosis. Morcellized bone graft protected by an antiprotrusion cage has also been shown to result in acceptable clinical and radiographic results at short-term follow-up.² Egli et al reported on 7 cases of pelvic discontinuity treated with pelvic plating and acetabular reinforcement rings. One patient had incomplete sciatic nerve palsy, 1 had recurrent dislocations, and 1 needed reoperation for aseptic loosening. However, at final follow-up all discontinuities had healed and the acetabular components were believed to be stable.⁹ DeBoer et al reported on the use of a custom triflanged device (DePuy,

Figure 5. A, Well-fixed prosthesis. **B,** The cup has migrated cephalad and has become more horizontal. The patient was symptomatic and necessitated a revision.

Figure 6. Broken screws can be seen as this cup has migrated from its previously well-fixed position. The patient is now 6 years postoperative, and no further component migration has occurred. The patient remains asymptomatic.

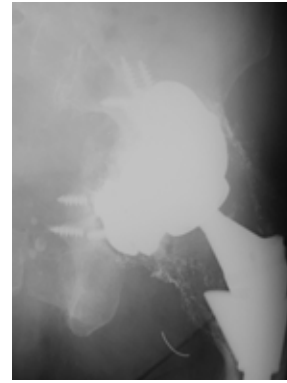
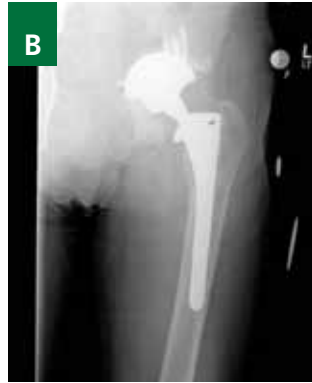
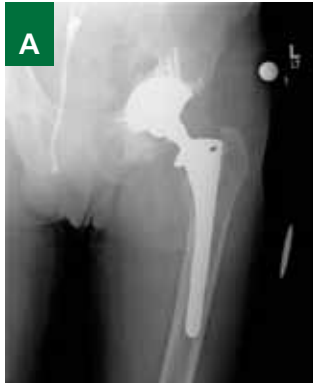
Figure 5

Figure 6

Warsaw, Indiana) in 20 hips with severe pelvic bone loss and discontinuity at an average follow-up of 10 years. Definite healing was demonstrated radiographically in 18 of 20 hips with no cases of implant migration. However, 6 cases had nonprogressive radiolucent lines, 1 case had partial sciatic nerve palsy, and 5 patients had 1 or more dislocations.¹⁰ Holt and Dennis reported on the use of a custom triflanged device in 26 hips. In this series, however, only 3 of the 26 hips had a pelvic discontinuity. Two of these 3 failed secondary to loss of inferior fixation in the ischium. The authors recommended caution in the use of the device without additional column plating.¹¹

Currently, most studies recommended compression plating of the posterior column to reduce and stabilize the pelvis in an attempt to create a solid platform for acetabular reconstruction.^{9,11-12} However, the severity of bone loss encountered during acetabular reconstruction may result in large segmental areas of deficient bone making the possibility of healing between the superior and inferior hemipelvis unlikely.

We have previously reported poor intermediate results with the use of acetabular cages in the treatment of pelvic discontinuity when bulk acetabular allograft along with an acetabular cage was used in patients with chronic pelvic discontinuities. In this series, 16 hips had been followed for an average of 5 years postoperatively.⁵ Five of these hips were revised for loosening while an additional 3 hips were radiographically loose. In these situations, it was hypothesized that the discontinuity did not heal and that

persistent micromotion across the discontinuity resulted in fatigue of the cage and eventual failure. Consequently, we believe that durable acetabular fixation in a patient with an associated chronic pelvic discontinuity with severe posterior column bone loss can occur only if there is bony healing of the discontinuity or if there is bony ingrowth into a porous acetabular component from both the superior and inferior hemipelvis. In cases of chronic pelvic discontinuity, we believe the biologic potential for healing at the discontinuity is decreased and that it is unlikely most chronic discontinuities will eventually heal. We describe a surgical technique that relies upon pelvic distraction in an attempt to gain rigid initial fixation to an acetabular component both caudal and cephalad to the discontinuity. The goal of this technique is to use the porous acetabular component as an internal plate to span the discontinuity rather than rely on biologic healing across the discontinuity. This surgical technique allows for potential biologic ingrowth into the acetabular component cephalad and caudal to the discontinuity. We feel that compared to the poor results with use of cage constructs, it offers a greater opportunity for a biologic solution that could potentially lead to better patient outcomes and improved component survival. We previously compared 12 patients with pelvic discontinuities that were treated with a porous tantalum metal cup with 12 patients in a previous cohort who were treated with a cage construct.¹³ In our 2005 study we found that treatment with a porous tantalum metal shell offered a reproducible and consistent improvement in pain and ambulation at an average of 2.1

years follow-up. In 2006, we produced a 2.6-year follow-up of 13 patients with pelvic discontinuities treated with a porous tantalum shell who showed improved Postel–Merle d’Aubigné scores from 6.1 to 10.3.¹⁴ These results showed promising outcomes in short-term follow-up.

In our current study, 15 of 20 hips remained clinically and radiographically stable at an average of 4.5 years postoperatively while 4 of the 20 hips demonstrated early superior migration of the acetabular component. However, all 4 patients that demonstrated early component migration have shown no further change in position radiographically, and all patients remain pain free. Only 1 cup (5%) required revision for loosening. The cause of this failure was believed to be inadequate fixation into the ischium, and we now strive to obtain a minimum of 2 screws into the ischium to avoid early vertical displacement of the acetabular component. In our series, we had no postoperative dislocations and only 1 superficial infection. We hypothesize that our decreased rate of infection compared to our series of patients with posterior column plating and acetabular cage reconstruction was secondary to decreased surgical time and minimizing the amount of soft-tissue stripping.

Extensive bone loss is frequently observed in the setting of a chronic pelvic discontinuity. In order to achieve long-term success in these difficult cases, either the pelvis must be stabilized to allow healing of the discontinuity or alternative methods to bridge the discontinuity must be utilized. We present the midterm results of a potential biologic solution in patients with a chronic pelvic discontinuity using the technique of pelvic distraction. This technique appears to have promise for these difficult cases of severe bone loss and compromised biologic healing potential. ■

References

1. Howie DW, Neale SD, Stamenkov R, McGee MA, Taylor DJ, Findlay DM. Progression of acetabular periprosthetic osteolytic lesions measured with computed tomography. *J Bone Joint Surg Am.* 2007;89(8):1818-1825.
2. Berry DJ, Lewallen DG, Hanssen AD, Cabanela ME. Pelvic discontinuity in revision total hip arthroplasty. *J Bone Joint Surg Am.* 1999;81(12):1692-1702.
3. Berry DJ. Identification and management of pelvic discontinuity. *Orthopedics.* 2001;24(9):881-882.
4. Della Valle CJ, Berger RA, Rosenberg AG, Galante JO. Cementless acetabular reconstruction in revision total hip arthroplasty. *Clin Orthop Relat Res.* 2004;(420):96-100.
5. Paprosky W, Sporer S, O’Rourke MR. The treatment of pelvic discontinuity with acetabular cages. *Clin Orthop Relat Res.* 2006;453:183-187.
6. Paprosky WG, Perona PG, Lawrence JM. Acetabular defect classification and surgical reconstruction in revision arthroplasty: a 6-year follow-up evaluation. *J Arthroplasty.* 1994;9(1):33-44.
7. Laflamme GY, Alami GB, Zhim F. Cement as a locking mechanism for screw heads in acetabular revision shells—a biomechanical analysis. *Hip Int.* 2008;18(1):29-34.
8. Bradford MS, Paprosky WG. Acetabular defect classification: a detailed radiographic approach. *Semin Arthroplasty.* 1995;6(2):76-85.
9. Eggl S, Müller C, Ganz R. Revision surgery in pelvic discontinuity: an analysis of seven patients. *Clin Orthop Relat Res.* 2002;(398):136-145.
10. DeBoer DK, Christie MJ, Brinson MF, Morrison JC. Revision total hip arthroplasty for pelvic discontinuity. *J Bone Joint Surg Am.* 2007;89(4):835-840.
11. Holt GE, Dennis DA. Use of custom triflanged acetabular components in revision total hip arthroplasty. *Clin Orthop Relat Res.* 2004;(429):209-214.
12. Stiehl JB, Saluja R, Diener T. Reconstruction of major column defects and pelvic discontinuity in revision total hip arthroplasty. *J Arthroplasty.* 2000;15(7):849-857.
13. Paprosky WG, O’Rourke M, Sporer SM. The treatment of acetabular bone defects with an associated pelvic discontinuity. *Clin Orthop Relat Res.* 2005;441:216-220.
14. Sporer SM, Paprosky WG. Acetabular revision using a trabecular metal acetabular component for severe acetabular bone loss associated with a pelvic discontinuity. *J Arthroplasty.* 2006;21(6)(suppl 2):87-90.

□ **An, Howard S.**

Anderson DG, Markova D, Adams SL, Pacifici M, An HS, Zhang Y. Fibronectin splicing variants in human intervertebral disc and association with disc degeneration. *Spine (Phila Pa 1976)*. 2010;35(17):1581-1588.

Kim JS, Ellman MB, An HS, van Wijnen AJ, Borgia JA, Im HJ. Insulin-like growth factor 1 synergizes with bone morphogenetic protein 7-mediated anabolism in bovine intervertebral disc cells. *Arthritis Rheum*. 2010;62(12):3706-3715.

Otsuka Y, An HS, Ochia RS, Andersson GB, Espinoza Orías AA, Inoue N. In vivo measurement of lumbar facet joint area in asymptomatic and chronic low back pain subjects. *Spine (Phila Pa 1976)*. 2010;35(8):924-928.

Park DK, An HS, Lurie JD, Zhao W, Tosteson A, Tosteson TD, Herkowitz H, Errico T, Weinstein JN. Does multilevel lumbar stenosis lead to poorer outcomes?: a subanalysis of the Spine Patient Outcomes Research Trial (SPORT) lumbar stenosis study. *Spine (Phila Pa 1976)*. 2010;35(4):439-446.

Takatori R, Tokunaga D, Hase H, Mikami Y, Ikeda T, Harada T, Imai K, Ito H, Nishimura T, An HS, Inoue N, Kubo T. Three-dimensional morphology and kinematics of the craniovertebral junction in rheumatoid arthritis. *Spine (Phila Pa 1976)*. 2010;35(23):E1278-E1284.

Weinstein JN, Tosteson TD, Lurie JD, Tosteson A, Blood E, Herkowitz H, Cammisa F, Albert T, Boden SD, Hilibrand A, Goldberg H, Berven S, An H. Surgical versus nonoperative treatment for lumbar spinal stenosis four-year results of the Spine Patient Outcomes Research Trial. *Spine (Phila Pa 1976)*. 2010;35(14):1329-1338.

□ **Andersson, Gunnar B. J.**

Andersson GB, Chapman JR, Dekutoski MB, Dettori J, Fehlings MG, Fourney DR, Norvell D, Weinstein JN. Do no harm: the balance of “beneficence” and “non-maleficence”. *Spine (Phila Pa 1976)*. 2010;35(9)(suppl):S2-S8.

□ **Bach, Bernard R., Jr**

Frank RM, Seroyer ST, Lewis PB, Bach BR Jr, Verma NN. MRI analysis of tibial position of the anterior cruciate ligament. *Knee Surg Sports Traumatol Arthrosc*. 2010;18(11):1607-1611.

Grumet RC, Bach BR Jr, Provencher MT. Arthroscopic stabilization for first-time versus recurrent shoulder instability. *Arthroscopy*. 2010;26(2):239-248.

Pensak M, Grumet RC, Slabaugh MA, Bach BR Jr. Open versus arthroscopic distal clavicle resection. *Arthroscopy*. 2010;26(5):697-704.

Piasecki DP, Bach BR Jr. Anatomical single-bundle anterior cruciate ligament reconstruction with a transtibial technique. *Am J Orthop (Belle Mead NJ)*. 2010;39(6):302-304.

Provencher MT, Bhatia S, Ghodadra NS, Grumet RC, Bach BR Jr, Dewing CB, LeClere L, Romeo AA. Recurrent shoulder instability: current concepts for evaluation and management of glenoid bone loss. *J Bone Joint Surg Am*. 2010;92(suppl 2):133-151.

□ **Berger, Richard A.**

Berger RA, Della Valle CJ. Unicompartmental knee arthroplasty: indications, techniques, and results. *Instr Course Lect*. 2010;59:47-56.

Hartman CW, Ting NT, Moric M, Berger RA, Rosenberg AG, Della Valle CJ. Revision total knee arthroplasty for stiffness. *J Arthroplasty*. 2010;25(6)(suppl):62-66.

□ **Cole, Brian J.**

Burkhart SS, Cole BJ. Bridging self-reinforcing double-row rotator cuff repair: we really are doing better. *Arthroscopy*. 2010;26(5):677-680.

Cole BJ, Pascual-Garrido C, Grumet RC. Surgical management of articular cartilage defects in the knee. *Instr Course Lect*. 2010;59:181-204.

Friel NA, Karas V, Slabaugh MA, Cole BJ. Outcomes of type II superior labrum, anterior to posterior (SLAP) repair: prospective evaluation at a minimum two-year follow-up. *J Shoulder Elbow Surg*. 2010;19(6):859-867.

Greco NJ, Anderson AF, Mann BJ, Cole BJ, Farr J, Nissen CW, Irrgang JJ. Responsiveness of the International Knee Documentation Committee Subjective Knee Form in comparison to the Western Ontario and McMaster Universities Osteoarthritis Index, modified Cincinnati Knee Rating System, and Short Form 36 in patients with focal articular cartilage defects. *Am J Sports Med*. 2010;38(5):891-902.

Grumet RC, Friel NA, Cole BJ. Bony avulsion of the medial ulnar collateral ligament in a gymnast: a case report. *J Shoulder Elbow Surg.* 2010;19(7):e1-e6.

Kang RW, Friel NA, Williams JM, Cole BJ, Wimmer MA. Effect of impaction sequence on osteochondral graft damage: the role of repeated and varying loads. *Am J Sports Med.* 2010;38(1):105-113.

Slabaugh MA, Frank RM, Cole BJ. Resurfacing of isolated articular cartilage defects in the glenohumeral joint with microfracture: a surgical technique & case report. *Am J Orthop (Belle Mead NJ).* 2010;39(7):326-332.

Slabaugh MA, Friel NA, Cole BJ. Rapid chondrolysis of the knee after anterior cruciate ligament reconstruction: a case report. *J Bone Joint Surg Am.* 2010;92(1):186-189.

Van Thiel GS, Sheehan S, Frank RM, Slabaugh M, Cole BJ, Nicholson GP, Romeo AA, Verma NN. Retrospective analysis of arthroscopic management of glenohumeral degenerative disease. *Arthroscopy.* 2010;26(11):1451-1455.

□ Della Valle, Craig J.

Buvanendran A, Kroin JS, Della Valle CJ, Kari M, Moric M, Tuman KJ. Perioperative oral pregabalin reduces chronic pain after total knee arthroplasty: a prospective, randomized, controlled trial. *Anesth Analg.* 2010;110(1):199-207.

Della Valle C, Parvizi J, Bauer TW, Dicesare PE, Evans RP, Segreti J, Spangehl M, Watters WC III, Keith M, Turkelson CM, Wies JL, Sluka P, Hitchcock K. Diagnosis of periprosthetic joint infections of the hip and knee. *J Am Acad Orthop Surg.* 2010;18(12):760-770.

Della Valle CJ, Dittle E, Moric M, Sporer SM, Buvanendran A. A prospective randomized trial of mini-incision posterior and two-incision total hip arthroplasty. *Clin Orthop Relat Res.* 2010;468(12):3348-3354.

Della Valle CJ, Haidukewych GJ, Callaghan JJ. Periprosthetic fractures of the hip and knee: a problem on the rise but better solutions. *Instr Course Lect.* 2010;59:563-575.

Jacofsky DJ, Della Valle CJ, Meneghini RM, Sporer SM, Cercek RM; American Academy of Orthopaedic Surgeons. Revision total knee arthroplasty: what the practicing orthopaedic surgeon needs to know. *J Bone Joint Surg Am.* 2010;92(5):1282-1292.

Parvizi J, Della Valle CJ. AAOS Clinical Practice Guideline: diagnosis and treatment of periprosthetic joint infections of the hip and knee. *J Am Acad Orthop Surg.* 2010;18(12):771-772.

Schwartz AJ, Della Valle CJ, Rosenberg AG, Jacobs JJ, Berger RA, Galante JO. Cruciate-retaining TKA using a third-generation system with a four-pegged tibial component: a minimum 10-year followup note. *Clin Orthop Relat Res.* 2010;468(8):2160-2167.

Sheth NP, Lieberman JR, Della Valle CJ. DVT prophylaxis in total joint reconstruction. *Orthop Clin North Am.* 2010;41(2):273-280.

Wera GD, Ting NT, Della Valle CJ, Sporer SM. External iliac artery injury complicating prosthetic hip resection for infection. *J Arthroplasty.* 2010;25(4):660.e1-660.e4.

□ Espinoza Orías, Alejandro A.

Ritacco LE, Espinoza Orías AA, Aponte-Tinao L, Muscolo DL, de Quirós FG, Inoue N. Three-dimensional morphometric analysis of the distal femur: a validity method for allograft selection using a virtual bone bank. *Stud Health Technol Inform.* 2010;160(pt 2):1287-1290.

Takigawa T, Espinoza Orías AA, An HS, Gohgi S, Udayakumar RK, Sugisaki K, Natarajan RN, Wimmer MA, Inoue N. Spinal kinematics and facet load transmission after total disc replacement. *Spine (Phila Pa 1976).* 2010;35(22):E1160-E1166.

□ Foucher, Kharma C.

Foucher KC, Thorp LE, Orozco D, Hildebrand M, Wimmer MA. Differences in preferred walking speeds in a gait laboratory compared with the real world after total hip replacement. *Arch Phys Med Rehabil.* 2010;91(9):1390-1395.

Shakoor N, Sengupta M, Foucher KC, Wimmer MA, Fogg LF, Block JA. Effects of common footwear on joint loading in osteoarthritis of the knee. *Arthritis Care Res (Hoboken).* 2010;62(7):917-923.

□ Gitelis, Steven

Miller IJ, Blank A, Yin SM, McNickle A, Gray R, Gitelis S. A case of recurrent giant cell tumor of bone with malignant transformation and benign pulmonary metastases. *Diagn Pathol.* 2010;5:62.

□ Glant, Tibor T.

Angyal A, Egelston C, Kobezda T, Olasz K, László A, Glant TT, Mikecz K. Development of proteoglycan-induced arthritis depends on T cell-supported autoantibody production, but does not involve significant influx of T cells into the joints. *Arthritis Res Ther.* 2010;12(2):R44.

Carulli D, Pizzorusso T, Kwok JC, Putignano E, Poli A, Forostyak S, Andrews MR, Deepa SS, Glant TT, Fawcett JW. Animals

continued on next page

lacking link protein have attenuated perineuronal nets and persistent plasticity. *Brain*. 2010;133(pt 8):2331-2347.

de Jong H, Berlo SE, Hombrink P, Otten HG, van Eden W, Lafeber FP, Heurkens AH, Bijlsma JW, Glant TT, Prakken BJ. Cartilage proteoglycan aggrecan epitopes induce proinflammatory autoreactive T-cell responses in rheumatoid arthritis and osteoarthritis. *Ann Rheum Dis*. 2010;69(1):255-262.

□ Hallab, Nadim J.

Hallab NJ. A review of the biologic effects of spine implant debris: fact from fiction. *SAS J*. 2010;4(3):143-160.

Deirmengian C, Hallab N, Tarabishy A, Della Valle C, Jacobs JJ, Lonner J, Booth RE Jr. Synovial fluid biomarkers for periprosthetic infection. *Clin Orthop Relat Res*. 2010;468(8):2017-2023.

Hallab NJ, Caicedo M, Epstein R, McAllister K, Jacobs JJ. In vitro reactivity to implant metals demonstrates a person-dependent association with both T-cell and B-cell activation. *J Biomed Mater Res A*. 2010;92(2):667-682.

Langton DJ, Jameson SS, Joyce TJ, Hallab NJ, Natu S, Nargol AV. Early failure of metal-on-metal bearings in hip resurfacing and large-diameter total hip replacement: a consequence of excess wear. *J Bone Joint Surg Br*. 2010;92(1):38-46.

Smith RA, Hallab NJ. In vitro macrophage response to polyethylene and polycarbonate-urethane particles. *J Biomed Mater Res A*. 2010;93(1):347-355.

Smith RA, Maghsoodpour A, Hallab NJ. In vivo response to cross-linked polyethylene and polycarbonate-urethane particles. *J Biomed Mater Res A*. 2010;93(1):227-234.

□ Hammerberg, Kim W.

Cahill PJ, Warnick DE, Lee MJ, Gaughan J, Vogel LE, Hammerberg KW, Sturm PF. Infection after spinal fusion for pediatric spinal deformity: thirty years of experience at a single institution. *Spine (Phila Pa 1976)*. 2010;35(12):1211-1217.

Serhan H, Hammerberg K, O'Neil M, Sturm P, Mardjetko S, Crawford A. Intraoperative techniques to reduce the potential of set-screw loosening in long spinal constructs: a static and fatigue biomechanical investigation. *J Spinal Disord Tech*. 2010;23(7):e31-e36.

□ Jacobs, Joshua J.

Caicedo MS, Pennekamp PH, McAllister K, Jacobs JJ, Hallab NJ.

Soluble ions more than particulate cobalt-alloy implant debris induce monocyte costimulatory molecule expression and release of proinflammatory cytokines critical to metal-induced lymphocyte reactivity. *J Biomed Mater Res A*. 2010;93(4):1312-1321.

Catelas I, Jacobs JJ. Biologic activity of wear particles. *Instr Course Lect*. 2010;59:3-16.

Schemitsch EH, Bhandari M, Boden SD, Bourne RB, Bozic KJ, Jacobs JJ, Zdero R. The evidence-based approach in bringing new orthopaedic devices to market. *J Bone Joint Surg Am*. 2010;92(4):1030-1037.

□ Levine, Brett

Levine B, Fabi D, Deirmengian C. Digital templating in primary total hip and knee arthroplasty. *Orthopedics*. 2010;33(11):797.

Ting NT, Wera GD, Levine BR, Della Valle CJ. Early experience with a novel nonmetallic cable in reconstructive hip surgery. *Clin Orthop Relat Res*. 2010;468(9):2382-2386.

□ Maki, Carl

Maki CG. Decision-making by p53 and mTOR. *Aging (Albany NY)*. 2010;2(6):324-326.

Moran DM, Maki CG. Nutlin-3a induces cytoskeletal rearrangement and inhibits the migration and invasion capacity of p53 wild-type cancer cells. *Mol Cancer Ther*. 2010;9(4):895-905.

Shen H, Maki CG. p53 and p21(Waf1) are recruited to distinct PML-containing nuclear foci in irradiated and Nutlin-3a-treated U2OS cells. *J Cell Biochem*. 2010;111(5):1280-1290.

Shen H, Maki CG. Persistent p21 expression after Nutlin-3a removal is associated with senescence-like arrest in 4N cells. *J Biol Chem*. 2010;285(30):23105-23114.

□ Mikecz, Katalin

Boldizsar F, Kis-Toth K, Tarjanyi O, Olasz K, Hegyi A, Mikecz K, Glant TT. Impaired activation-induced cell death promotes spontaneous arthritis in antigen (cartilage proteoglycan)-specific T cell receptor-transgenic mice. *Arthritis Rheum*. 2010;62(10):2984-2994.

Boldizsar F, Mikecz K, Glant TT. Immunosenescence and its potential modulation: lessons from mouse models. *Expert Rev Clin Immunol*. 2010;6(3):353-357.

Doodles PD, Cao Y, Hamel KM, Wang Y, Rodeghero RL, Mikecz K, Glant TT, Iwakura Y, Finnegan A. IFN-gamma regulates the

requirement for IL-17 in proteoglycan-induced arthritis. *J Immunol.* 2010;184(3):1552-1559.

Wiranowska M, Ladd S, Moscinski LC, Hill B, Haller E, Mikecz K, Plaas A. Modulation of hyaluronan production by CD44 positive glioma cells. *Int J Cancer.* 2010;127(3):532-542.

□ Natarajan, Raghu N.

Bresnahan L, Fessler RG, Natarajan RN. Evaluation of change in muscle activity as a result of posterior lumbar spine surgery using a dynamic modeling system. *Spine (Phila Pa 1976).* 2010;35(16):E761-E767.

Hussain M, Natarajan RN, An HS, Andersson GB. Motion changes in adjacent segments due to moderate and severe degeneration in C5-C6 disc: a poroelastic C3-T1 finite element model study. *Spine (Phila Pa 1976).* 2010;35(9):939-947.

Hussain M, Natarajan RN, An HS, Andersson GB. Reduction in segmental flexibility because of disc degeneration is accompanied by higher changes in facet loads than changes in disc pressure: a poroelastic C5-C6 finite element investigation. *Spine J.* 2010;10(12):1069-1077.

□ Nho, Shane J.

Bhatia S, Piasecki DP, Nho SJ, Romeo AA, Cole BJ, Nicholson GP, Boniquit N, Verma NN. Early return to work in workers' compensation patients after arthroscopic full-thickness rotator cuff repair. *Arthroscopy.* 2010;26(8):1027-1034.

DeFranco MJ, Nho S, Romeo AA. Scapulothoracic fusion. *J Am Acad Orthop Surg.* 2010;18(4):236-242.

Diklic ID, Ganic ZD, Blagojevic ZD, Nho SJ, Romeo AA. Treatment of locked chronic posterior dislocation of the shoulder by reconstruction of the defect in the humeral head with an allograft. *J Bone Joint Surg Br.* 2010;92(1):71-76.

Kepler CK, Nho SJ, Bansal M, Ala OL, Craig EV, Wright TM, Warren RF. Radiographic and histopathologic analysis of osteolysis after total shoulder arthroplasty. *J Shoulder Elbow Surg.* 2010;19(4):588-595.

Nam D, Kepler CK, Nho SJ, Craig EV, Warren RF, Wright TM. Observations on retrieved humeral polyethylene components from reverse total shoulder arthroplasty. *J Shoulder Elbow Surg.* 2010;19(7):1003-1012.

Nho SJ, Delos D, Yadav H, Pensak M, Romeo AA, Warren RF, MacGillivray JD. Biomechanical and biologic augmentation

for the treatment of massive rotator cuff tears. *Am J Sports Med.* 2010;38(3):619-629.

Nho SJ, Frank RM, Reiff SN, Verma NN, Romeo AA. Arthroscopic repair of anterosuperior rotator cuff tears combined with open biceps tenodesis. *Arthroscopy.* 2010;26(12):1667-1674.

Nho SJ, Frank RM, Van Thiel GS, Wang FC, Wang VM, Provencher MT, Verma NN. A biomechanical analysis of anterior Bankart repair using suture anchors. *Am J Sports Med.* 2010;38(7):1405-1412.

Nho SJ, Frank RM, Van Thiel GS, Wang FC, Wang VM, Provencher MT, Verma NN. A biomechanical analysis of shoulder stabilization: posteroinferior glenohumeral capsular plication. *Am J Sports Med.* 2010;38(7):1413-1419.

Nho SJ, Frank RM, Verma NN, Romeo AA. Incidence of early development of radiolucent lines in keeled polyethylene glenoid components after total shoulder arthroplasty. *Am J Orthop (Belle Mead NJ).* 2010;39(7):333-337.

Nho SJ, Pensak MJ, Seigerman DA, Cole BJ. Rehabilitation after autologous chondrocyte implantation in athletes. *Clin Sports Med.* 2010;29(2):267-282, viii.

Nho SJ, Reiff SN, Verma NN, Slabaugh MA, Mazzocca AD, Romeo AA. Complications associated with subpectoral biceps tenodesis: low rates of incidence following surgery. *J Shoulder Elbow Surg.* 2010;19(5):764-768.

Nho SJ, Strauss EJ, Lenart BA, Provencher MT, Mazzocca AD, Verma NN, Romeo AA. Long head of the biceps tendinopathy: diagnosis and management. *J Am Acad Orthop Surg.* 2010;18(11):645-656.

Pensak M, Nho SJ, Alland J, Bach BR. Management of acute anterior shoulder instability in adolescents. *Orthop Nurs.* 2010;29(4):237-243; quiz 244-245.

Reiff SN, Nho SJ, Romeo AA. Proximal humerus fracture after keyhole biceps tenodesis. *Am J Orthop (Belle Mead NJ).* 2010;39(7):E61-E63.

Seroyer ST, Nho SJ, Provencher MT, Romeo AA. Four-quadrant approach to capsulolabral repair: an arthroscopic road map to the glenoid [published correction appears in *Arthroscopy.* 2010;26(6):866]. *Arthroscopy.* 2010;26(4):555-562.

Slabaugh MA, Nho SJ, Grumet RC, Wilson JB, Seroyer ST, Frank RM, Romeo AA, Provencher MT, Verma NN. Does the literature confirm superior clinical results in radiographically healed rotator cuffs after rotator cuff repair? *Arthroscopy.* 2010;26(3):393-403.

continued on next page

Strauss EJ, Nho SJ, Kelly BT. Greater trochanteric pain syndrome. *Sports Med Arthrosc.* 2010;18(2):113-119.

□ Nicholson, Gregory P.

Nicholson GP, Twigg S, Blatz B, Sturonas-Brown B, Wilson J. Subscapularis lengthening in shoulder arthroplasty. *J Shoulder Elbow Surg.* 2010;19(3):427-433.

□ Paprosky, Wayne

Flecher X, Paprosky W, Grillo JC, Aubaniac JM, Argenson JN. Do tantalum components provide adequate primary fixation in all acetabular revisions? *Orthop Traumatol Surg Res.* 2010;96(3):235-241.

□ Phillips, Frank M.

Isaacs RE, Hyde J, Goodrich JA, Rodgers WB, Phillips FM. A prospective, nonrandomized, multicenter evaluation of extreme lateral interbody fusion for the treatment of adult degenerative scoliosis: perioperative outcomes and complications. *Spine (Phila Pa 1976).* 2010;35(26)(suppl):S322-S330.

McAfee PC, Cappuccino A, Cunningham BW, Devine JG, Phillips FM, Regan JJ, Albert TJ, Ahrens JE. Lower incidence of dysphagia with cervical arthroplasty compared with ACDF in a prospective randomized clinical trial. *J Spinal Disord Tech.* 2010;23(1):1-8.

McAfee PC, Phillips FM, Andersson G, Buvenenadran A, Kim CW, Laurysen C, Isaacs RE, Youssef JA, Brodke DS, Cappuccino A, Akbarnia BA, Mundis GM, Smith WD, Uribe JS, Garfin S, Allen RT, Rodgers WB, Pimenta L, Taylor W. Minimally invasive spine surgery. *Spine (Phila Pa 1976).* 2010;35(26)(suppl):S271-S273.

Mundis GM, Akbarnia BA, Phillips FM. Adult deformity correction through minimally invasive lateral approach techniques. *Spine (Phila Pa 1976).* 2010;35(26)(suppl):S312-S321.

□ Rauch, Tibor A.

Choi JH, Li Y, Guo J, Pei L, Rauch TA, Kramer RS, Macmil SL, Wiley GB, Bennett LB, Schnabel JL, Taylor KH, Kim S, Xu D, Sreekumar A, Pfeifer GP, Roe BA, Caldwell CW, Bhalla KN, Shi H. Genome-wide DNA methylation maps in follicular lymphoma cells determined by methylation-enriched bisulfite sequencing. *PLoS One.* 2010;5(9):e13020.

Dunwell T, Hesson L, Rauch TA, Wang L, Clark RE, Dallol A, Gentle D, Catchpole D, Maher ER, Pfeifer GP, Latif F. A

genome-wide screen identifies frequently methylated genes in haematological and epithelial cancers. *Mol Cancer.* 2010;9:44.

Lee DH, Singh P, Tsai SY, Oates N, Spalla A, Spalla C, Brown L, Rivas G, Larson G, Rauch TA, Pfeifer GP, Szabó PE. CTCF-dependent chromatin bias constitutes transient epigenetic memory of the mother at the H19-Igf2 imprinting control region in prospermatogonia. *PLoS Genet.* 2010;6(11):e1001224.

Rauch TA, Pfeifer GP. DNA methylation profiling using the methylated-CpG island recovery assay (MIRA). *Methods.* 2010;52(3):213-217.

Wu X, Rauch TA, Zhong X, Bennett WP, Latif F, Krex D, Pfeifer GP. CpG island hypermethylation in human astrocytomas. *Cancer Res.* 2010;70(7):2718-2727.

□ Romeo, Anthony A.

Baker CL III, Baker CL Jr, Romeo AA. Osteochondritis dissecans of the capitellum. *J Shoulder Elbow Surg.* 2010;19(2)(suppl):76-82.

Baker CL III, Romeo AA, Baker CL Jr. Osteochondritis dissecans of the capitellum. *Am J Sports Med.* 2010;38(9):1917-1928.

Forsythe B, Ghodadra N, Romeo AA, Provencher MT. Management of the failed posterior/multidirectional instability patient. *Sports Med Arthrosc.* 2010;18(3):149-161.

Frank RM, Van Thiel GS, Slabaugh MA, Romeo AA, Cole BJ, Verma NN. Clinical outcomes after microfracture of the glenohumeral joint. *Am J Sports Med.* 2010;38(4):772-781.

Geaney LE, Miller MD, Ticker JB, Romeo AA, Guerra JJ, Bollier M, Arciero RA, DeBerardino TM, Mazzocca A. Management of the failed AC joint reconstruction: causation and treatment. *Sports Med Arthrosc.* 2010;18(3):167-172.

Ghodadra N, Gupta A, Romeo AA, Bach BR Jr, Verma N, Shewman E, Goldstein J, Provencher MT. Normalization of glenohumeral articular contact pressures after Latarjet or iliac crest bone-grafting. *J Bone Joint Surg Am.* 2010;92(6):1478-1489.

Heckman DS, Creighton RA, Romeo AA. Management of failed biceps tenodesis or tenotomy: causation and treatment. *Sports Med Arthrosc.* 2010;18(3):173-180.

Lattermann C, Romeo AA, Anbari A, Meiningner AK, McCarty LP, Cole BJ, Cohen MS. Arthroscopic debridement of the extensor carpi radialis brevis for recalcitrant lateral epicondylitis. *J Shoulder Elbow Surg.* 2010;19(5):651-656.

Provencher MT, Arciero RA, Burkhart SS, Levine WN, Ritting AW, Romeo AA. Key factors in primary and revision surgery for shoulder instability. *Instr Course Lect.* 2010;59:227-244.

Provencher MT, Ghodadra N, Romeo AA. Arthroscopic management of anterior instability: pearls, pitfalls, and lessons learned. *Orthop Clin North Am.* 2010;41(3):325-337.

Provencher MT, Handfield K, Boniquit NT, Reiff SN, Sekiya JK, Romeo AA. Injuries to the pectoralis major muscle: diagnosis and management. *Am J Sports Med.* 2010;38(8):1693-1705.

Romeo AA, Ghodadra NS, Salata MJ, Provencher MT. Arthroscopic suprascapular nerve decompression: indications and surgical technique. *J Shoulder Elbow Surg.* 2010;19(2)(suppl):118-123.

□ Rosenberg, Aaron

Meneghini RM, Cornwell P, Guthrie M, Moore HD, Abou-Trabi D, Rosenberg AG. A novel method for prevention of intraoperative fracture in cementless hip arthroplasty: vibration analysis during femoral component insertion. *Surg Technol Int.* 2010;20:334-339.

Rosenberg A. Encountering cancer or its sequelae at the hip. *Orthopedics.* 2010;33(9):630.

□ Singh, Kern

Park DK, Lee MJ, Lin EL, Singh K, An HS, Phillips FM. The relationship of intrapsoas nerves during a transpsoas approach to the lumbar spine: anatomic study. *J Spinal Disord Tech.* 2010;23(4):223-228.

□ Sporer, Scott M.

Berend KR, Sporer SM, Sierra RJ, Glassman AH, Morris MJ. Achieving stability and lower-limb length in total hip arthroplasty. *J Bone Joint Surg Am.* 2010;92(16):2737-2752.

Shukla SK, Ward JP, Jacofsky MC, Sporer SM, Paprosky WG, Della Valle CJ. Perioperative testing for persistent sepsis following resection arthroplasty of the hip for periprosthetic infection. *J Arthroplasty.* 2010;25(6)(suppl):87-91.

Sporer SM, Della Valle C. Porous metal augments: big hopes for big holes. *Orthopedics.* 2010;33(9):651.

Wright G, Sporer S, Urban R, Jacobs J. Fracture of a modular femoral neck after total hip arthroplasty: a case report. *J Bone Joint Surg Am.* 2010;92(6):1518-1521.

□ Verma, Nikhil N.

Dodson CC, Kitay A, Verma NN, Adler RS, Nguyen J, Cordasco FA, Altchek DW. The long-term outcome of recurrent defects after rotator cuff repair. *Am J Sports Med.* 2010;38(1):35-39.

Goldstein JL, Verma N, McNickle AG, Zelazny A, Ghodadra N, Bach BR Jr. Avoiding mismatch in allograft anterior cruciate ligament reconstruction: correlation between patient height and patellar tendon length. *Arthroscopy.* 2010;26(5):643-650.

Piasecki DP, Verma NN, Nho SJ, Bhatia S, Boniquit N, Cole BJ, Nicholson GP, Romeo AA. Outcomes after arthroscopic revision rotator cuff repair. *Am J Sports Med.* 2010;38(1):40-46.

Strauss EJ, Barker JU, McGill K, Verma NN. The evaluation and management of failed distal clavicle excision. *Sports Med Arthrosc.* 2010;18(3):213-219.

Verma NN, Bhatia S, Baker CL III, Cole BJ, Boniquit N, Nicholson GP, Romeo AA. Outcomes of arthroscopic rotator cuff repair in patients aged 70 years or older. *Arthroscopy.* 2010;26(10):1273-1280.

□ Virkus, Walter W.

Miller BJ, Virkus WW. Intercalary allograft reconstructions using a compressible intramedullary nail: a preliminary report. *Clin Orthop Relat Res.* 2010;468(9):2507-2513.

Sah AP, Marshall A, Virkus W, Estok DM II, Della Valle CJ. Interprosthetic fractures of the femur: treatment with a single-locked plate. *J Arthroplasty.* 2010;25(2):280-286.

□ Wang, Vincent M.

Slabaugh MA, Friel NA, Wang VM, Cole BJ. Restoring the labral height for treatment of Bankart lesions: a comparison of suture anchor constructs. *Arthroscopy.* 2010;26(5):587-591.

Van Thiel GS, Wang VM, Wang FC, Nho SJ, Piasecki DP, Bach BR Jr, Romeo AA. Biomechanical similarities among subscapularis repairs after shoulder arthroplasty. *J Shoulder Elbow Surg.* 2010;19(5):657-663.

Wang VM, Wang FC, McNickle AG, Friel NA, Yanke AB, Chubinskaya S, Romeo AA, Verma NN, Cole BJ. Medial versus lateral supraspinatus tendon properties: implications for double-row rotator cuff repair. *Am J Sports Med.* 2010;38(12):2456-2463.

□ Wimmer, Markus A.

Bajaj S, Shoemaker T, Hakimiyan AA, Rappoport L, Pascual-Garrido C, Oegema TR, Wimmer MA, Chubinskaya S. Protective effect of P188 in the model of acute trauma to human ankle cartilage: the mechanism of action. *J Orthop Trauma.* 2010;24(9):571-576.

Galetz MC, Uth T, Wimmer MA, Adam P, Glatzel U. Determination of the temperature rise within UHMWPE tibial components during tribological loading. *Acta Biomater.* 2010;6(2):552-562.

continued on next page

Görke UJ, Günther H, Nagel T, Wimmer MA. A large strain material model for soft tissues with functionally graded properties. *J Biomech Eng.* 2010;132(7):074502.

Thorp LE, Wimmer MA, Foucher KC, Sumner DR, Shakoor N, Block JA. The biomechanical effects of focused muscle training on medial knee loads in OA of the knee: a pilot, proof of concept study. *J Musculoskelet Neuronal Interact.* 2010;10(2):166-173.

Wimmer MA, Fischer A, Büscher R, Pourzal R, Sprecher C, Hauert R, Jacobs JJ. Wear mechanisms in metal-on-metal bearings: the importance of tribochemical reaction layers. *J Orthop Res.* 2010;28(4):436-443.

□ **Wysocki, Robert W.**

Jupiter JB, Fernandez DL, Levin LS, Wysocki RW. Reconstruction of posttraumatic disorders of the forearm. *Instr Course Lect.* 2010;59:283-293.

Wysocki RW, Cohen MS, Shott S, Fernandez JJ. Thumb carpometacarpal suspension arthroplasty using interference screw fixation: surgical technique and clinical results. *J Hand Surg Am.* 2010;35(6):913-920.

Wysocki RW, Cohen MS. Complications of limited and total wrist arthrodesis. *Hand Clin.* 2010;26(2):221-228. ■

□ **Howard S. An, MD**

Linkage Analysis, GenMapping and Genome-Wide Analysis of Degenerative Disk Disease

Outcome of Biactive Foam Graft With Autogenous Bone Marrow Aspirate

2009-2010 Clinical Spine Fellowship Program

□ **Gunnar B. J. Andersson, MD, PhD**

Program Project Grant

□ **Charles A. Bush-Joseph, MD**

Clinical Evaluation Balloon Distraction in Hip Arthroscopy

□ **Brian J. Cole, MD, MBA**

Arthroscopic Partial Meniscectomy in Osteoarthritis

Femoral Condyle Resurfacing Prosthesis

Labral Bumper for Treatment of Shoulder Instability

Post Market Study of Articular Cartilage Defects of the Knee

□ **Craig J. Della Valle, MD**

Postoperative Analgesia in Subjects for Total Knee Arthroplasty

□ **Tibor T. Glant, MD**

Mapping of Arthritis Susceptibility Genes

□ **Nadim J. Hallab, PhD**

Biocompatibility Assessment of Particles In Vitro

□ **Joshua J. Jacobs, MD**

Biotribological Layers in Metal-on-Metal Hip Replacement

Cartilage-Friendly Materials

84 Mo Serum Metal Ion Analysis of PRESTIGE Cervical Disk

48 Mo Serum Metal Ion Analysis of the PRESTIGE LP Cervical Disk

Fretting Corrosion Testing of Modular Acetabular Components

Serum Metal Ion Analysis of MAVERICK Total Disk Replacement

Serum Metal Ion Analysis of the A-MAV Total Disk Replacement

Systemic Implications of Total Joint Replacement

Wearing Determination of Orthopedic Polyethylene Materials Using a Tracer

□ **Brett Levine, MD**

Regenerex Tibial Tray Multicenter Data Collection

□ **Hannah J. Lundberg, PhD**

Calculation of Total Joint Replacement Contact Forces During Walking

□ **Shane J. Nho, MD, MS**

Biomechanical Analysis of Gluteus Medius Repairs in a Cadaveric Hip Model

□ **Gregory P. Nicholson, MD**

Assess Rotator Cuff Repair Using Conexia Graft Reinforcement

□ **Markus A. Wimmer, PhD**

Reducing the Emission of Wear Debris in Metal-on-Metal Hip Joints

□ **YeJia Zhang, MD, PhD**

Cell Therapy for Degenerating Intervertebral Disks ■

ABOUT RUSH UNIVERSITY MEDICAL CENTER

Rush is a not-for-profit health care, education, and research enterprise located on the west side of Chicago. Rush encompasses the academic medical center Rush University Medical Center; Rush Oak Park Hospital; Rush University; and Rush Health, a clinically integrated network of providers covering the full spectrum of patient care.

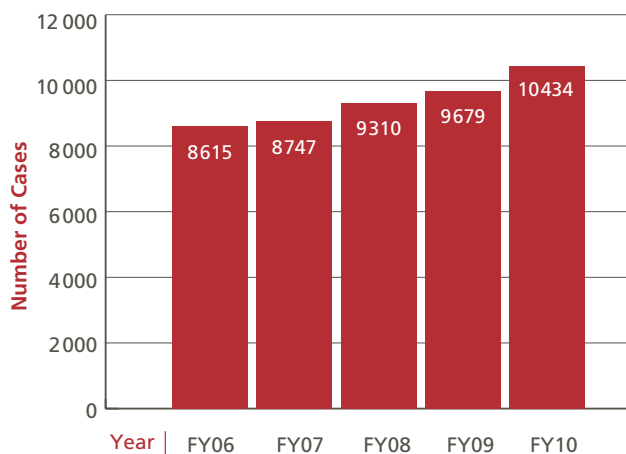
QUALITY RECOGNITION

- The orthopedics program at Rush is consistently ranked among the best in the nation by *U.S. News & World Report*. It was ranked No. 8 in 2011.
- Rush’s nurses have been awarded Magnet status—the highest honor a hospital can receive for outstanding achievement in nursing services—3 times. Rush was the first medical center in Illinois caring for adults and children to receive this prestigious designation, and the first in Illinois to earn a third 4-year designation.
- Rush was named among the top hospitals in the country for quality, safety, and efficiency by the Leapfrog Group,

a national organization that promotes health care safety and quality improvement. Rush is one of only 65 hospitals that made the list of top hospitals for 2010 from among nearly 2000 hospitals surveyed.

- University HealthSystem Consortium has awarded Rush the highest possible score for “equity of care” in each of the 6 years of its annual quality and accountability study. This ranking measures whether patients receive the same quality of treatment and have the same outcomes regardless of their gender, race, or socioeconomic status.
- The orthopedics program at Rush had the second-lowest readmission rate (3.29%) in the country compared to the orthopedics programs of other hospitals rated among the top 50 by *U.S. News & World Report* in 2010.*
- Also in 2010, the orthopedics program at Rush had the third-lowest mortality index (.51) among orthopedics programs from *U.S. News’* top 50 hospitals. For patients of orthopedic surgeons at Rush, the mortality rate was 49% less than expected by UHC risk adjustment algorithms.* ■

Total Orthopedic Surgical Cases**

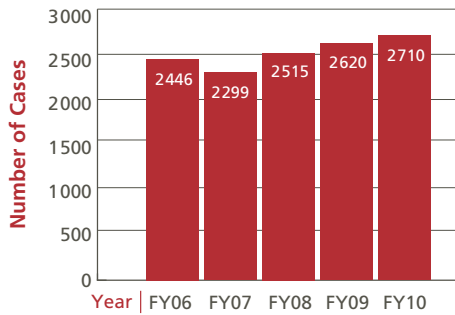


*Source: University HealthSystem Consortium (2010). Rush metrics include attending physicians within the Department of Orthopedic Surgery at Rush, while metrics for the comparative groups utilize the UHC orthopedic service line definition.

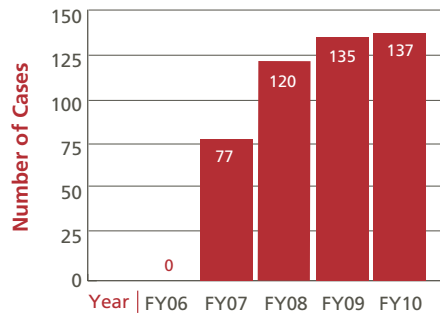
**Volumes include surgeries performed at Rush University Medical Center, Rush Oak Park Hospital, and the outpatient Rush SurgiCenter for each fiscal year, covering July 1 to June 30.

ORTHOPEDIC SUBSPECIALTY SURGICAL CASES**

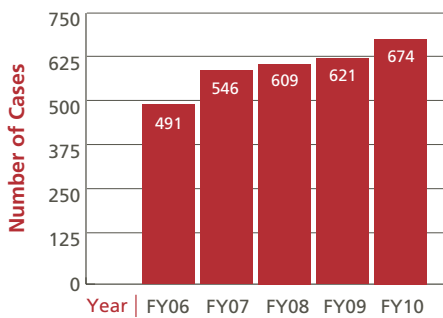
Adult Reconstruction Volumes



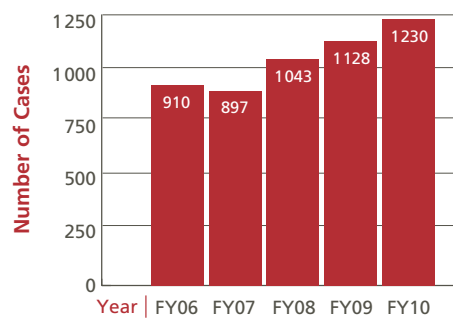
Pediatrics Volumes



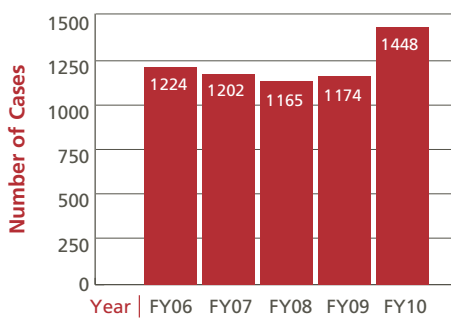
Foot and Ankle Surgery Volumes



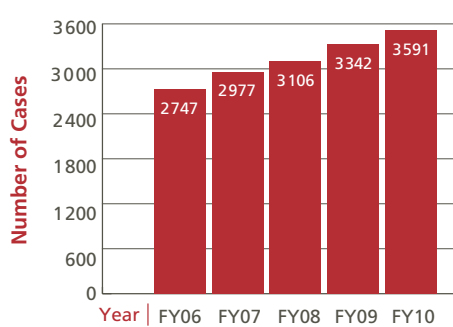
Spine Surgery Volumes



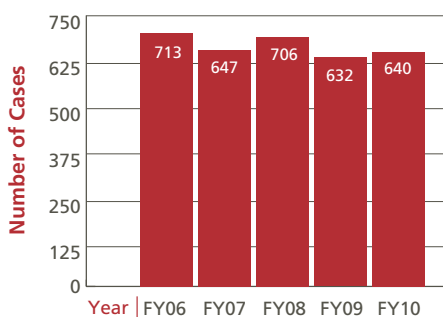
Hand, Wrist, and Elbow Volumes



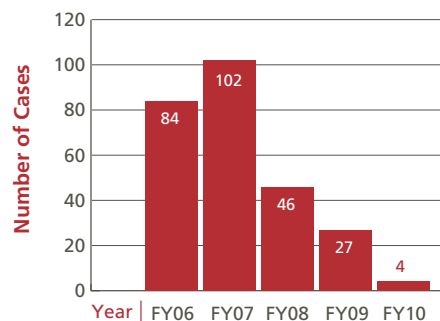
Sports Medicine Volumes



Joint/Orthopedic Oncology & Trauma Volumes



Other Volumes



Legacy of Excellence

AN INTERVIEW WITH RENOWNED SPINE SURGEON
GUNNAR B. J. ANDERSSON, MD, PHD, BY CHRISTOPHER DEWALD, MD

When Gunnar B. J. Andersson, MD, PhD, moved to the United States from his native Sweden in 1985, he already had a stellar reputation for his clinical and research endeavors. But even so, he could not have foreseen the phenomenal success he would enjoy at Rush as a clinician, a researcher, an educator, and a leader. He served as chairman of the Department of Orthopedic Surgery for 14 years before stepping down in 2008, and he holds the Ronald L. DeWald, MD, Endowed Chair in Spinal Deformities. His lab's research on intervertebral disk degeneration, which has broken new ground in the search for answers to low back pain, was honored with the 2011 Kappa Delta Elizabeth Winston Lanier Award from the American Academy of Orthopaedic Surgeons (AAOS). This coveted award was the culmination of 15-plus years spent characterizing disk degeneration and studying therapeutic options to reverse the degenerative process.

Christopher DeWald, MD, whose father established the endowed chair held by Andersson, is one of the many spine surgeons at Rush whom Andersson has mentored through the years. The two recently sat down to talk about Andersson's life—and his lasting contributions to spine care and research.

DeWald: What inspired you to become an orthopedic surgeon?

Andersson: I knew early on that I wanted to be a surgeon, but I wasn't sure which subspecialty I preferred. I was inspired by some of my professors at the University of Gothenburg in Sweden, and also by the fact that there is mechanical theory behind what spine surgeons do, which I've always liked. One of my professors was internationally famous; he was well known as one of the fathers of biomechanics—applying mechanical engineering principles to the body. This appealed to me because I was interested in the engineering aspects of the profession.

DeWald: Was your medical school similar to the medical schools in the United States?

Andersson: It was different because in Europe you don't have the college system, so you went to medical school and spent 6 and a half years in medical school. During the first 2 years you do a lot of the stuff that in America students do in college. Then you enter into the clinical area and, as in the United States, you rotate to different specialties. I did a 1-month rotation in orthopedic surgery, and I thought it was a great subspecialty. I always thought medicine was fascinating in that you don't have to make choices about your area of focus when you start medical school; you have to make choices when you finish medical school.

DeWald: At the time you completed your training, there weren't fellowships like there are now. How did you decide that spine was your calling?

Andersson: I think others decided that for me in a way, because I was initially really not interested in the clinical care of patients with back pain. I was interested in deformity, but I was more interested in joint replacement surgery and in trauma and fracture care. However, my research was primarily in spine, and people kept sending me patients with back problems because they identified me with the spine, and I got more and more interested in that area. Eventually it was too difficult to juggle all these subspecialties, so I had to make a decision. At that time I had been devoting so much time to spine that it was very easy to make a decision. I have never regretted it.

DeWald: What was the focus of your research in Sweden?

Andersson: A lot of the research I did was related to back pain in industry, and ways of reducing the impact of work on the back. You could call it occupational orthopedics or occupational

**CHRISTOPHER DEWALD, MD, WHOSE FATHER ESTABLISHED THE ENDOWED CHAIR
HELD BY ANDERSSON, IS ONE OF THE MANY SPINE SURGEONS AT RUSH
WHOM ANDERSSON HAS MENTORED THROUGH THE YEARS.**



Gunnar B. J. Andersson, MD,
PhD (right), and Christopher
DeWald, MD

biomechanics. At that time it was not a particularly popular subject in the United States. Everybody knew there were a lot of worker's compensation injuries, but there were not a lot of orthopedic surgeons who were interested in trying to do something from a prevention point of view or in addressing the problems more specifically. That has clearly changed. Now people are much more cognizant about work-related orthopedic problems.

DeWald: I've heard you also had something to do with developing the seats in Volvos.

Andersson: I did. It started because Volvo was looking at the seat design they had, and they wanted some input. And at that time I had just started my research career and was interested in looking at sitting—not just from a car seat perspective but in other ways as well. My research team started working on ways of measuring loads on the spine when you sit, and we adapted that research to Volvo's interest in figuring out what types of supports chairs should have in order to be as comfortable and as physiologically well designed as possible. In the process I got connected with the research engineers at Volvo and with the interior designers, and we started working very closely on developing seats. That collaboration actually continued for about 15 years. It was a very nice collaboration, and Volvo supported a lot of the research I did during those years.

DeWald: They still use the same car seat design today, don't they?

Andersson: They do. Interestingly, some of the things we felt would enhance the seats—such as lower back support—were things Volvo had thought about removing because they cost money. You know, it's only a few dollars per seat, but if you make millions of seats each year, it adds up to a lot of money.

DeWald: You had quite a successful career in Sweden. What made you decide to make the jump across the pond?

Andersson: That was also chance to some degree. I was actually planning to move within Sweden. In the 1970s and early 1980s, I had been here in the States doing research with Jorge O. Galante, MD, DMSc [the Grainger Director of the Rush Arthritis and Orthopedics Institute and former chairman of the Department of Orthopedic Surgery], and I had people from the States spending time with me in Sweden, primarily on the research side. Around the time I was getting ready to move within Sweden, I visited the United States, and Jorge said, "You know, if you're going to move, you should move to the United States." That's how it started.

I thought the opportunity here was tremendous, and at that time in my life I also thought it would be exciting to move to a new environment and experience new challenges. I figured if it didn't work out, I could always go back to Sweden. I was 42 years old when I moved to the United States—that's fairly late in life—and I had built a career in Sweden. But I thought it would be an interesting challenge to try to build a career in the United States.

DeWald: How was the transition overall for your family from Sweden to the United States?

Andersson: For my wife and myself it was fairly easy, but the kids struggled for a couple of years. However, we had decided from the beginning we were going to be here for three years, whether we liked it or not, and then after three years we would make a decision whether to stay or move. After three years, we had breakfast and my wife and I told the kids that we needed to decide what to do. And the kids looked at us and said, "Well, we don't really care what you guys do, but we're going to stay here." So it became fairly easy. I have never regretted the move. It's been very rewarding personally and professionally.

DeWald: What type of research were you doing with Dr Galante before you moved here?

Andersson: We worked mostly on joint replacements, and also on bone ingrowth into the porous material he had developed, which subsequently became the fixation system for a lot of joint replacement devices. I was here doing primarily research in joint replacement. I did some work on the spine as well with some of the people over at the University of Illinois, Chicago. In subsequent years some of those researchers came over and spent a year with me in Sweden. We continued to work together. So by the time I moved here I had all these friends, and Chicago felt like a home away from home in many ways.

DeWald: You came to Rush in 1985; at what point did you assume the role of department chairman?

Andersson: In 1994, and that was because we made some major changes to the department. The Rush Arthritis and Orthopedics Institute was created, and Dr Galante, who had been department chairman since the department was founded in 1972-1973, decided he would rather be head of the institute than continue to be the department chairman. It was an exciting time because at that time I was also the managing partner of Midwest Orthopaedics at Rush, and we had started growing very rapidly and were recruiting a lot of talented new people. There were tremendous clinical opportunities based on our clinical excellence and the fact that

“MOST OF THE TIME WHAT YOU DO IN RESEARCH IS LAY FOUNDATIONS, YOU LAY BRICKS, AND HOPEFULLY SOMEBODY ELSE WILL LAY THE NEXT BRICK, AND RESEARCH ADVANCES.”

we had been able to marry research and clinical care in a way that was unique to Chicago and, to some degree, unique to the United States at the time.

DeWald: The amount of change that has occurred in the department since 1994 is dramatic. How were you able to grow the department as well as you have with all the different personalities?

Andersson: You have to accept that people are different. You have to take advantage of the fact that many people who have high-strung personalities also are brilliant, and if you give them the opportunity they will put their brilliance to use. You build by recruiting people, and then you give them an opportunity to excel in the areas where they can excel. And you leave them alone; you don't micromanage what they do. Meanwhile, you just keep a direction that moves everything forward.

We've been blessed at Rush. There's not been a single person that I wouldn't have recruited again to this department, and all of the faculty members have shown clinical excellence as well as a devotion to research and education. We've also been extremely lucky in recruiting the right people to our research faculty. They've been successful in getting funding and in enhancing Rush's reputation. Once you have a good reputation, it's easy to recruit more good people.

DeWald: Do you see the department continuing to grow?

Andersson: I do. We've nearly tripled in size since 1994, when we had only 10 or 11 surgeons, and the numbers of publications and research papers and presentations by our faculty have been absolutely phenomenal. Our surgical volume has grown as well; in 1994 we were doing about 3000 cases a year; now we're doing more than 10000 cases. There has been explosive development in many of the subspecialties, and I don't see any reason why that should stop.

One of our limitations, historically, has been space. On the practice side, I started working on consolidation and increasing space in the 1990s, and now we have our own building on campus, and we have space for additional growth.

DeWald: Whose idea was the Orthopedic Building?

Andersson: I believe it was my idea. I started conceptualizing an orthopedic hospital in the early 1990s, shortly after I took over as managing partner of Midwest Orthopaedics at Rush. And by the time Rush started working on the transformation of the campus in the early 2000s, it was obvious that we needed more professional office space for our orthopedic physicians. At that time I pushed the idea that we should have a separate building that we would be able to finance and run on our own. There wasn't a lot of resistance. The institution thought it was a good idea because consolidating our orthopedic practices would open up space in the existing professional office buildings that Rush could use for other purposes. And it also freed up some capital for the institution to spend on the new hospital, which was important for them from a business perspective. So I think it was fairly well accepted from the very beginning.

DeWald: Getting back to your research, you're best known for your work on intervertebral disk degeneration, but obviously that wasn't always your area of interest. What caused you to shift your focus?

Andersson: When I first came to the States, I continued to work on lifting and other activities that are stressful to the back. But one of the areas I've devoted a lot of time to is epidemiology, and it became clear to me that back pain is probably the most common of all the chronic pain conditions, not only in the United States, but in virtually every country in the world. It also became obvious to me that the major cause of back pain is related to disk degeneration and the consequences of disk degeneration. So over the past 15-plus years that's been the primary focus of my research.

As a result of that research, we have characterized disk degeneration at its various stages. We have created animal models to study disk degeneration in detail and have studied a variety of products—genes, growth factors, cells, stem cells—to reverse disk degeneration. And we have come to the point now where 2 of those products are being tested in humans by large implant companies.

DeWald: Your lab received a Kappa Delta Award for this work. Would you say that is your crowning research achievement?

Andersson: I don't know that I can really point to one thing that I'm proudest of. Most of the time what you do in research is lay foundations, you lay bricks, and hopefully somebody else will lay the next brick, and research advances. You look at the areas in which you have made contributions, and you ask whether those contributions have stimulated people to do more in the area. And I think I have. The whole area of clinical research, which I was very interested in initially, has blossomed. The area of occupational biomechanics has grown dramatically. Spine research certainly is at a very different level today than it was when I started. But you go through phases. You go through phases when you contribute a lot, and then you go through phases where you stimulate others to contribute. And when you get to the stage where you look back at your life, it's hard to pick certain things out and say this is where your contributions made a difference, and this is where they didn't.

Of course, the Kappa Delta Award is a huge honor because it's given for a body of research, over a period of time, that has influenced the field. Interestingly, I was an author on Kappa Delta Award papers twice before, and in both cases I had to take my name off because I was still in Sweden, and at the time they would

not allow nonmembers of the AAOS to be on these papers. So this is my one and only Kappa Delta Award, and that's fine. The true awardee is Howard S. An, MD, without whom the progress would not have occurred and who, appropriately, is the first author.

DeWald: What do you think is the future of treatment for disk degeneration?

Andersson: I think biologics will play a larger role than they do today. There's no question that you can reverse disk degeneration in the early stages. But the problem is that in the early stages most people don't have any pain from disk degeneration. And clinically it's not practical to have a method to treat something that isn't causing symptoms. So we need to find ways of affecting disk degeneration at a later stage, a way of stimulating the cells in the disks to produce the normal products that a disk needs to sustain its normal biologic activity. Currently you can do that by injecting chemicals that stimulate the cells, or by injecting cells that produce substances, or by manipulating the genes of the cells. All these methods are currently available and are currently being tested clinically, but they are still primarily in a research stage. In the future they will be clinically useful methods, although I don't think it's going to happen in the next decade. Maybe it will happen in my lifetime. ■