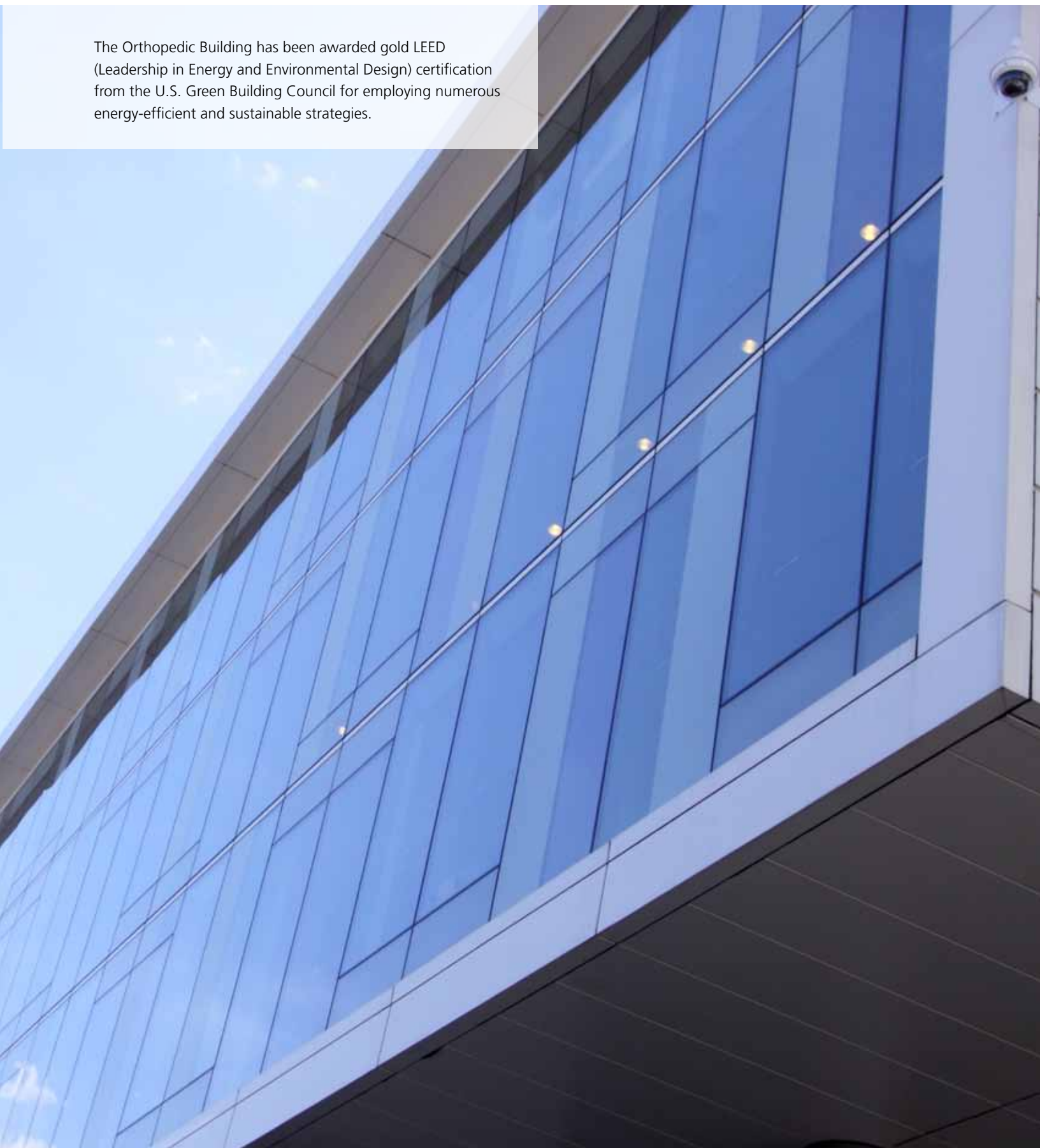


2010 RUSH

# ORTHOPEDICS

JOURNAL

The Orthopedic Building has been awarded gold LEED (Leadership in Energy and Environmental Design) certification from the U.S. Green Building Council for employing numerous energy-efficient and sustainable strategies.



## FACULTY EDITORS

Steven Gitelis, MD  
*Editor in Chief*

Bernard R. Bach Jr, MD

Frank M. Phillips, MD



## 2 CHAIRMAN'S LETTER

## 4 DEPARTMENT OF ORTHOPEDIC SURGERY FACULTY AND FELLOWS

## 8 RESEARCH FACULTY

## 9 RESIDENTS

### ARTICLES

- 10 **Rotator Cuff Repair: Strategies for Maximizing Patient Outcomes** James S. Kercher, MD; Michael J. Salata, MD; Sarvottam Bajaj, BE; Eric J. Strauss, MD; Nikhil N. Verma, MD; Anthony A. Romeo, MD; Brian J. Cole, MD, MBA
- 17 **Cervical Disk Replacement: Is There a Motion-Sparing Alternative to Anterior Cervical Decompression and Fusion?** Brian R. Braaksmma, MD; Frank M. Phillips, MD
- 23 **Perioperative Oral Pregabalin Reduces Chronic Pain After Total Knee Arthroplasty: A Prospective, Randomized, Controlled Trial** Asokumar Buvanendran, MD; Jeffrey S. Kroin, PhD; Craig J. Della Valle, MD; Maruti Kari, MD; Mario Moric, MS; Kenneth J. Tuman, MD
- 33 **The Expected Value of Hip Resurfacing Arthroplasty Versus Total Hip Arthroplasty for 50-Year-Old Patients With Osteoarthritis of the Hip** W. Randall Schultz, MD, MS; James D. Slover, MD, MS; Scott Sporer, MD, MS
- 41 **Wear Mechanisms in Metal-on-Metal Bearings: The Importance of Tribochemical Reaction Layers** Markus A. Wimmer, PhD; Alfons Fischer, PhD; Robin Büscher, PhD; Robin Pourzal, MS; Christoph Sprecher, MS; Roland Hauert, PhD; Joshua J. Jacobs, MD
- 50 **Giant Cell Tumor of the Tibial Tuberosity With Involvement of the Patellar Ligament: A Case Report** Cara Cipriano, MD; Alan Blank, MS; Ira J. Miller, MD, PhD; Steven Gitelis, MD

### ABSTRACTS

- 54 **Pediatric Patella Realignment Surgery: Do Postoperative Radiographic Measurements Correlate With Clinical Outcome?** Aimee Brasher, MD; Jeffrey Ackman, MD
- 56 **Runx2 Regulation of *Col10a1* Expression During Chondrocyte Maturation Impacts Bone Formation and Joint Maintenance** Ming Ding, PhD, DDS; Sam

Abbassi, BS; Jun Li, MD; Yaojuan Lu, MD, MS; Valérie Geoffroy, PhD; Feifei Li, MD; Anna Plaas, PhD; Qiping Zheng, PhD

- 58 **Normalization of Glenohumeral Articular Contact Pressures After Either Latarjet or Iliac Crest Bone Grafting Procedure: Impact of Graft Type, Position, and Coracoid Orientation** Neil Ghodadra, MD; Jordan Goldstein, MD; Aman Gupta, BS; Elizabeth Shewman, PhD; Nikhil N. Verma, MD; Bernard R. Bach Jr, MD; Anthony A. Romeo, MD; Matthew T. Provencher, MD
- 60 **Early Results of a Bipolar Radial Head Implant: A Multicenter Study** Robert R. L. Gray, MD; Mark Zunkiewicz, MD; Robert W. Wysocki, MD; Mark S. Cohen, MD; Mark E. Baratz, MD
- 62 **Early Results of a Porous Tantalum Primary Femoral Hip Prosthesis** Brett Levine, MD
- 64 **Characterization of the Hypertrophic Chondrocyte-Specific *Col10a1* Cis-Enhancer Both In Vitro and In Vivo** Feifei Li, MD; Yaojuan Lu, MD, MS; Sam Abbassi, BS; Ming Ding, PhD, DDS; Yuqing Chen, MS; Siying Wang, PhD, MD; Brendan Lee, PhD, MD; Qiping Zheng, PhD
- 66 **Does Multilevel Lumbar Stenosis Lead to Poorer Outcomes? A Subanalysis of the Spine Patient Outcomes Research Trial (SPORT) Lumbar Stenosis Study** Daniel K. Park, MD; Howard S. An, MD; Jon D. Lurie, MD, MS; Wenyan Zhao, MS; Anna Tosteson, ScD; Tor D. Tosteson, ScD; Harry Herkowitz, MD; Thomas Errico, MD; James N. Weinstein, DO, MS
- 68 **Thumb Carpometacarpal Suspension Arthroplasty Using Interference Screw Fixation: Surgical Technique and Clinical Results** Robert W. Wysocki, MD; Mark S. Cohen, MD; John J. Fernandez, MD

## 70 PUBLICATIONS

## 76 RESEARCH GRANTS

## 78 VOLUME AND QUALITY DATA

## 80 LIFETIME ACHIEVEMENT

An Interview With Joint Replacement Pioneer Jorge O. Galante, MD, DMSc, by Craig J. Della Valle, MD

This is an abbreviated issue of the *Rush Orthopedics Journal*. For the complete version, which contains additional articles, please visit the Rush Web site at [www.rush.edu/orthopedicsjournal](http://www.rush.edu/orthopedicsjournal).

This issue of the *Rush Orthopedics Journal* highlights what has been a truly eventful and historic year for the Department of Orthopedic Surgery at Rush University Medical Center—starting with the move of our physicians, researchers, and staff into the newly constructed, state-of-the-art Orthopedic Building in November 2009.


Already the transition is paying huge dividends. Consolidating our clinical, research, and educational components into one facility has helped to streamline patient care, promote greater intradepartmental collaboration, and make our day-to-day operations more efficient. This new ambulatory building also enhances patient access to the complementary medical disciplines that are key to an orthopedic patient's success, such as rheumatology. It has long been our goal to provide the best comprehensive, multidisciplinary patient care in one location, and it's gratifying to see that vision now being realized.

In the midst of this momentous move, our physicians and researchers continued to break new ground in orthopedic care and research. These contributions are evidenced by numerous peer-reviewed publications, as well as several national research awards and societal leadership positions. Among the most notable honors, former Department Chairman Jorge O. Galante, MD, DMSc, received the Lifetime Achievement Award from the Hip Society (see page 80 for an interview with Galante about the advent and evolution of cementless fixation); Craig J. Della Valle, MD, was the recipient of two prestigious research awards from the Knee Society (Coventry and Ranawat awards) as well as the 2009 Clinical Research Award from the American Association of Hip and Knee Surgeons; Robert W. Wysocki, MD, received the 2009 Best Paper Award from the American Society for Surgery of the Hand; Howard S. An, MD, is serving as president of the International Society for the Study of the Lumbar Spine; Frank M. Phillips, MD, is serving as president of the Society of Minimally Invasive Spine Surgery; and I am currently president of the United States Bone and Joint Decade, which held its most recent Board of Directors meeting in our new Orthopedic Building.

In addition, researchers in the Department of Orthopedic Surgery were the recipients of approximately 3 million dollars in new research funding from the National Institutes of Health for projects that include the study of the molecular biology of inflammatory arthritis (Tibor T. Glant, MD, PhD); the mechanisms of intervertebral disk disease (Gunnar B. J. Andersson, MD, PhD); the tribology of metal-on-metal bearings in total hip replacement (Joshua J. Jacobs, MD, and Markus A. Wimmer, PhD); and the mechanical properties of tissue-engineered cartilage (Vincent M. Wang, PhD).

Our commitment to excellence can also be seen in our highly competitive residency and fellowship programs. We are extremely proud to be training highly skilled orthopedic specialists who will help advance orthopedic care for generations to come.

I invite you to peruse this issue of the *Rush Orthopedics Journal* and enjoy a sampling of the outstanding work produced by our department during the past year.



Joshua J. Jacobs, MD  
The William A. Hark, MD/Susanne G. Swift Professor of Orthopedic Surgery  
Chairman, Department of Orthopedic Surgery  
Rush University Medical Center

Joshua J. Jacobs, MD (right), and Kharma C. Foucher, MD, PhD, co-director of the Motion Analysis Laboratory.



“Consolidating our clinical, research, and educational components into one facility has helped to streamline patient care, promote greater intradepartmental collaboration, and make our day-to-day operations more efficient.”

## ADULT RECONSTRUCTIVE SURGERY



**Aaron Rosenberg, MD**  
Director, Section of Adult Reconstruction  
Professor, Department of Orthopedic Surgery



**Richard A. Berger, MD**  
Assistant professor, Department of Orthopedic Surgery



**Craig J. Della Valle, MD**  
Associate professor, Department of Orthopedic Surgery  
Director, Adult Reconstructive Orthopedic Surgery Fellowship Program



**Jorge O. Galante, MD, DMSc**  
The Grainger Directorship of the Rush Arthritis and Orthopedics Institute  
Professor, Department of Orthopedic Surgery



**Joshua J. Jacobs, MD**  
The William A. Hark, MD/ Susanne G. Swift Chair of Orthopedic Surgery  
Chairman and professor, Department of Orthopedic Surgery



**Brett Levine, MD**  
Assistant professor, Department of Orthopedic Surgery



**Wayne Paprosky, MD**  
Professor, Department of Orthopedic Surgery



**Scott Sporer, MD, MS**  
Assistant professor, Department of Orthopedic Surgery

## FELLOWS

**David Fabi, MD**  
Medical school – University of Illinois College of Medicine  
Residency – University of Illinois at Chicago

**Jared Foran, MD**  
Medical school – Johns Hopkins University School of Medicine  
Residency – University of California San Diego

**Matthew Miller, MD**  
Medical school – Boston University School of Medicine  
Residency – Stanford University

**Neil Sheth, MD**  
Medical school – Albany Medical College of Union University  
Residency – Hospital of the University of Pennsylvania

**Venessa Stas, MD**  
Medical school – University of Toronto, Faculty of Medicine  
Residency – University of Toronto Affiliated Hospitals


**Jesse Templeton, MD**  
Medical school – University of Iowa Roy J. and Lucille A. Carver College of Medicine  
Residency – Cleveland Clinic

**Brent Whited, MD**  
Medical school – University of Iowa Roy J. and Lucille A. Carver College of Medicine  
Residency – Vanderbilt University Medical Center

## ELBOW, WRIST, AND HAND SURGERY



**Mark S. Cohen, MD**  
Director, Section of Hand  
Surgery  
Professor, Department of  
Orthopedic Surgery



**John J. Fernandez, MD**  
Assistant professor,  
Department of  
Orthopedic Surgery



**Robert Goldberg, MD**  
Instructor, Department  
of Orthopedic Surgery



**Robert W. Wysocki, MD**  
Assistant professor,  
Department of  
Orthopedic Surgery

---

## FOOT AND ANKLE SURGERY



**George Holmes Jr, MD**  
Director, Section of Foot  
and Ankle Surgery  
Assistant professor,  
Department of  
Orthopedic Surgery



**Simon Lee, MD**  
Assistant professor,  
Department of  
Orthopedic Surgery



**Johnny L. Lin, MD**  
Assistant professor,  
Department of  
Orthopedic Surgery

---

## ONCOLOGY AND TRAUMA



**Steven Gitelis, MD**  
Director, Section of  
Orthopedic Oncology  
Rush Medical College  
Endowed Professor of  
Orthopedic Oncology  
Vice chairman and  
professor, Department of  
Orthopedic Surgery



**Walter W. Virkus, MD**  
Associate professor,  
Department of  
Orthopedic Surgery  
Director, Orthopedic  
Residency Program

---

## PEDIATRIC SURGERY



**Monica Kogan, MD**  
Director, Section of  
Pediatric Surgery  
Assistant professor,  
Department of  
Orthopedic Surgery

6

## SPINE SURGERY



**Howard S. An, MD**  
Director, Division of  
Spine Surgery  
The Morton  
International Chair of  
Orthopedic Surgery  
Professor, Department  
of Orthopedic Surgery  
Director, Spine Surgery  
Fellowship Program



**Gunnar B. J.  
Andersson, MD, PhD**  
The Ronald L. DeWald,  
MD, Endowed Chair in  
Spinal Deformities  
Professor and chairman  
emeritus, Department of  
Orthopedic Surgery



**Christopher DeWald, MD**  
Assistant professor,  
Department of  
Orthopedic Surgery



**David Fardon, MD**  
Associate professor,  
Department of  
Orthopedic Surgery



**Edward J. Goldberg, MD**  
Assistant professor,  
Department of  
Orthopedic Surgery



**Kim W. Hammerberg, MD**  
Assistant professor,  
Department of  
Orthopedic Surgery



**Frank M. Phillips, MD**  
Director, Section of  
Minimally Invasive  
Spine Surgery  
Professor, Department  
of Orthopedic Surgery



**Kern Singh, MD**  
Assistant professor,  
Department of  
Orthopedic Surgery

## FELLOWS

**Mir Ali, MD, PhD**  
Medical school – University of Chicago Pritzker School  
of Medicine  
Residency – Mayo Clinic

**Colin Harris, MD**  
Medical school – New York Medical College  
Residency – University of Medicine and Dentistry of  
New Jersey

**Mohammad Shukairy, MD**  
Medical school – Medical College of Ohio at Toledo  
Residency – Henry Ford Hospital

**Krzysztof Siemionow, MD**  
Medical school – Karol Marcinkowski University  
of Medical Sciences  
Residency – Cleveland Clinic



## SPORTS MEDICINE




**Bernard R. Bach Jr, MD**  
Director, Division of Sports Medicine  
The Claude N. Lambert, MD/Helen S. Thomson Chair of Orthopedic Surgery  
Professor, Department of Orthopedic Surgery  
Director, Sports Medicine Fellowship Program



**Charles Bush-Joseph, MD**  
Professor, Department of Orthopedic Surgery



**Brian J. Cole, MD, MBA**  
Director, Rush Cartilage Restoration Center  
Professor, Department of Orthopedic Surgery



**Shane J. Nho, MD, MS**  
Assistant professor, Department of Orthopedic Surgery



**Gregory Nicholson, MD**  
Associate professor, Department of Orthopedic Surgery



**Anthony A. Romeo, MD**  
Director, Section of Shoulder and Elbow Surgery  
Professor, Department of Orthopedic Surgery



**Nikhil N. Verma, MD**  
Assistant professor, Department of Orthopedic Surgery

## FELLOWS

**Joseph U. Barker, MD**  
Medical school – Duke University School of Medicine  
Residency – Hospital for Special Surgery

**James S. Kercher, MD**  
Medical school – Medical College of Georgia  
Residency – Emory University

**Michael J. Salata, MD**  
Medical school – Case Western Reserve University  
Residency – University of Michigan Hospitals

**Eric J. Strauss, MD**  
Medical school – Weill Cornell Medical College  
Residency – NYU Hospital for Joint Diseases

**RESEARCH FACULTY**

**Alejandro A. Espinoza Orias, PhD**

**Instructor**

Areas of focus – Spine and bone biomechanics

**Alfons Fischer, PhD**

**Visiting professor**

Areas of focus - Tribology and metallurgy

**Kharma C. Foucher, MD, PhD**

**Assistant professor**

Area of focus – Gait biomechanics

**Tibor T. Glant, MD, PhD**

**The Jorge O. Galante, MD, DMSc,**

**Chair in Orthopaedic Surgery**

**Professor**

Areas of focus – Animal models of rheumatoid arthritis; genetics of autoimmune arthritis; transgenic mouse models of autoimmune arthritis; animal model of myelodysplasia; expression and function of hyaluronan-binding proteins

**Deborah J. Hall**

**Instructor**

Areas of focus – Implant and tissue retrieval studies; pathology; histology

**Nadim J. Hallab, PhD**

**Associate professor**

Areas of focus – Immunological reactions to orthopedic implants; biomaterials; mechanical testing

**Nozomu Inoue, MD, PhD**

**Professor**

Areas of focus – Intervertebral disk degeneration and regeneration

**Hannah J. Lundberg, PhD**

**Instructor**

Areas of focus – Musculoskeletal modeling; implant biomechanics

**Carl Maki, PhD**

**Associate professor**

Area of focus – Orthopedic cancer biology

**Katalin Mikecz, MD, PhD**

**Professor**

Areas of focus – Animal models of rheumatoid arthritis; leukocyte migration; in vivo imaging/multiphoton microscopy

**Raghu N. Natarajan, PhD**

**Professor**

Area of focus – Spine biomechanics

**Tibor A. Rauch, PhD**

**Associate professor**

Area of focus – Epigenetics associated with autoimmune diseases and joint replacement

**Anastasia Skipor, MS**

**Instructor**

Areas of focus – Trace metal analysis; metal-on-metal surface arthroplasty

**Thomas M. Turner, DVM**

**Assistant professor**

Areas of focus – Animal models in orthopedic surgery; cartilage damage and repair; joint replacement fixation

**Robert M. Urban**

**Associate professor**

Areas of focus – Implant and tissue retrieval studies; pathology; histology

**Vincent M. Wang, PhD**

**Assistant professor**

Areas of focus – Ligament and tendon biomechanics, healing, and repair

**Markus A. Wimmer, PhD**

**Associate professor**

Areas of focus – Cartilage repair; wear testing; gait biomechanics

**YeJia Zhang, MD, PhD**

**Assistant professor**

Area of focus – Intervertebral disk degeneration

**Qiping Zheng, PhD**

**Assistant professor**

Area of focus – Orthopedic cancer biology

## RESIDENTS

2010 RUSH ORTHOPEDICS JOURNAL

### DEPARTMENT OF ORTHOPEDIC SURGERY RESIDENTS

CLASS OF 2010

#### Christopher Bayne, MD

Medical school – Harvard Medical School

#### Sanjeev Bhatia, MD

Medical school – Northwestern University Feinberg School of Medicine

#### Debdut Biswas, MD

Medical school – Yale University School of Medicine

#### Brian R. Braaksma, MD

Medical school – Columbia University College of Physicians and Surgeons

#### Aimee Brasher, MD

Medical school – Rush Medical College

#### Cara A. Cipriano, MD

Medical school – University of Pennsylvania School of Medicine

#### Michael Ellman, MD

Medical school – University of Michigan Medical School

#### Amir-Kianoosh Fallahi, MD

Medical school – Wayne State University School of Medicine

#### Nickolas G. Garbis, MD

Medical school – University of Illinois at Chicago College of Medicine

#### Neil Ghodadra, MD

Medical school – Duke University School of Medicine

#### Robert R. L. Gray, MD

Medical school – Warren Alpert Medical School of Brown University

#### James Gregory, MD

Medical school – University of Pennsylvania School of Medicine

#### Christopher Gross, MD

Medical school – Harvard Medical School

#### Andrew Hsu, MD

Medical school – Stanford University School of Medicine

#### Richard W. Kang, MD

Medical school – Rush Medical College

#### Brett Lenart, MD

Medical school – Weill Cornell Medical College

#### Paul B. Lewis, MD

Medical school – Rush Medical College

#### Sameer J. Lodha, MD

Medical school – Washington University School of Medicine

#### Samuel A. McArthur, MD

Medical school – Uniformed Services University Hébert School of Medicine

#### Daniel K. Park, MD

Medical school – Duke University School of Medicine

#### Kevin Park, MD

Medical school – Tulane University School of Medicine

#### Sanjai K. Shukla, MD

Medical school – Duke University School of Medicine

#### Geoffrey S. Van Thiel, MD

Medical school – University of California Los Angeles Geffen School of Medicine

#### Adam Yanke, MD

Medical school – Rush Medical College

## ROTATOR CUFF REPAIR STRATEGIES FOR MAXIMIZING PATIENT OUTCOMES

James S. Kercher, MD;  
Michael J. Salata, MD;  
Sarvottam Bajaj, BE;  
Eric J. Strauss, MD; Nikhil  
N. Verma, MD; Anthony  
A. Romeo, MD; Brian J.  
Cole, MD, MBA

Author Affiliations: Department of Orthopedic Surgery, Division of Sports Medicine, Rush University Medical Center, Chicago, Illinois.

Corresponding Author: Brian J. Cole, MD, MBA, Rush University Medical Center, 1611 W Harrison St, Suite 300, Chicago, IL 60612 (bcole@rushortho.com).

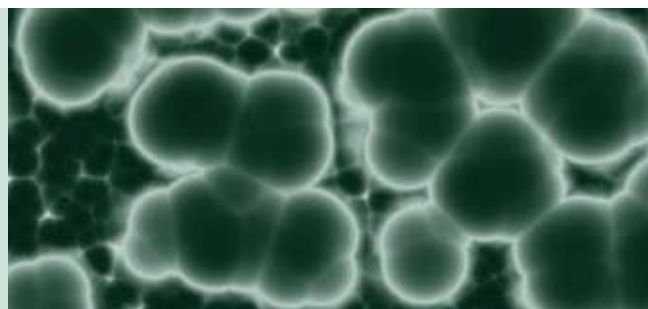
### Introduction

Injury to the rotator cuff results in a structural defect, but more important, it initiates a cascade of alterations involving atrophy, infiltration, retraction, fibrosis, and decreased collagen expression<sup>1-3</sup> that further compromises the muscle-tendon unit. Outcomes following rotator cuff repair vary widely in the literature and are dependent on factors such as age,<sup>4-7</sup> tear size,<sup>4,5,7,8</sup> muscle atrophy,<sup>9</sup> and chronicity.<sup>1</sup> Despite improved understanding of rotator cuff pathology and improved surgical repair techniques and instrumentation, as many as 1 out of every 4 rotator cuff repairs may go on to failure.<sup>4</sup>

Anatomic failure following rotator cuff repair is generally reported to occur in 20% to 40% of primary repairs, although higher rates of failure are reported in some studies.<sup>4,5,6,10-12</sup> Interestingly, initial reports following rotator cuff repair demonstrated that irrespective of retears, patients maintained high satisfaction ratings following repair primarily due to relief of preoperative pain.<sup>7,9,11</sup> However, clinical follow-up studies over the past 20 years have consistently demonstrated that healing and anatomic integrity of the rotator cuff repair site correlate with superior outcomes, particularly with regard to function and strength recovery.<sup>4-7,10,13</sup> This knowledge has encouraged orthopedic surgeons to place more emphasis on surgically improving anatomic integrity and potentially reducing anatomic failure rates in rotator cuff surgery.

Reduced material properties and altered collagen distribution within the rotator cuff tendon following tearing have significant effects on tissue characteristics including the capacity to heal and may be one of the key factors behind anatomic failure.<sup>1,3,4,14,15</sup> Furthermore, previous data have shown that vascularity of the rotator cuff deteriorates with age, likely contributing to poor healing capacity.<sup>16</sup> The inability to achieve consistent tendon healing has fueled the investigation of a variety of strategies to improve initial repair strength, promote tissue in-growth, and ensure long-term repair integrity to sustain the physiologic demands. Advanced techniques such as double-row suture configuration restore the insertion site anatomy and footprint contact area while minimizing gap formation, and in doing so may provide the optimal environment for tendon healing.<sup>17-21</sup> Augmentation strategies include the use of biologic and synthetic patches that attempt to provide strength and scaffolding for rotator cuff tendon repair, although these procedures remain investigational. The addition of platelet-rich plasma (PRP) at the repair site has been hypothesized to accelerate healing.<sup>22-26</sup> The addition of PRP is safe and convenient since it is acquired while the patient is prepared for surgery and then added at the completion of the surgical repair of the tendon; however, the efficacy of the procedure is unknown.

“The inability to achieve consistent tendon healing has fueled the investigation of a variety of strategies to improve initial repair strength, promote tissue in-growth, and ensure long-term repair integrity to sustain the physiologic demands.”



### Double-Row Repairs

Existing constructs for arthroscopic rotator cuff fixation include single-row, double-row, and most recently transosseous-equivalent double-row repairs (Figure 1). The optimal fixation method is an important topic for debate as repair technique is implicated as a source of failure.<sup>27-29</sup> Many studies have demonstrated that double-row configurations, which involve the placement of medial and lateral anchors, significantly increase the amount of native footprint covered with the repaired tendon.<sup>19,30,31</sup> Double-row repairs have also been found to be stronger, exhibit less gap formation, and significantly improve resistance to cyclic displacement when compared to single-row repairs.<sup>17,18,32-35</sup> At our institution, a biomechanical cadaveric study comparing work, maximum load, and stiffness of medial versus lateral sutures demonstrated significantly higher outcomes of sutures placed medially through a torn supraspinatus tendon. In addition, Wall et al<sup>36</sup> reviewed all available biomechanical literature comparing single-row to double-row constructs and identified 15 studies examining biomechanical properties of single-row repair versus double-row repair that met the criteria of directly comparing the two techniques in animal and human models. Nine studies demonstrated a statistically significant advantage to double-row repair with regard to biomechanical strength, failure, and

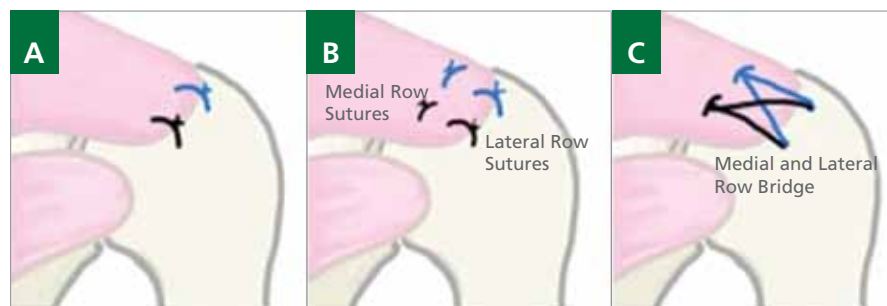
gap formation. Furthermore, 5 of the studies demonstrated that double-row repair was superior to single-row repairs with respect to restoring anatomy.<sup>36</sup> However, more advanced single-row techniques such as adding a medial suture to the repair, the so-called rip-stop suture, compare favorably with strength of fixation using double-row repair but do not reconstitute the same area of tendon-bone healing. Cyclic loading of rotator cuff constructs generally show superior properties for double-row and transosseous repairs over single-row repairs.<sup>37</sup>

When discussing double-row repairs it is important to differentiate the first-generation technique from newer constructs that include bridging sutures between the medial and lateral rows, known as a suture-bridge configuration or transosseous-equivalent (TOE) repair (Figure 2).<sup>20,21,38</sup> First-generation double-row repair constructs consist of a medial row of mattress sutures with simple sutures placed at the lateral edge of the cuff without linkage between the two rows.<sup>39</sup> While this configuration has been shown to outperform the single-row suture anchor techniques,<sup>17,40</sup> biomechanical testing has demonstrated that first-generation double-row configurations fail to prevent repair site gapping during humeral rotation.<sup>32</sup>

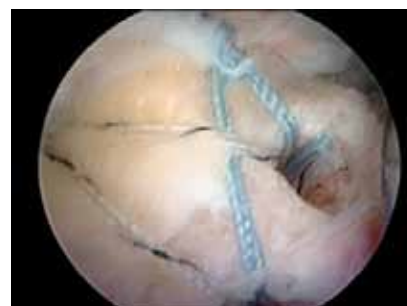Early data on the suture-bridge technique are beginning to show promise. Bisson and Manohar<sup>41</sup> compared open transosseous repair, considered the gold standard, to the suture-bridge

**Figure 1.** Rotator cuff repair. **A**, Single-row. **B**, First-generation double-row. **C**, Transosseous-equivalent.

**Figure 2.** Intraoperative scope image of a completed transosseous-equivalent repair.



**Figure 1**



**Figure 2**

technique for supraspinatus tears in paired cadaveric shoulder specimens. They found no significant difference between the two techniques with respect to elongation, load to failure, and stiffness. Furthermore, these repair methods demonstrated failure loads of approximately 400 to 450 N, approximately half the strength of an intact supraspinatus tendon but higher than that of previously reported repair strengths.<sup>17-19,37,42,43</sup> Biomechanical testing emphasizing internal and external rotation during high loading conditions showed that the linked double-row construct was superior due to self-reinforcing properties resembling those of a Chinese finger trap.<sup>44</sup>

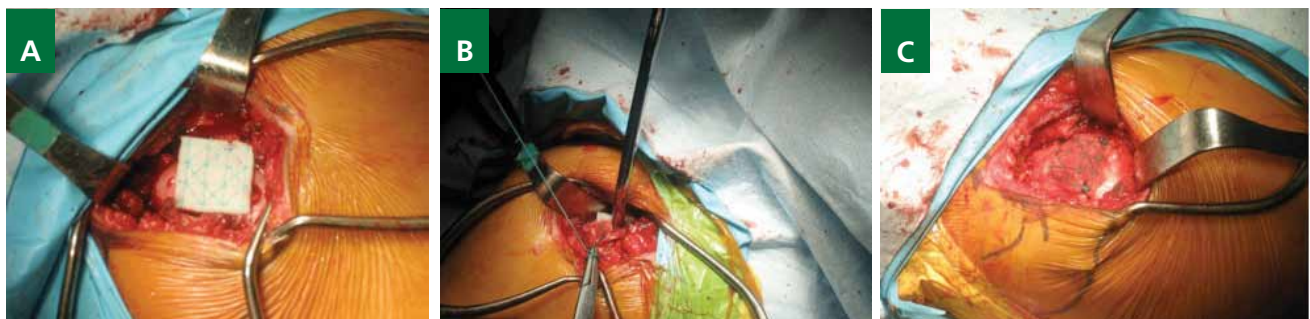Despite the compelling biomechanical data, few studies have reported a difference in clinical outcomes between single-row and double-row techniques. Franceschi et al<sup>45</sup> performed a randomized controlled trial comparing single-row and double-row fixation, and although they reported that double-row repair produced a mechanically superior construct, they found no significant difference in postoperative clinical scores or range of motion between the two groups at 2-year follow-up.<sup>45</sup> However, this study suffered from a beta error and lacked sufficient sample size to show any significant difference; furthermore, it utilized the first-generation double-row repair technique. Similarly, Burks et al<sup>46</sup> reported no clinical differences between patients whose tendons were repaired with a single-row or double-row technique. This study was also underpowered, comparing only 20 patients in each group; additionally, the authors used a nonstandard “triangular” repair configuration with 1 medial anchor and 2 lateral anchors. Although these studies represent the highest level of evidence available, statistical issues related to insufficient power make their findings difficult to extrapolate.

To date, prospective clinical series have suggested that maintaining rotator cuff repair integrity and achieving tendon healing occurs more frequently in patients who have had double-

row rotator cuff repairs as compared to historical controls that reported healing rates after single-row repairs.<sup>12,47,48</sup> Duquin et al<sup>47</sup> performed a systematic review of more than 1100 rotator cuff repairs comparing single-row to double-row constructs. The authors found a statistically significant decrease in anatomic retear rates for true double-row repairs when compared to single-row repairs in all tears greater than 1 cm. Frank et al<sup>48</sup> examined repair site integrity after arthroscopic transosseous-equivalent suture-bridge repairs in 25 patients. Using postoperative magnetic resonance imaging (MRI), they demonstrated intact surgical repair sites in 22 of 25 patients at 1 year. Furthermore, healing was noted in 3 tears that were considered massive. At our institution we have postoperative MRI data from 35 patients demonstrating an 18.5% retear or failure-to-heal rate at an average of 39.6 months after surgery.

Despite the lack of direct comparison of the clinical outcomes of single-row and TOE repairs, it is still possible to draw conclusions from the existing literature. Multiple studies have demonstrated the obvious finding that patients are more satisfied and have improved outcomes when rotator cuff repair integrity is maintained.<sup>5,9,12,49,50</sup> At our institution we have examined outcome scores of 35 patients who underwent double-row repair and reported significant improvement in all subjective scores (Simple Shoulder Test [SST], visual analog scale [VAS], American Shoulder and Elbow Surgeons assessment [ASES], and activities of daily living [ADL]), pain scores, and Constant-Murley scores at an average postoperative time of 3.3 years. In addition, we have examined the strength benefits of TOE constructs and found that patients with TOE repairs demonstrated significantly improved forward flexion and external rotation strength. Given these benefits and following the reasoning that improved outcomes are predicated on healing, surgeons should emphasize repair techniques that provide the most resistance to in vivo forces in an effort to decrease retear rates.

**Figure 3.** Synthetic augmentation patch. **A,** Patch placed over the repair site. **B,** Securing of patch in place using sutures. **C,** Secured patch over the repair site.



## Augmentation Patches

A significant amount of research has been dedicated to investigating the use of augmentation devices that are secured over the repaired rotator cuff. These augmentation devices buffer physiologic demands, improve mechanical properties of the repair, and promote tissue growth at the repair site (Figure 3). These devices can be broadly classified as biologic or synthetic. Naturally occurring extracellular matrix (ECM) scaffolds consist of structural and functional proteins that can stimulate connective tissue growth, deposition, and angiogenesis. These matrices are typically derived from xenogeneic or allogeneic tissue depending on the manufacturer. Human sources include processed human dermal tissue, while xenografts are generally derived from porcine dermis, porcine small intestine submucosa (SIS), or equine pericardium. Advancements in tissue engineering have produced biologically similar synthetic tissue alternatives that demonstrate superior mechanical characteristics compared to biologic soft-tissue augmentation devices.<sup>22,24,51-53</sup>

Although xenogeneic and allogeneic tissue patches are marketed as acellular, these grafts do maintain DNA,<sup>54</sup> which can produce inflammatory reactions in human<sup>55</sup> and animal models.<sup>56-58</sup> Human allogeneic dermal scaffolds have shown better histologic results,<sup>38,56,59</sup> but again these devices are not completely acellular<sup>54</sup> and maintain the potential to incite a host response. Clinical results of ECM grafts used for augmentation have not been promising in short-term studies.<sup>55,57,60,61</sup> Sciamberg et al<sup>60</sup> reported poor results using SIS ECM grafts in 11 consecutive patients for augmentation of rotator cuff tears. Ten of the 11 patients had MRI-documented retears at 6 months postoperatively, and 5 patients had worse postoperative clinical scores. Walton et al<sup>57</sup> similarly reported high rates of tendon retear and declining function on postoperative clinical exams. These results are most likely due to a combination of graft resorption<sup>56,62,63</sup> and reduced biomechanical properties of the ECM devices.<sup>54,64</sup>

Periosteum contains multipotent cells with the capacity to form connective tissue and has been reported to improve tendon-to-bone healing.<sup>65-69</sup> Chang et al<sup>70</sup> investigated the benefits of rotator cuff augmentation with a periosteal patch taken from the proximal tibia in 36 New Zealand white rabbits. The investigators demonstrated significant improvement in maximal load to failure at both 8 and 12 weeks in specimens treated with periosteal augmentation and felt that the cambium layer of the periosteum could serve as a potent interface layer with potential to improve healing and repair strength.<sup>70</sup> Unfortunately, similar results have not translated well to human clinical studies. In a prospective cohort study, Scheibel et al<sup>71</sup> performed augmented open rotator cuff repair on 23 patients (average age, 59.7 years) using a periosteal patch harvested from the proximal humerus. At a mean follow-up of 14.4 months, the

patients demonstrated significant increases in clinical outcome measures. Postoperative MRI, however, showed a 20% failure rate in patients with medium to large rotator cuff tears.

Synthetics such as polyurethane are innocuous polymers and have been used in a variety of soft-tissue applications.<sup>72-76</sup> The biologic response to supraspinatus tendon repairs augmented with a polycarbonate polyurethane patch in Sprague Dawley rats has been examined<sup>72</sup> and demonstrated no inflammatory reaction on histologic sectioning.<sup>72</sup> In an unpublished study, we have recently investigated the use of a reticulated polycarbonate polyurethane patch (Biomerix Corp, Fremont, California) to augment rotator cuff repairs in 10 consecutive patients using an open repair technique. Postoperatively, all patients demonstrated significant improvements in outcome measures as well as range of motion. Furthermore, MRI at 12 months found 90% of patients healed, with 1 persistent tear (I. Encalada-Diaz, MD; B.J.C.; J. D. MacGillivray, MD; et al, unpublished data, 2009-2010).

While no long-term data on the clinical performance of these devices are currently available, the existing research has demonstrated that a polycarbonate polyurethane patch can be safely implanted and may enhance rotator cuff repair longevity and improve patient outcomes. As technology and implantation techniques improve, these findings may offer a rationale for providing a permanent structural scaffold to disperse forces at the tendon-bone interface and promote tissue in-growth, while ultimately improving the natural history of rotator cuff repairs.

## PRP Augmentation

Current knowledge regarding tissue biology highlights the complex interaction of growth factors with regard to tissue structure and reaction to injury. Growth factors (GFs) such as transforming growth factor- $\beta$  (TGF- $\beta$ ), platelet-derived growth factor (PDGF), insulin-like growth factor (IGF), fibroblast growth factor (FGF), and vascular endothelial growth factor (VEGF) are involved in tissue homeostasis<sup>77-79</sup> and play important roles in cell growth, chemotaxis, differentiation, and angiogenesis. Autologous blood products such as platelet-rich plasma (PRP) have been studied extensively in an effort to harness the beneficial effects of these GFs to augment tissue healing. These efforts are based on the ability of platelets to release growth factors from their alpha granules, which play a critical role in mediating tissue healing.<sup>78</sup> In the normal healing process, platelets aggregate at the site of injury and release GFs in response to local stimuli. It is hypothesized that locally administering a platelet concentrate to the injury site may accelerate the healing process.

PRP has received attention in the public media due to its use in high-profile athletes. Platelet-rich plasma is derived from anticoagulated blood that undergoes centrifugation to separate

out the platelet-containing plasma concentrate (Figure 4). Several laboratory and clinical studies have demonstrated the benefits of PRP in acute and chronic orthopedic conditions.<sup>80-84</sup> This treatment adjunct has only recently been applied to rotator cuff repair. Randelli et al<sup>85</sup> administered PRP in combination with an autologous thrombin component in 14 patients following arthroscopic rotator cuff repair. Following a standardized rehabilitation protocol, they found significant increases in functional outcome measures when compared to preoperative status at 6-month, 12-month, and 24-month follow-up intervals; however, repair site integrity was not evaluated postoperatively.<sup>85</sup> Similar improvements were described in a case report by Maniscalco et al<sup>86</sup> after augmentation of an open rotator cuff repair with a PRP-enriched fibrin membrane. Both authors concede that further studies are necessary to evaluate the potential benefits in tendon healing.<sup>85,86</sup>

At our institution we have received IRB approvals and outside funding to begin a randomized, controlled trial to assess the efficacy of PRP in rotator cuff healing and also to pursue an in vitro analysis focusing on cellular and biochemical response following PRP treatment. The clinical trial has been devised to randomize patients with partial-thickness rotator cuff tears (less than or equal to 50% of the tendon) who elect to undergo surgical intervention to be treated with or without the addition of PRP at the time of surgical debridement. The goal of this study is to determine if the addition of PRP is helpful in the healing of these tears. If a positive relationship is noted, the use of this therapy adjunct could potentially be extrapolated to first-line treatment of this pathologic condition and could possibly even be performed in the office setting.

### Conclusion

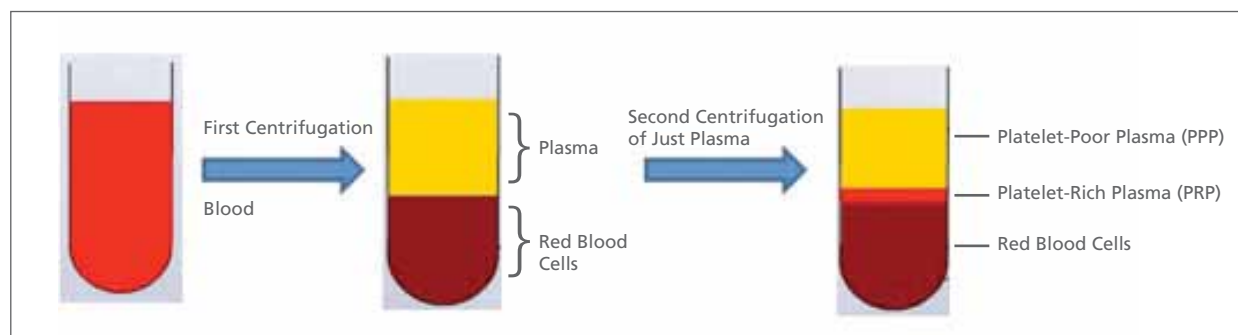
While many advances have been made in rotator cuff repair, room for improvement remains. Recreation of the anatomy

of the rotator cuff insertion (or footprint) does seem to be important in both the healing capacity and clinical outcomes of rotator cuff repair. This has been facilitated with new surgical techniques such as TOE repair. Despite the most advanced current surgical techniques, repair failures do continue to occur. The incidence of repair failures may potentially be decreased by the addition of reparative adjuncts that are currently available and on the horizon. Further research, like the work being done at this institution, is needed to provide optimal outcomes for all patients with rotator cuff injuries.

### References

1. Coleman SH, Fealy S, Ehteshami JR, et al. Chronic rotator cuff injury and repair model in sheep. *J Bone Joint Surg Am.* 2003;85-A(12):2391-2402.
2. Kannus P, Józsa L. Histopathological changes preceding spontaneous rupture of a tendon: a controlled study of 891 patients. *J Bone Joint Surg Am.* 1991;73(10):1507-1525.
3. Thomopoulos S, Hattersley G, Rosen V, et al. The localized expression of extracellular matrix components in healing tendon insertion sites: an in situ hybridization study. *J Orthop Res.* 2002;20(3):454-463.
4. Boileau P, Brassart N, Watkinson DJ, et al. Arthroscopic repair of full-thickness tears of the supraspinatus: does the tendon really heal? *J Bone Joint Surg Am.* 2005;87(6):1229-1240.
5. Cole BJ, McCarty LP III, Kang RW, Alford W, Lewis PB, Hayden JK. Arthroscopic rotator cuff repair: prospective functional outcome and repair integrity at minimum 2-year follow-up. *J Shoulder Elbow Surg.* 2007;16(5):579-585.
6. Flurin PH, Landreau P, Gregory T, et al; and Société Française d'Arthroscopie. Arthroscopic repair of full-thickness cuff tears: a multicentric retrospective study of 576 cases with anatomical assessment [in French]. *Rev Chir Orthop Reparatrice Appar Mot.* 2005;91(S8):31-42.
7. Harryman DT II, Mack LA, Wang KY, Jackins SE, Richardson ML, Matsen FA III. Repairs of the rotator cuff: correlation of functional results with integrity of the cuff. *J Bone Joint Surg Am.* 1991;73(7):982-989.
8. Liu SH, Baker CL. Arthroscopically assisted rotator cuff repair: correlation of functional results with integrity of the cuff. *Arthroscopy.* 1994;10(1):54-60.
9. Galatz LM, Ball CM, Teefey SA, Middleton WD, Yamaguchi K. The outcome and repair integrity of completely arthroscopically repaired large and massive rotator cuff tears. *J Bone Joint Surg Am.* 2004;86-A(2):219-224.
10. DeFranco MJ, Bershady B, Ciccone J, Yum JK, Iannotti JP. Functional outcome of arthroscopic rotator cuff repairs: a correlation of anatomic

**Figure 4.** Procedure for obtaining platelet-rich plasma (PRP).





- and clinical results. *J Shoulder Elbow Surg.* 2007;16(6):759-765.
11. Klepps S, Bishop J, Lin J, et al. Prospective evaluation of the effect of rotator cuff integrity on the outcome of open rotator cuff repairs. *Am J Sports Med.* 2004;32(7):1716-1722.
  12. Sugaya H, Maeda K, Matsuki K, Moriishi J. Repair integrity and functional outcome after arthroscopic double-row rotator cuff repair: a prospective outcome study. *J Bone Joint Surg Am.* 2007;89(5):953-960.
  13. Wilson F, Hinov V, Adams G. Arthroscopic repair of full-thickness tears of the rotator cuff: 2- to 14-year follow-up. *Arthroscopy.* 2002;18(2):136-144.
  14. Longo UG, Franceschi F, Ruzzini L, et al. Histopathology of the supraspinatus tendon in rotator cuff tears. *Am J Sports Med.* 2008;36(3):533-538.
  15. Shen PH, Lien SB, Shen HC, Lee CH, Wu SS, Lin LC. Long-term functional outcomes after repair of rotator cuff tears correlated with atrophy of the supraspinatus muscles on magnetic resonance images. *J Shoulder Elbow Surg.* 2008;17(1)(suppl):1S-7S.
  16. Rudzki JR, Adler RS, Warren RF, et al. Contrast-enhanced ultrasound characterization of the vascularity of the rotator cuff tendon: age- and activity-related changes in the intact asymptomatic rotator cuff. *J Shoulder Elbow Surg.* 2008;17(1)(suppl):96S-100S.
  17. Kim DH, ElAttrache NS, Tibone JE, et al. Biomechanical comparison of a single-row versus double-row suture anchor technique for rotator cuff repair. *Am J Sports Med.* 2006;34(3):407-414.
  18. Ma CB, Comerford L, Wilson J, Puttlitz CM. Biomechanical evaluation of arthroscopic rotator cuff repairs: double-row compared with single-row fixation. *J Bone Joint Surg Am.* 2006;88(2):403-410.
  19. Mazzocca AD, Millett PJ, Guaniche CA, Santangelo SA, Arciero RA. Arthroscopic single-row versus double-row suture anchor rotator cuff repair. *Am J Sports Med.* 2005;33(12):1861-1868.
  20. Park MC, ElAttrache NS, Tibone JE, Ahmad CS, Jun BJ, Lee TQ. Part I: footprint contact characteristics for a transosseous-equivalent rotator cuff repair technique compared with a double-row repair technique. *J Shoulder Elbow Surg.* 2007;16(4):461-468.
  21. Park MC, Tibone JE, ElAttrache NS, Ahmad CS, Jun BJ, Lee TQ. Part II: biomechanical assessment for a footprint-restoring transosseous-equivalent rotator cuff repair technique compared with a double-row repair technique. *J Shoulder Elbow Surg.* 2007;16(4):469-476.
  22. Aoki M, Miyamoto S, Okamura K, Yamashita T, Ikada Y, Matsuda S. Tensile properties and biological response of poly(L-lactic acid) felt graft: an experimental trial for rotator-cuff reconstruction. *J Biomed Mater Res B Appl Biomater.* 2004;71(2):252-259.
  23. Derwin KA, Codsí MJ, Milks RA, Baker AR, McCarron JA, Iannotti JP. Rotator cuff repair augmentation in a canine model with use of a woven poly-L-lactide device. *J Bone Joint Surg Am.* 2009;91(5):1159-1171.
  24. Moffat KL, Kwei AS, Spalazzi JP, Doty SB, Levine WN, Lu HH. Novel nanofiber-based scaffold for rotator cuff repair and augmentation. *Tissue Eng Part A.* 2009;15(1):115-126.
  25. Post M. Rotator cuff repair with carbon filament: a preliminary report of five cases. *Clin Orthop Relat Res.* 1985;(196):154-158.
  26. Yokoya S, Mochizuki Y, Nagata Y, Deie M, Ochi M. Tendon-bone insertion repair and regeneration using polyglycolic acid sheet in the rabbit rotator cuff injury model. *Am J Sports Med.* 2008;36(7):1298-1309.
  27. Bynum CK, Lee S, Mahar A, Tasto J, Pedowitz R. Failure mode of suture anchors as a function of insertion depth. *Am J Sports Med.* 2005;33(7):1030-1034.
  28. Cummins CA, Murrell GA. Mode of failure for rotator cuff repair with suture anchors identified at revision surgery. *J Shoulder Elbow Surg.* 2003;12(2):128-133.
  29. Zheng N, Harris HW, Andrews JR. Failure analysis of rotator cuff repair: a comparison of three double-row techniques. *J Bone Joint Surg Am.* 2008;90(5):1034-1042.
  30. Brady PC, Arrigoni P, Burkhart SS. Evaluation of residual rotator cuff defects after in vivo single- versus double-row rotator cuff repairs. *Arthroscopy.* 2006;22(10):1070-1075.
  31. Nelson CO, Sileo MJ, Grossman MG, Serrahsu F. Single-row modified Mason-Allen versus double-row arthroscopic rotator cuff repair: a biomechanical and surface area comparison. *Arthroscopy.* 2008;24(8):941-948.
  32. Ahmad CS, Kleweno C, Jacir AM, et al. Biomechanical performance of rotator cuff repairs with humeral rotation: a new rotator cuff repair failure model. *Am J Sports Med.* 2008;36(5):888-892.
  33. Baums MH, Buchhorn GH, Spahn G, Poppendieck B, Schultz W, Klinger HM. Biomechanical characteristics of single-row repair in comparison to double-row repair with consideration of the suture configuration and suture material. *Knee Surg Sports Traumatol Arthrosc.* 2008;16(11):1052-1060.
  34. Domb BG, Glousman RE, Brooks A, Hansen M, Lee TQ, ElAttrache NS. High-tension double-row footprint repair compared with reduced-tension single-row repair for massive rotator cuff tears. *J Bone Joint Surg Am.* 2008;90(suppl 4):35-39.
  35. Milano G, Grasso A, Zarelli D, Deriu L, Cillo M, Fabbriani C. Comparison between single-row and double-row rotator cuff repair: a biomechanical study. *Knee Surg Sports Traumatol Arthrosc.* 2008;16(1):75-80.
  36. Wall LB, Keener JD, Brophy RH. Double-row vs single-row rotator cuff repair: a review of the biomechanical evidence. *J Shoulder Elbow Surg.* 2009;18(6):933-941.
  37. Lorbach O, Bachelier F, Veas J, Kohn D, Pape D. Cyclic loading of rotator cuff reconstructions: single-row repair with modified suture configurations versus double-row repair. *Am J Sports Med.* 2008;36(8):1504-1510.
  38. Adams JE, Zobitz ME, Reach JS Jr, An KN, Steinmann SP. Rotator cuff repair using an acellular dermal matrix graft: an in vivo study in a canine model. *Arthroscopy.* 2006;22(7):700-709.
  39. Lo IK, Burkhart SS. Double-row arthroscopic rotator cuff repair: re-establishing the footprint of the rotator cuff. *Arthroscopy.* 2003;19(9):1035-1042.
  40. Meier SW, Meier JD. Rotator cuff repair: the effect of double-row fixation on three-dimensional repair site. *J Shoulder Elbow Surg.* 2006;15(6):691-696.
  41. Bisson LJ, Manohar LM. A biomechanical comparison of transosseous-suture anchor and suture bridge rotator cuff repairs in cadavers. *Am J Sports Med.* 2009;37(10):1991-1995.
  42. Busfield BT, Glousman RE, McGarry MH, Tibone JE, Lee TQ. A biomechanical comparison of 2 technical variations of double-row rotator cuff fixation: the importance of medial row knots. *Am J Sports Med.* 2008;36(5):901-906.
  43. Gerber C, Schneeberger AG, Beck M, Schlegel U. Mechanical strength of repairs of the rotator cuff. *J Bone Joint Surg Br.* 1994;76(3):371-380.
  44. Burkhart SS, Adams CR, Burkhart SS, Schoolfield JD. A biomechanical comparison of 2 techniques of footprint reconstruction for rotator cuff repair: the Swivelock-FiberChain construct versus standard double-row repair. *Arthroscopy.* 2009;25(3):274-281.
  45. Franceschi F, Ruzzini L, Longo UG, et al. Equivalent clinical results of arthroscopic single-row and double-row suture anchor repair for rotator cuff tears: a randomized controlled trial. *Am J Sports Med.* 2007;35(8):1254-1260.
  46. Burks RT, Crim J, Brown N, Fink B, Greis PE. A prospective randomized clinical trial comparing arthroscopic single- and double-row rotator cuff repair: magnetic resonance imaging and early clinical evaluation. *Am J Sports Med.* 2009;37(4):674-682.
  47. Duquin TR, Buyea C, Bisson LJ. Which method of rotator cuff repair leads to the highest rate of structural healing? *Am J Sports Med.* 2010;38(4):835-841.
  48. Frank JB, ElAttrache NS, Dines JS, Blackburn A, Crues J, Tibone JE. Repair site integrity after arthroscopic transosseous-equivalent suture-bridge rotator cuff repair. *Am J Sports Med.* 2008;36(8):1496-1503.
  49. Lafosse L, Brozka R, Toussaint B, Gobezie R. The outcome and structural integrity of arthroscopic rotator cuff repair with use of the double-row suture anchor technique. *J Bone Joint Surg Am.* 2007;89(7):1533-1541.
  50. Lafosse L, Brozka R, Toussaint B, Gobezie R. The outcome and structural integrity of arthroscopic rotator cuff repair with use of the double-row suture anchor technique: surgical technique. *J Bone Joint Surg Am.* 2008;90(suppl 2, pt 2):275-286.
  51. Funakoshi T, Majima T, Iwasaki N, et al. Application of tissue engineering techniques for rotator cuff regeneration using a chitosan-based hyaluronan hybrid fiber scaffold. *Am J Sports Med.* 2005;33(8):1193-1201.
  52. Kimura A, Aoki M, Fukushima S, Ishii S, Yamakoshi K. Reconstruction of a defect of the rotator cuff with polytetrafluoroethylene felt graft: recovery of tensile strength and histocompatibility in an animal model. *J Bone Joint Surg Br.* 2003;85(2):282-287.
  53. Koh JL, Szomor Z, Murrell GA, Warren RF. Supplementation of rotator cuff repair with a bioresorbable scaffold. *Am J Sports Med.* 2002;30(3):410-413.
  54. Derwin KA, Baker AR, Spragg RK, Leigh DR, Iannotti JP. Commercial extracellular matrix scaffold

- folds for rotator cuff tendon repair: biomechanical, biochemical, and cellular properties. *J Bone Joint Surg Am*. 2006;88(12):2665-2672.
55. Malcarney HL, Bonar F, Murrell GA. Early inflammatory reaction after rotator cuff repair with a porcine small intestine submucosal implant: a report of 4 cases. *Am J Sports Med*. 2005;33(6):907-911.
56. Valentin JE, Badylak JS, McCabe GP, Badylak SF. Extracellular matrix bioscaffolds for orthopaedic applications: a comparative histologic study. *J Bone Joint Surg Am*. 2006;88(12):2673-2686.
57. Walton JR, Bowman NK, Khatib Y, Linklater J, Murrell GA. Restore orthobiologic implant: not recommended for augmentation of rotator cuff repairs. *J Bone Joint Surg Am*. 2007;89(4):786-791.
58. Zheng MH, Chen J, Kirilak Y, Willers C, Xu J, Wood D. Porcine small intestine submucosa (SIS) is not an acellular collagenous matrix and contains porcine DNA: possible implications in human implantation. *J Biomed Mater Res B Appl Biomater*. 2005;73(1):61-67.
59. Snyder SJ, Arnoczky SP, Bond JL, Dopirak R. Histologic evaluation of a biopsy specimen obtained 3 months after rotator cuff augmentation with GraftJacket Matrix. *Arthroscopy*. 2009;25(3):329-333.
60. Sclamberg SG, Tibone JE, Itamura JM, Kasraeian S. Six-month magnetic resonance imaging follow-up of large and massive rotator cuff repairs reinforced with porcine small intestinal submucosa. *J Shoulder Elbow Surg*. 2004;13(5):538-541.
61. Soler JA, Gidwani S, Curtis MJ. Early complications from the use of porcine dermal collagen implants (Permacol) as bridging constructs in the repair of massive rotator cuff tears: a report of 4 cases. *Acta Orthop Belg*. 2007;73(4):432-436.
62. Badylak SF, Gilbert TW. Immune response to biologic scaffold materials. *Semin Immunol*. 2008;20(2):109-116.
63. Jarman-Smith ML, Bodamyali T, Stevens C, Howell JA, Horrocks M, Chaudhuri JB. Porcine collagen crosslinking, degradation and its capability for fibroblast adhesion and proliferation. *J Mater Sci Mater Med*. 2004;15(8):925-932.
64. Barber FA, Herbert MA, Boothby MH. Ultimate tensile failure loads of a human dermal allograft rotator cuff augmentation. *Arthroscopy*. 2008;24(1):20-24.
65. Chen CH. Graft healing in anterior cruciate ligament reconstruction. *Sports Med Arthrosc Rehabil Ther Technol*. 2009;1(1):21.
66. Kyung HS, Kim SY, Oh CW, Kim SJ. Tendon-to-bone tunnel healing in a rabbit model: the effect of periosteum augmentation at the tendon-to-bone interface. *Knee Surg Sports Traumatol Arthrosc*. 2003;11(1):9-15.
67. Ohtera K, Yamada Y, Aoki M, Sasaki T, Yamakoshi K. Effects of periosteum wrapped around tendon in a bone tunnel: a biomechanical and histological study in rabbits. *Crit Rev Biomed Eng*. 2000;28(1-2):115-118.
68. Ritsilä VA, Santavirta S, Alhopuro S, et al. Periosteal and perichondral grafting in reconstructive surgery. *Clin Orthop Relat Res*. 1994;(302):259-265.
69. Youn I, Jones DG, Andrews PJ, Cook MP, Suh JK. Periosteal augmentation of a tendon graft improves tendon healing in the bone tunnel. *Clin Orthop Relat Res*. 2004;(419):223-231.
70. Chang CH, Chen CH, Su CY, Liu HT, Yu CM. Rotator cuff repair with periosteum for enhancing tendon-bone healing: a biomechanical and histological study in rabbits. *Knee Surg Sports Traumatol Arthrosc*. 2009;17(12):1447-1453.
71. Scheibel M, Brown A, Woertler K, Imhoff AB. Preliminary results after rotator cuff reconstruction augmented with an autologous periosteal flap. *Knee Surg Sports Traumatol Arthrosc*. 2007;15(3):305-314.
72. Cole BJ, Gomoll AH, Yanke A, et al. Biocompatibility of a polymer patch for rotator cuff repair. *Knee Surg Sports Traumatol Arthrosc*. 2007;15(5):632-637.
73. Jayabalan M, Rathinam K. Effects of biostability and morphology on host response of polyurethane-based soft tissue implants. *Clin Mater*. 1992;11(1-4):179-191.
74. Nair PD, Mohanty M, Rathinam K, Jayabalan M, Krishnamurthy VN. Studies on the effect of degree of hydrophilicity on tissue response of polyurethane interpenetrating polymer networks. *Biomaterials*. 1992;13(8):537-542.
75. Sanders JE, Bale SD, Neumann T. Tissue response to microfibers of different polymers: polyester, polyethylene, polylactic acid, and polyurethane. *J Biomed Mater Res*. 2002; 62(2):222-227.
76. Zhang YZ, Bjursten LM, Freij-Larsson C, Kober M, Wesslén B. Tissue response to commercial silicone and polyurethane elastomers after different sterilization procedures. *Biomaterials*. 1996;17(23):2265-2272.
77. Hickey DG, Frenkel SR, Di Cesare PE. Clinical applications of growth factors for articular cartilage repair. *Am J Orthop (Belle Mead NJ)*. 2003;32(2):70-76.
78. Kajikawa Y, Morihara T, Sakamoto H, et al. Platelet-rich plasma enhances the initial mobilization of circulation-derived cells for tendon healing. *J Cell Physiol*. 2008;215(3):837-845.
79. Woodall J Jr, Tucci M, Mishra A, Benghuzzi H. Cellular effects of platelet rich plasma: a study on HL-60 macrophage-like cells. *Biomed Sci Instrum*. 2007;43:266-271.
80. de Mos M, van der Windt AE, Jahr H, et al. Can platelet-rich plasma enhance tendon repair? a cell culture study. *Am J Sports Med*. 2008;36(6):1171-1178.
81. de Vos RJ, Weir A, van Schie HT, et al. Platelet-rich plasma injection for chronic Achilles tendinopathy: a randomized controlled trial. *JAMA*. 2010;303(2):144-149.
82. Lyras D, Kazakos K, Verettas D, et al. Immunohistochemical study of angiogenesis after local administration of platelet-rich plasma in a patellar tendon defect. *Int Orthop*. 2010;34(1):143-148.
83. Lyras DN, Kazakos K, Verettas D, et al. The effect of platelet-rich plasma gel in the early phase of patellar tendon healing. *Arch Orthop Trauma Surg*. 2009;129(11):1577-1582.
84. Silva A, Sampaio R. Anatomic ACL reconstruction: does the platelet-rich plasma accelerate tendon healing? *Knee Surg Sports Traumatol Arthrosc*. 2009;17(6):676-682.
85. Randelli PS, Arrigoni P, Cabitza P, Volpi P, Maffulli N. Autologous platelet rich plasma for arthroscopic rotator cuff repair: a pilot study. *Disabil Rehabil*. 2008;30(20-22):1584-1589.
86. Maniscalco P, Gambera D, Lunati A, et al. The "Cascade" membrane: a new PRP device for tendon ruptures: description and case report on rotator cuff tendon. *Acta Biomed*. 2008; 79(3):223-226.

## CERVICAL DISK REPLACEMENT IS THERE A MOTION-SPARING ALTERNATIVE TO ANTERIOR CERVICAL DECOMPRESSION AND FUSION?

Brian R. Braaksma, MD;  
Frank M. Phillips, MD

Author Affiliations: Department of Orthopedic Surgery, Rush University Medical Center, Chicago, Illinois.

Corresponding Author: Frank M. Phillips, MD, Rush University Medical Center, 1611 W Harrison St, Suite 300, Chicago, IL 60612 (frank.phillips@rushortho.com).

### Introduction

Anterior cervical decompression and fusion (ACDF) is a well-established treatment of cervical radiculopathy and/or myelopathy resulting from degenerative spondylosis that is refractory to nonoperative care. While the reported results for ACDF are good, fusion has downsides including pseudarthrosis and adjacent segment degeneration.<sup>1,3</sup> Furthermore, the use of anterior cervical plating has been associated with additional complications including dysphagia, implant failure, and screw migration.<sup>3,4</sup> In recent years, total disk replacement (TDR) has been suggested as a reconstructive alternative to fusion, with recent prospective, randomized studies demonstrating outcomes that compare favorably to those of ACDF.<sup>5,6</sup>

Issues relating to disk replacement in the cervical spine are quite different from those in lumbar disk replacement surgery. Lumbar disk replacement has been recommended for the treatment of diskogenic axial back pain, a condition for which diagnosis is imprecise and treatments, such as fusion, have met with inconsistent clinical results.<sup>7-9</sup> In contrast, cervical disk replacement is generally applied after cervical decompression in the treatment of radiculopathy or myelopathy. In these conditions, the role of surgical intervention is well established and the decision to operate is made independently of the choice of reconstruction. Once decompression is accomplished, the decision is made to proceed with TDR or fusion as reconstructive alternatives.

The high success rate and long-term track record of ACDF raise the question of the need for alternate procedures. Proponents of artificial disk technology claim that although cervical arthrodesis is clinically successful in the short term, fusion results in increased biomechanical stresses at adjacent segments that may hasten degeneration at these levels.<sup>10-13</sup> Alternatively, artificial disk replacement maintains motion at the operated level, theoretically maintaining adjacent-level kinematics and reducing the rate of adjacent-level degeneration when compared to fusion. The fate of segments adjacent to fusion has indeed become a primary rationale for the use of TDR.<sup>14</sup>

While no studies have definitively established that symptomatic adjacent-level degeneration after ACDF is a direct result of the altered biomechanics imposed on the cervical spine due to fused motion segments, the literature offers a general consensus and clinical association regarding its occurrence. Symptomatic adjacent-level disease has been reported to occur in more than 25% of patients within 8 to 10 years following ACDF, with nearly half of those symptomatic patients requiring reoperation.<sup>15</sup> While this clinical scenario is commonly encountered, there is a lack of literature on the outcomes of surgical management of symptomatic radiculopathy or myelopathy at a level adjacent to prior fusion. Hilibrand et al, in a retrospective review of patients undergoing ACDF adjacent to a prior fusion, reported a fusion rate of only 63% as well as inferior clinical outcome scores as compared to primary ACDF.<sup>15</sup> Furthermore, the loss of motion across adjacent cervical motion segments is likely to accentuate the detrimental effects of fusion on the

remaining motion segments. Thus, in addressing a symptomatic segment adjacent to prior fusion, a procedure that allows for anterior decompression while preserving motion at the symptomatic level is appealing.

In this review, we will highlight basic science and clinical research studies performed at Rush University Medical Center exploring total disk replacement as an alternative to fusion in the treatment of degenerative cervical conditions.

### Disk Replacement Adjacent to Cervical Fusion: A Biomechanical Comparison of Hybrid Construct vs. Two-Level Fusion

#### Methods

Nine cadaveric cervical spines (C3-T1; age,  $60.2 \pm 3.5$  years) were tested under load-control and displacement-control testing.<sup>16</sup> After intact testing, a simulated fusion was performed at C4-C5, followed by C6-C7. The simulated fusion was then reversed, and the response of Porous Coated Motion (PCM) (NuVasive, San Diego, California) TDR at C5-C6 was measured. A hybrid construct was then tested with the TDR either below or above a single-level fusion and contrasted with a simulated 2-level fusion (C4-C6 and C5-C7).

#### Results

In the cadaveric model, fusion significantly reduced range of motion (ROM) at C4-C5 and C6-C7 by  $74.7 \pm 8.1\%$  and  $78.1 \pm 11.5\%$ , respectively ( $P < .05$ ). TDR performed at C5-C6 maintained total flexion-extension ROM comparable to that of the intact controls when used as a stand-alone procedure or when performed adjacent to a single-level fusion ( $P > .05$ ). The location of the single-level fusion, whether above or below the TDR, did not significantly affect the motion response of the arthroplasty. Performing a 2-level fusion significantly increased the motion demands on the nonoperated segments as compared to a hybrid fusion-TDR construct. The spine with a hybrid construct required significantly less extension moment as compared to the spine with a 2-level fusion to reach the same extension endpoint.

### Effect of Two-Level Total Disk Replacement on Cervical Spine Kinematics

#### Methods

Six human cadaveric cervical spine specimens (C3-C7; age,  $57 \pm 12$  years) were tested intact, after TDR (Discover; DePuy Spine, Raynham, Massachusetts) at C5-C6, and after additional TDR (Discover) at C6-C7.<sup>17</sup> Specimens were subjected to flexion-extension ( $\pm 1.5 \text{ N} \cdot \text{m}$ ), lateral bending ( $\pm 1.5 \text{ N} \cdot \text{m}$ ), and axial rotation ( $\pm 1.5 \text{ N} \cdot \text{m}$ ). Flexion-extension was tested under 150 N follower preload. Segmental ROM was measured at all levels using optoelectronic instrumentation and also monitored using digital fluoroscopy images. Two comparisons on segmental

ROM were made for implanted and adjacent levels: (1) intact versus single-level TDR and (2) single-level TDR versus 2-level TDR. The level of significance was  $\alpha = 0.025$ .

#### Results

TDR at C5-C6 increased the flexion-extension ROM of the implanted segment compared to intact under a 150 N preload ( $8.6 \pm 1.0$  degrees vs.  $12.3 \pm 3.3$  degrees,  $P < .025$ ). The TDR maintained a range of motion comparable to that of intact specimens in lateral bending ( $7.4 \pm 2.6$  degrees vs.  $6.0 \pm 1.6$  degrees,  $P > .025$ ) and in axial rotation ( $5.5 \pm 1.9$  degrees vs.  $6.0 \pm 2.9$  degrees,  $P > .025$ ). The single-level TDR at C5-C6 did not significantly affect the ROM at the intact adjacent levels (C6-C7 or C4-C5) from their intact values in any of the 3 loading modes. Implantation of a second TDR at C6-C7 (in addition to the C5-C6 TDR) maintained the ROM at the C6-C7 segment at intact (presurgical) values in flexion-extension ( $9.6 \pm 4.3$  degrees vs.  $11.2 \pm 5.5$  degrees,  $P > .025$ ), lateral bending ( $6.1 \pm 4.0$  degrees vs.  $4.1 \pm 2.1$  degrees,  $P > .025$ ), and axial rotation ( $6.7 \pm 3.6$  degrees vs.  $5.5 \pm 3.7$  degrees,  $P > .025$ ). The second disk prosthesis (at C6-C7) did not affect the ROM of the prosthesis that was already implanted at the adjacent level. The 2-level TDR at C5-C7 also did not affect the ROM at C4-C5 from its values after the first TDR at C5-C6 in flexion-extension or axial rotation. However, in lateral bending a small but significant increase was noted ( $8.9 \pm 3.6$  degrees vs.  $10.1 \pm 4.5$  degrees,  $P < .025$ ).

### Index and Adjacent-Level Kinematics Following Cervical Disk Replacement and Anterior Fusion: In Vivo Quantitative Radiographic Analysis

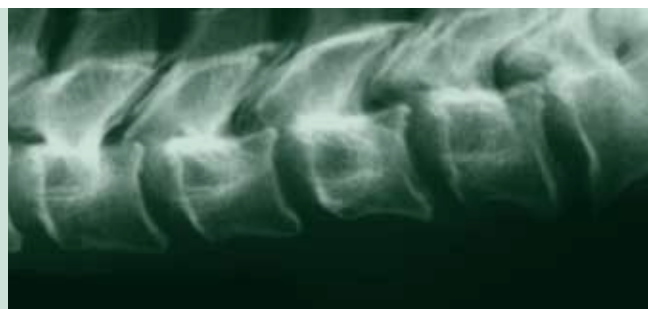#### Methods

As part of a multicenter, prospective, randomized Food and Drug Administration (FDA) investigational device exemption (IDE) clinical evaluation<sup>18</sup> of the Porous Coated Motion artificial cervical disk, patients underwent either a single-level TDR (272 patients) or ACDF (182 patients) for treatment of cervical radiculopathy or myelopathy. Neutral, flexion, and extension radiographs of the cervical spine obtained preoperatively and at 3, 6, and 12 months postoperatively were assessed. Quantitative assessments and comparisons of motion patterns were produced using validated computer-assisted methods. Kinematic parameters including segmental rotation, translation, center of rotation, disk height, and disk angle were calculated.

#### Results

In patients treated with fusion, angular motion at the superior adjacent level increased from 9.6 degrees preoperatively to 11.0 degrees ( $P = .003$ ) at 12 months (Figure 1) with a trend toward increased postoperative translation ( $P = .07$ ). In contrast, cervical TDR preserved angular motion at the operated level, although the range was reduced from 8.0 degrees preopera-

“Cervical disk replacement is an exciting technology that, in our studies, preserves kinematics at treated as well as adjacent levels in single and multilevel constructs.”



tively to 6.2 degrees at 12 months postoperatively ( $P < .001$ ). Following TDR, adjacent-level angular motion was unchanged (Figure 2). For the TDR group, the vertical and horizontal centers of rotation at the treated level remained within 0.5 mm of their preoperative locations (Figure 3). Centers of rotation at the adjacent levels were unaltered by fusion or TDR. Lordotic alignment and disk height at the index level increased post intervention in both groups.

### Cervical Disk Replacement in Patients With and Without Previous Adjacent-Level Fusion Surgery: A Prospective Study

#### Methods

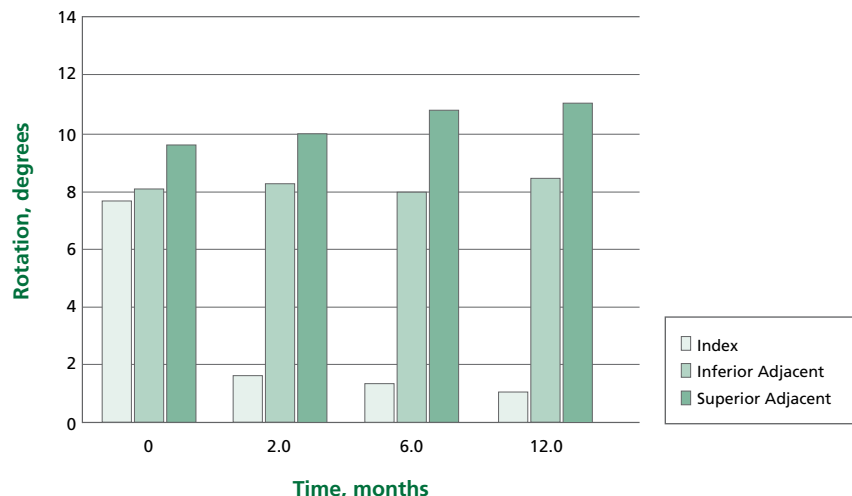
Patients between ages of 18 and 65 with single-level cervical radiculopathy and/or myelopathy, unresponsive to at least 6 weeks of nonsurgical therapy or experiencing progressive

neurological symptoms, were enrolled in a prospective study.<sup>19</sup> After surgery, patients returned for scheduled follow-up visits at 6 weeks, 3 months, 6 months, 1 year, and 2 years. Patients' self-reported outcome assessments, including the Neck Disability Index (NDI) and neck and arm visual analog scale (VAS) scores, were obtained at all follow-up visits, and all complications or adverse events were recorded. Clinical and radiographic outcomes were compared for patients who received a PCM disk at a level adjacent to a prior ACDF (Figure 4) and those who had not previously had fusion performed. Statistical analysis of reported clinical outcomes was performed using 2-way analysis of variance.

#### Results

In this study, 126 patients received a primary TDR (mean age, 44.4 years) and 26 patients had previously had adjacent-level fusion surgery (mean age, 46.4 years). Surgery time was similar

**Figure 1.** Angular motion at index and adjacent levels in patients treated with fusion. In patients treated with fusion, angular motion at the superior adjacent level increased from 9.6 degrees preoperatively to 11.0 degrees ( $P = .003$ ) at 12 months. Data were not collected at 1.5 months.



in both groups (96 minutes and 98 minutes, respectively;  $P = .761$ ), and mean blood loss was 76 mL and 66 mL in the 2 groups, respectively ( $P = .491$ ). Clinical outcomes using NDI and neck and arm VAS scores showed significant improvement after surgery and were similar between groups at all follow-up visits (Table). Revision surgery was required in 2 of 126 patients receiving a primary TDR and in 2 of 26 patients in the adjacent-to-fusion cohort.

### Discussion

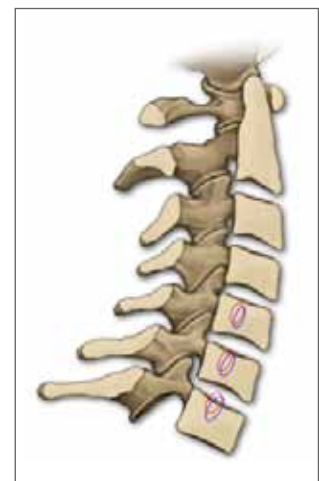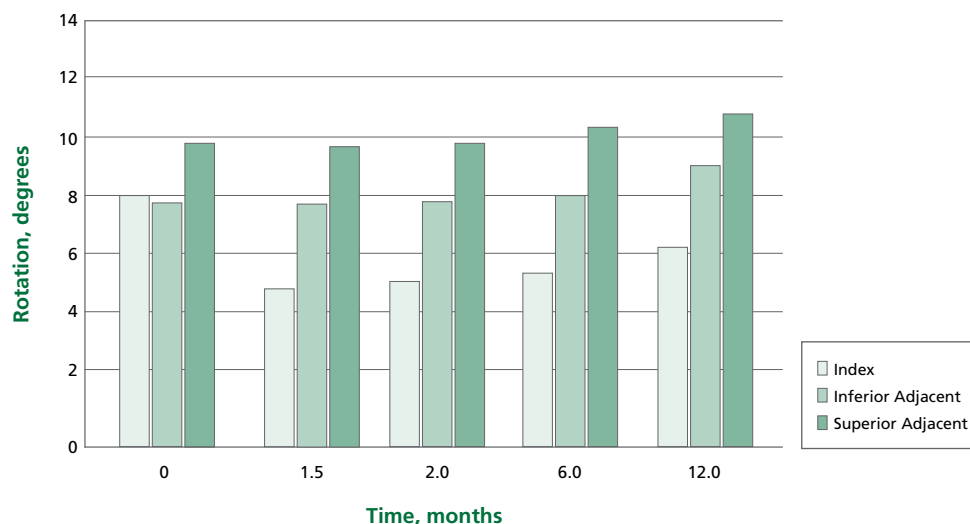
Our studies have helped elucidate the biomechanics and clinical outcomes for cervical TDR. Previous biomechanical studies suggest that single-level cervical fusion alters adjacent-level kinematics<sup>20,21</sup> whereas TDR leads to a normalization of load transfer and kinematics at adjacent levels when compared to fusion.<sup>22,23</sup> DiAngelo et al have shown that after anterior cervical fusion, an increase in motion at adjacent segments compensates for the loss of motion at the index level.<sup>20</sup> In contrast, the use of an artificial disk replacement did not alter motion at either the index

or adjacent levels. This has obvious implications for potential adjacent-level protection. The deleterious effects of fusion on adjacent levels are likely to be accentuated when fusion is performed on multiple levels, a frequent clinical scenario.

In biomechanical studies performed with varying designs of disk prostheses, we have elucidated the kinematic effects of multilevel fusion, multilevel TDR, and hybrid constructs with TDR adjacent to fusion. We demonstrated that TDR maintained motion comparable to that of intact controls when used as a stand-alone procedure as well as when implanted adjacent to a single-level fusion. In contrast, a 2-level fusion significantly increased the motion demands on the nonoperated segments as compared to a hybrid construct. Further, we demonstrated that the insertion of a second TDR adjacent to an existing TDR did not alter the kinematic properties of either implant, nor did it adversely affect kinematics of the remaining intact cervical motion segments. These data suggest the ability of current TDR designs to function in these challenging biomechanical environments.

**Figure 2.** Angular motion at index and adjacent levels in patients treated with TDR. In contrast to fusion (Figure 1), TDR better preserved angular motion at the operated level, although the range was reduced from 8.0 degrees preoperatively to 6.2 degrees at 12 months postoperatively ( $P < .001$ ). Furthermore, adjacent-level angular motion was unchanged.

**Figure 3.** Diagram of cervical spine showing centers of rotation for index and adjacent levels before and after TDR. The center of rotation (COR) for each level after TDR (blue) was slightly altered to a more anterior and inferior position within 0.5 mm of the preoperative location (red) in either direction. The new COR locations were, however, still within the normal range.



**Figure 2**

**Figure 3**

The basic science data were supported in a large prospective, randomized clinical trial<sup>18</sup> where we found that the PCM TDR maintains motion at both the index and adjacent motion segments. In contrast, fusion results in the development of hypermobility of the adjacent level over time. We also report the detailed kinematics of the treated and adjacent levels after reconstruction with either fusion or TDR in vivo. Finally, in a prospective clinical study,<sup>19</sup> we showed that the early clinical outcomes of TDR implanted adjacent to a previously fused segment compare favorably to the outcomes of primary TDR.

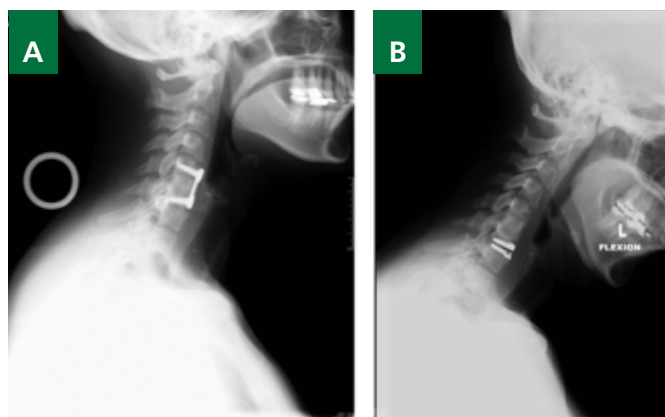
### Conclusion

While clinical reports of the success of cervical TDR are encouraging, they are also quite preliminary. Cervical disk replacement is an exciting technology that, in our studies, preserves kinematics at treated as well as adjacent levels in single and multilevel constructs. By preserving more normal kinematics, TDR has the potential to improve load transfer to the adjacent levels as compared to fusion. However, it remains challenging to determine whether the reports of degeneration adjacent to cervical fusion reflect only the consequence of altered biomechanics resulting from the fusion or represent to some degree the natural tendency toward degeneration of the cervical spine with aging.

**Table.** Neck Disability Index (NDI), Neck Visual Analog Scale (VAS), and Most Painful Arm VAS Clinical Outcome Scores (Mean ± Standard Deviation)

**Figure 4.** A, Lateral radiograph showing preoperative spondylosis below a prior C5-C6 anterior cervical decompression and fusion (ACDF). B, Lateral radiograph, in flexion, showing C6-C7 Porous Coated Motion (PCM) implant adjacent to previous fusion.

Time of Follow-up wk	Primary TDR (n)	TDR Adjacent to Prior Fusion (n)
<b>NDI</b>		
0	28.1 ± 7.3 (126)	28.2 ± 7.5 (26)
6	14.8 ± 9.6 (116)	17.6 ± 9.5 (23)
12	12.2 ± 9.6 (104)	12.8 ± 9.9 (24)
26	11.2 ± 9.9 (98)	11.1 ± 10.3 (24)
52	10.8 ± 10.5 (91)	11.7 ± 10.5 (21)
<b>Neck VAS</b>		
0	68.5 ± 23.1 (126)	72.0 ± 16.4 (26)
6	28.3 ± 23.0 (120)	33.7 ± 27.9 (26)
12	26.2 ± 23.6 (106)	31.0 ± 30.9 (25)
26	25.6 ± 25.7 (99)	28.4 ± 30.5 (25)
52	25.8 ± 25.8 (93)	28.4 ± 29.6 (21)
<b>Arm VAS</b>		
0	71.3 ± 19.8 (126)	78.2 ± 17.2 (26)
6	25.3 ± 26.4 (120)	31.0 ± 30.8 (26)
12	24.3 ± 26.8 (106)	27.4 ± 32.8 (25)
26	25.2 ± 28.0 (99)	23.1 ± 27.2 (25)
52	27.2 ± 30.2 (93)	31.0 ± 34.3 (21)



**Figure 4**

**Table**

## References

1. Tribus CB, Corteen DP, Zdeblick TA. The efficacy of anterior cervical plating in the management of symptomatic pseudoarthrosis of the cervical spine. *Spine*. 1999;24(9):860-864.
2. Phillips FM, Carlson G, Emery SE, Bohlman HH. Anterior cervical pseudarthrosis: natural history and treatment. *Spine*. 1997;22(14):1585-1589.
3. Gore DR, Sepic SB. Anterior discectomy and fusion for painful cervical disc disease: a report of 50 patients with an average follow-up of 21 years. *Spine*. 1998;23(19):2047-2051.
4. Gore DR, Sepic SB. Anterior cervical fusion for degenerated or protruded discs: a review of one hundred forty-six patients. *Spine*. 1984;9(7):667-671.
5. Robertson JT, Metcalf NH. Long-term outcome after implantation of the Prestige I disc in an end-stage indication: 4-year results from a pilot study. *Neurosurg Focus*. 2004;17(3):E10.
6. Porchet F, Metcalf NH. Clinical outcomes with the Prestige II cervical disc: preliminary results from a prospective randomized clinical trial. *Neurosurg Focus*. 2004;17(3):E6.
7. Han X, Zhu Y, Cui C, Wu Y. A meta-analysis of circumferential fusion versus instrumented posterolateral fusion in the lumbar spine. *Spine*. 2009;34(17):E618-E625.
8. Gibson JN, Grant IC, Waddell G. The Cochrane review of surgery for lumbar disc prolapse and degenerative lumbar spondylosis. *Spine*. 1999;24(17):1820-1832.
9. Arnold PM, Robbins S, Paullus W, Faust S, Holt R, McGuire R. Clinical outcomes of lumbar degenerative disc disease treated with posterior lumbar interbody fusion allograft spacer: a prospective, multicenter trial with 2-year follow-up. *Am J Orthop (Belle Mead NJ)*. 2009;38(7):E115-E122.
10. Matsumoto M, Okada E, Ichihara D, et al. Anterior cervical decompression and fusion accelerates adjacent segment degeneration: comparison with asymptomatic volunteers in a ten-year magnetic resonance imaging follow-up study. *Spine*. 2010;35(1):36-43.
11. Tchako A, Sadegh AM. Stress changes in intervertebral discs of the cervical spine due to partial discectomies and fusion. *J Biomech Eng*. 2009;131(5):051013.
12. Nabhan A, Steudel WI, Nabhan A, Pape D, Ishak B. Segmental kinematics and adjacent level degeneration following disc replacement versus fusion: RCT with three years of follow-up. *J Long Term Eff Med Implants*. 2007;17(3):229-236.
13. Lopez-Espina CG, Amirouche F, Havalad V. Multilevel cervical fusion and its effect on disc degeneration and osteophyte formation. *Spine*. 2006;31(9):972-978.
14. Phillips FM, Garfin SR. Cervical disc replacement. *Spine*. 2005;30(17)(suppl):S27-S33.
15. Hilibrand AS, Carlson GD, Palumbo MA, Jones PK, Bohlman HH. Radiculopathy and myelopathy at segments adjacent to the site of a previous anterior cervical arthrodesis. *J Bone Joint Surg Am*. 1999;81(4):519-528.
16. Lee M, Dumonski M, Phillips F, et al. Disc replacement adjacent to cervical fusion: a biomechanical comparison of hybrid construct vs. two-level fusion. Presented at: 36th Annual Meeting of the Cervical Spine Research Society; December 2008; Austin, TX.
17. Phillips FM, Tzermiadianos MN, Voronov LI, et al. Effect of two-level total disc replacement on cervical spine kinematics. *Spine*. 2009;34(22):E794-E799.
18. Park D, Lin D, Phillips F. Index and adjacent level kinematics following cervical disc replacement and anterior fusion: in vivo quantitative radiographic analysis. Presented at: 37th Annual Meeting of the Cervical Spine Research Society; December 2009; Salt Lake City, UT. *Spine*. In press.
19. Phillips FM, Allen TR, Regan JJ, et al. Cervical disc replacement in patients with and without previous adjacent level fusion surgery: a prospective study. *Spine*. 2009;34(6):556-565.
20. DiAngelo DJ, Roberston JT, Metcalf NH, McVay BJ, Davis RC. Biomechanical testing of an artificial cervical joint and an anterior cervical plate. *J Spinal Disord Tech*. 2003;16(4):314-323.
21. Maiman DJ, Kumaresan S, Yoganandan N, Pintar FA. Biomechanical effect of anterior cervical spine fusion on adjacent segments. *Biomed Mater Eng*. 1999;9(1):27-38.
22. Eck JC, Humphreys SC, Lim TH, et al. Biomechanical study on the effect of cervical spine fusion on adjacent-level intradiscal pressure and segmental motion. *Spine*. 2002;27(22):2431-2434.
23. Wigfield CC, Skrzypiec D, Jackowski A, Adams MA. Internal stress distribution in cervical intervertebral discs: the influence of an artificial cervical joint and simulated anterior interbody fusion. *J Spinal Disord Tech*. 2003;16(5):441-449.



## PERIOPERATIVE ORAL PREGABALIN REDUCES CHRONIC PAIN AFTER TOTAL KNEE ARTHROPLASTY A PROSPECTIVE, RANDOMIZED, CONTROLLED TRIAL

Asokumar Buvanendran, MD; Jeffrey S. Kroin, PhD; Craig J. Della Valle, MD; Maruti Kari, MD; Mario Moric, MS; Kenneth J. Tuman, MD

Author Affiliations: Department of Anesthesiology, Rush University Medical Center, Chicago, Illinois (Drs Buvanendran, Kroin, Kari, Moric, and Tuman); and Department of Orthopedic Surgery, Rush University Medical Center, Chicago, Illinois (Dr Della Valle).

Corresponding Author: Craig J. Della Valle, MD, Rush University Medical Center, 1611 W. Harrison St., Suite 300, Chicago, IL 60612 (craigdv@yahoo.com).

Previous Publication: This article was previously published in *Anesthesia & Analgesia* (2010;110:199-207). Minor edits have been made.

### Introduction

Osteoarthritis currently affects approximately 27 million adults in the United States and is expected to increase by the year 2030.<sup>1</sup> The sequelae of arthritis, such as pain and disability, frequently necessitate joint replacement surgery. Total knee arthroplasty (TKA) is a highly effective treatment for end-stage knee osteoarthritis, and correspondingly, these procedures are increasing both in the United States and globally. In the United States alone, 550 000 TKAs were performed in 2007.<sup>2</sup>

Despite advances in surgical technology and perioperative anesthetic management, the incidence of chronic neuropathic pain after TKA surgery has not decreased<sup>3</sup> and is as high as 12.7% at 6 months postoperatively.<sup>4</sup> Neuropathic pain is a distressing condition that is characterized by allodynia, hyperalgesia, edema, and skin color changes of the limb. Treatment of neuropathic pain is often both challenging and prolonged, with substantially diminished quality of life. Gabapentin and the related more potent compound pregabalin have been shown to be beneficial in the treatment of neuropathic pain.<sup>5-7</sup> Because of the chronic and distressing nature of neuropathic pain, as well as the difficulty in treatment and resolution, preventing development of this syndrome is highly advantageous.

Pregabalin given before operation has been shown to reduce dental pain after molar extraction,<sup>8</sup> reduce postoperative morphine requirements after total hip arthroplasty,<sup>9</sup> and attenuate postoperative pain after laparoscopic cholecystectomy<sup>10</sup>; however, other studies show no beneficial effect of pregabalin on acute postoperative pain when administered preoperatively for minor gynecological procedures,<sup>11</sup> elective ambulatory and short-stay operations,<sup>12</sup> and laparoscopic cholecystectomy.<sup>13</sup> However, no clinical study has yet investigated whether perioperative administration of pregabalin can reduce the incidence of postoperative chronic neuropathic pain. The primary objective of this study was to evaluate whether pregabalin given before and for 14 days after TKA reduces the incidence of neuropathic pain assessed at 6 months postoperatively. Secondary outcomes assessed include knee range of motion (ROM), acute postoperative opioid requirements, and time until hospital discharge criteria are achieved.

### Methods

After the researchers received institutional review board (IRB) approval, 350 consecutive patients scheduled to undergo elective primary TKA were contacted and assessed for study eligibility

from August 2006 to August 2007 (Figure 1). Written informed consent was obtained from each patient. Two hundred forty patients undergoing primary TKA were enrolled in this randomized, placebo-controlled, double-blind trial. Patients were randomized to a treatment group using a computer-generated randomization sequence. This study was approved for a physician-sponsored investigational new drug (IND) No. 72 121, issued January 2006, by the Food and Drug Administration (FDA).

#### Inclusion/Exclusion Criteria

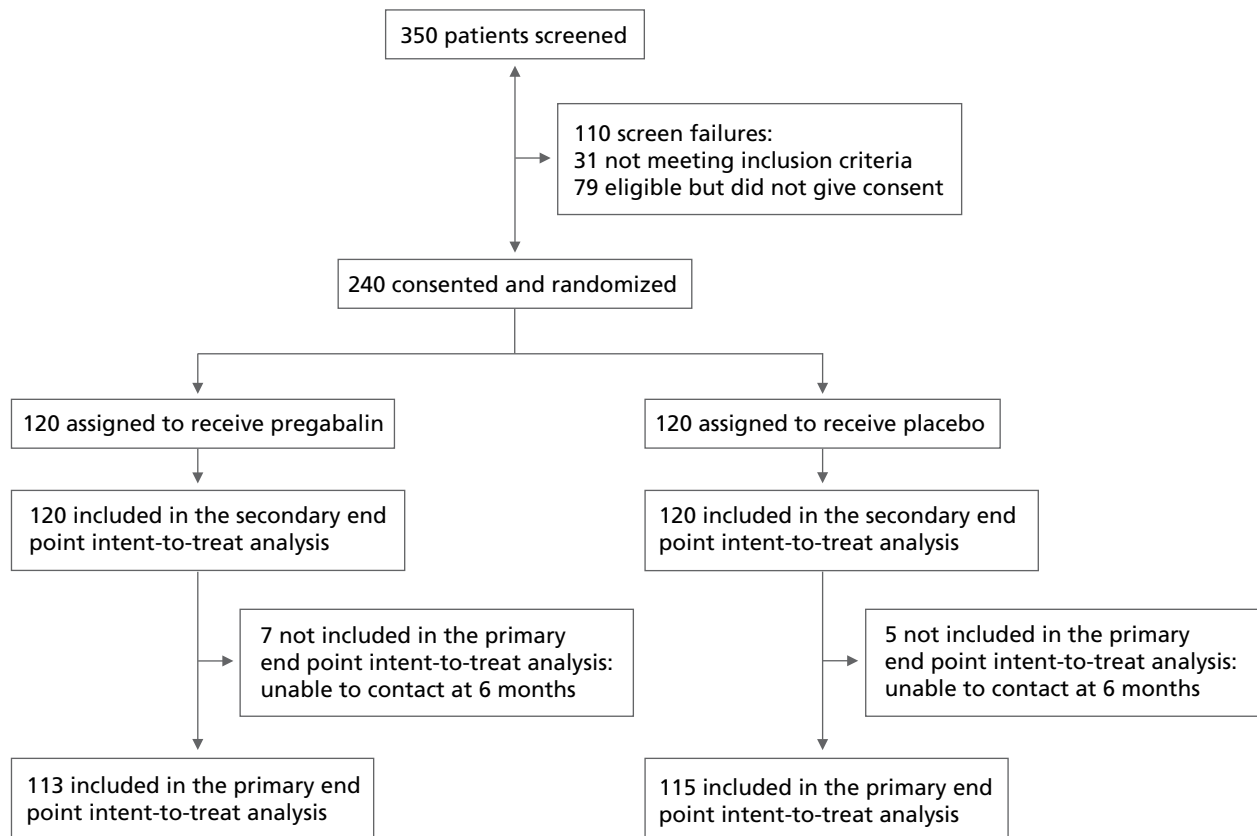
Patients were eligible for the study if they were scheduled to undergo a primary TKA with a diagnosis of osteoarthritis of the operative knee and had the ability to understand and read English. Patients were excluded if they were younger than 21 years or older than 80 years; had an American Society of Anesthesiologists (ASA) physical status of 4; had prior use of gabapentin (or pregabalin) or nonsteroidal anti-inflammatory drugs (NSAIDs) within 2 weeks before the operation; had a history of neuropathic pain or any other chronic pain condition, other than

osteoarthritis pain; were pregnant; had a sulfa allergy; or were currently enrolled in another investigational study.

#### Treatment Protocol

Patients were randomly assigned to receive either the study medication or placebo, using SAS Statistical Software 9.1.3. There was no dose administered on the days before the operation. Patients randomized to the experimental arm of the study received pregabalin 300 mg orally, 1-2 hours before the operation; 150 mg twice daily for the first 10 postoperative days; 75 mg twice daily on days 11 and 12; and 50 mg twice daily on days 13 and 14. Pregabalin is not approved by the FDA for perioperative use, and therefore the primary investigator consulted with the FDA before commencing the study. Dosing was approved in the physician-sponsored IND No. 72 121 by the FDA. Although this is an off-label use of the study drug, the doses did not exceed the daily limit allowed for the treatment of chronic pain. Control patients received PO-matched placebo tablets, at identical time points, with both pregabalin and placebo capsules provided by Pfizer (New York, New York).

Figure 1. CONSORT flow chart of study.



“The principal finding from this randomized, placebo-controlled trial of perioperative administration of pregabalin to patients undergoing TKA was a significant decrease in the incidence of chronic neuropathic pain.”



After discharge, patients were provided with diaries in which they recorded the exact times at which they took pregabalin/placebo each day. All patients were contacted 1 week after their discharge via a phone call to ensure their adherence with the medication regimen. They were asked to return any unused drug, along with the diaries, at their 1-month visit to the surgeon's office. The physicians and nurses managing the patient perioperatively, the personnel involved with postoperative pain assessments and management of the epidural infusion, physical therapists, and the study patients were blinded to group assignments. During the study, only the dispensing pharmacist had knowledge of the study codes. Pfizer, the manufacturer and provider of pregabalin and placebo, was not involved in protocol development, data collection and management, statistical analysis, or manuscript preparation.

In the operating room, patients were sedated with midazolam, and a combined spinal-epidural anesthetic was used for the operation as previously described.<sup>14</sup> After obtaining clear cerebrospinal fluid, 1.5 mL of 0.75% hyperbaric bupivacaine with 25 µg of fentanyl was injected. After the intrathecal injection, a catheter was inserted for epidural drug administration. Patients were sedated with IV propofol for the duration of the operation. At the completion of the operation, an epidural infusion of fentanyl (5 µg/mL) and bupivacaine (1 mg/mL) was initiated using a continuous basal infusion of 6 mL/h with superimposed patient-controlled epidural analgesia (PCEA) bolus doses. Patients were instructed before the operation to use the PCEA mode, so as to maintain their pain score (at rest) between 2 and 4 on the 11-point numerical rating scale (NRS), where 0 equals no pain and 10 equals worst possible pain. If the pain scores could not be maintained (NRS  $\geq$  4 and the maximum number of PCEA boluses was used<sup>14</sup>), the basal infusion rate was increased while maintaining the PCEA mode. However, the maximum amount of epidural solution that could be used per hour was 10 mL. The epidural infusion was discontinued between 32 and 42 hours postoperatively. Patients were then transitioned to oral opioid medications (morphine, oxycodone, and hydromorphone) as needed for adequate pain control (NRS < 4). All patients received preoperative celecoxib 400 mg orally, 1-2 hours before the operation and 200 mg orally twice daily

for 3 days while in the hospital, to conform to the multimodal analgesia protocol used at our facility.<sup>15</sup>

### Operation

Prophylactic antibiotics (cefazolin IV or vancomycin IV) were administered to all patients before the skin incision. TKA was performed under tourniquet control, using an abbreviated medial parapatellar approach with the arthrotomy extending into the quadriceps tendon for 2-4 cm above the superior pole of the patella, and without patellar eversion. A primary, cruciate-retaining TKA was performed in all cases (NexGen CR; Zimmer, Warsaw, Indiana); all components were cemented, and the patella was resurfaced in all cases. At the time of capsular closure, 60 mL of 0.25% bupivacaine with epinephrine was infiltrated into the wound. The knee was closed in 90° of flexion over a nonrefusion drain (Hemovac; Zimmer Snyder, Warsaw, Indiana). The drain was discontinued on postoperative day 1, and patients were started on a physical therapy program that included weight bearing as tolerated and ROM exercises as guided by a physical therapist.

### Outcome Measures

#### Adverse Events

Based on the package labeling for pregabalin, the occurrence of sedation, confusion, dizziness, headache, dry mouth, peripheral edema, and diplopia were assessed daily during hospitalization. In addition, occurrences of postoperative nausea and vomiting and pruritus were recorded based on answers to standardized questions in the morning and evening each day during hospitalization. Patients with postoperative nausea and vomiting were treated with metoclopramide (10 mg) or ondansetron (4 mg) if needed. Adverse events data after hospitalization were supplemented by the surgeon's clinical records up to the 6-month patient visit.

#### Chronic Neuropathic Pain and Related Outcomes

Patients were evaluated in a blinded fashion for lower extremity neuropathic pain at 3 and 6 months after TKA using a measure administered during a telephone interview. The 3-month to

6-month time points are often used to define when acute postoperative pain becomes chronic pain.<sup>3</sup> During this time period, there were no restrictions on patients' use of analgesic drugs. Clinical symptoms of neuropathic pain were assessed, using the self-report version of the Leeds Assessment of Neuropathic Symptoms and Signs pain scale (S-LANSS), to determine the presence of neuropathic pain in the operated leg at each time point (3 and 6 months postoperatively). S-LANSS is a validated, weighted, 7-item assessment tool for neuropathic pain (yes or no for each pain measure) with a maximum score of 24.<sup>16</sup> An S-LANSS score of 12 or more was an indication of chronic neuropathic pain. The 7 variables included 2 self-examination items: allodynia (assessed by gentle rubbing of the operated leg) and hyperalgesia (gently applied pressure from the fingertip); and 5 pain symptoms: pins and needles, skin color change, sensitivity to touch, sudden bursts of pain, and burning. Patients with an S-LANSS score of 12 or more at 6 months came to the physician's office for a standardized physical examination, which included the S-LANSS examination items (allodynia and hyperalgesia) directly assessed by the physician, plus a pinprick evaluation (physician applying pin to painful area and comparing it to a nonpainful area, and then recording an increased response in the painful area versus control area). Preoperative NRS scores were obtained from the orthopedic preoperative office visit. To account for concomitant analgesic use in the 6-month postoperative period, we reviewed the records of patients from postoperative orthopedic office visits, up to 6 months.

In addition, for those patients who were identified with neuropathic pain of the operative knee at 6 months, knee function was quantified using the validated Knee injury and Osteoarthritis Outcome Score–Physical Function Shortform (KOOS-PS).<sup>17</sup> Comparisons of knee function were made between patients with chronic postoperative neuropathic knee pain, case matched by age and surgeon, with 2 sets of patients without chronic pain, 1 from the pregabalin and the other from the placebo groups, using a random selection. Using the KOOS-PS, patients ranked each of the following 7 variables as to the degree of difficulty, from none to extreme (point values: 0–4): rising from bed, putting on socks/stockings, rising from sitting, bending to the floor, twisting/pivoting on the affected knee, kneeling, and squatting. The raw summed score from the KOOS-PS was then converted to a 0–100 scale, Rasch-based person score.<sup>17</sup>

#### *Range of Motion*

The degree of active (patient moving the knee) and passive (movement of the knee with the aid of a physical therapist) knee flexion, measured using a goniometer,<sup>14,18</sup> tolerated by the patient on postoperative days 1–3 was recorded by the physical therapist twice daily, and the maximum daily measure was used for analysis. Follow-up active ROM was assessed at 1 month

postoperatively by orthopedic nurses blinded to the study codes.

#### *Epidural Drug Use and Postoperative Pain Assessment*

Epidural medication consumption was recorded for each 4-hour interval from the completion of the operation to the time that the epidural was discontinued (same as the time to achieve hospital discharge criteria). Because the discontinuation time varied from patient to patient (as they achieved physical therapy criteria), the average hourly consumption (total analgesic used divided by the total infusion time) was used as the measure of epidural drug use. Pain scores at rest were assessed with the NRS rating every 8 hours during the immediate postoperative phase (the first 32–42 hours after the operation). All other oral opioid consumption during the entire hospital stay (mainly after epidural infusion was terminated and also during epidural infusion if needed for breakthrough pain) was recorded and subsequently converted to parenteral morphine equivalents for statistical comparisons.

#### *Discharge Time Criteria*

The time to achieve hospital discharge criteria (physical therapist appraisal of minimal assistance needed for ambulation; hemodynamically stable; stable cardiac rhythm; noninfected incisions and afebrile patient; and ability to void)<sup>19</sup> was determined.

#### *Sleep Interference*

Starting from the morning after the operation and ending at hospital discharge, patients were asked daily to rate sleep interference during the previous night on an 11-point scale (0 = no sleep disturbance and 10 = greatest sleep disturbance).<sup>14</sup> For all patients, this assessment was made between 7 and 9 AM on each day of the hospital stay.

#### *Statistical Analysis*

The primary hypothesis of reduction in the incidence of neuropathic pain for the pregabalin treatment group compared with placebo was tested by assessing the incidence of neuropathic pain at 6 months after TKA. An intent-to-treat analysis was applied to all patients consented and randomized for primary and secondary outcomes. A power analysis was performed to determine the sample size required to show a 75% reduction in the incidence of neuropathic pain at 6 months postoperatively; the published 12.7% incidence of neuropathic pain after TKA<sup>4</sup> was set as the control value. By using SAS Statistical Software, we determined that for  $\alpha = 0.05$  and 80% power, using the Pearson  $\chi^2$  1-tailed test for 2 proportions, 97 patients were required in each treatment group. Anticipating that a moderate number of patients would be withdrawn from the study after randomization and the prolonged follow-up time period, we chose 240 patients as our enrollment target.

Demographic and intraoperative data were analyzed with the Student *t*-test,  $\chi^2$  test, or Mann-Whitney-Wilcoxon (MWW) test as appropriate. Descriptive statistics are reported as mean and standard deviation for continuous variables, median and interquartile range for ordinal variables, and count and/or percentages (%) for dichotomous variables. Unless stated otherwise, results are mean  $\pm$  standard deviation. All statistical models were evaluated for assumption deviations and corrected as necessary. Epidural analgesic consumption rate, supplemental postoperative opioid use, KOOS-SP knee score, and time for patients to achieve hospital discharge criteria were compared between the 2 groups using the 2-sample Student *t*-test. All repeated measurement outcomes (active ROM, passive ROM, and sleep interference) were analyzed with a mixed-procedure, repeated-measures model with an autoregressive covariance structure, estimated using the maximum likelihood method. NRS pain scores during a postoperative period up to 42 hours were analyzed, after verifying that less than 20% of the scores were 0, as a repeated measurement outcome and evaluating the distributional assumptions. Although the mixed models used are robust against violations of non-normality, when distributional violations were identified, nonparametric methods were used to confirm parametric results. The incidence of

neuropathic pain (S-LANSS  $\geq$  12), allodynia, or hyperalgesia at 3 and 6 months and adverse events were analyzed by  $\chi^2$  test and confirmed with exact methods.

## Results

Two hundred forty patients were randomly assigned to the 2 treatment groups, with 120 per group (Figure 1). All patients received the preoperative dose, pregabalin or placebo, and all patients were therefore included in the intent-to-treat analysis for the secondary endpoints of the study. An intent-to-treat analysis for the primary outcome (at 6 mo) was performed on 113 and 115 patients, respectively, for the pregabalin and placebo groups. In the pregabalin and placebo groups, 7 and 5 patients, respectively, were lost to follow-up (Figure 1).

Nine patients in the pregabalin group and 2 patients in the placebo group did not receive any postoperative study medication. These 11 patients were included in the intent-to-treat analysis for both the primary and secondary endpoints, where there were data, because a single preoperative dose alone may influence postoperative outcomes. The reasons why the 9 patients in the pregabalin group did not receive any postoperative medication included 4 patients who withdrew consent

**Table 1.** Patient Demographics and Surgical Data

	<b>Pregabalin (n = 120) Mean (SD)</b>	<b>Placebo (n = 120) Mean (SD)</b>	<b>P</b>
Age (y)	64.0 (8.3)	63.3 (8.9)	0.579
Body mass index (kg/m <sup>2</sup> )	34.2 (8.4)	34.6 (7.7)	0.709
	<b>n (%)</b>	<b>n (%)</b>	
<b>Gender (counts)<sup>a</sup></b>			
Female	91 (76%)	84 (70%)	0.309 <sup>a</sup>
Male	29 (24%)	36 (30%)	
	<b>Mean (SD)</b>	<b>Mean (SD)</b>	
Duration of surgery (min)	104 (24)	101 (23)	0.384
Tourniquet time (min)	82 (33)	81 (34)	0.595
Blood loss (mL)	150 (135)	201 (160)	0.065
Total crystalloid (mL)	2320 (625)	2471 (697)	0.123

There were no significant differences between the treatment groups for tested demographic and surgical data.

<sup>a</sup>  $\chi^2$  test

after the operation (1 secondary to sedation), 3 cancellations of the operation (for reasons unrelated to the study protocol), 1 postoperative arrhythmia, and 1 unsuccessful spinal-epidural placement. The reasons for withdrawal in the control group included 1 unsuccessful spinal-epidural placement and 1 patient with severe early postoperative hypotension. Another 4 patients in the pregabalin group and 1 patient in the placebo group received less than 14 days of postoperative study medication and were also included in the intent-to-treat analysis. Demographic characteristics and intraoperative variables were similar between the 2 treatment groups (Table 1).

### Adverse Events

Sedation, confusion, and dry mouth occurred more frequently in the pregabalin group than in the placebo group on the day of the operation and the first postoperative day (Table 2). By postoperative day 2, no adverse event reached statistical significance. There were no falls in this studied population that the investigators observed. No extra physician consults were needed for adverse effects such as sedation. If sedation occurred, we

compensated by reducing the basal epidural analgesic flow rate. At the 6-month postoperative patient visit, there were no clinically significant adverse events in either group.

### Outcome Measures

#### Chronic Neuropathic Pain and Related Outcomes

The incidence of neuropathic pain at 3 and 6 months postoperatively was less frequent in the pregabalin group compared with the placebo group. At 3 months, the incidence of neuropathic pain after TKA was 0% (0 of 113 patients) in the pregabalin group compared with 8.7% (10 of 115) in the placebo group ( $P = 0.001$ ). The incidence of allodynia in the operated leg was also lower ( $P = 0.002$ ) at 3 months for the pregabalin group (2%, 2 of 113) than for the placebo group (12%, 14 of 115); the incidence of hyperalgesia in the operated leg was lower ( $P = 0.009$ ) at 3 months for the pregabalin group (8%, 8 of 113) than for the placebo group (20%, 23 of 115). At 6 months postoperatively, the incidence of neuropathic pain was 0% (0 of 113) in the pregabalin group and 5.2% (6 of 115) in the placebo group ( $P = 0.014$ ). The incidence of allodynia in the

**Table 2.** Incidence of Adverse Events on Day of Surgery (Day 0) and Postoperative Days 1 and 2

	Day 0		Day 1		Day 2	
	Pregabalin n = 120	Placebo n = 120	Pregabalin n = 106	Placebo n = 110	Pregabalin n = 100	Placebo n = 106
Sedation	16 (13%)	4 (3%)	28 (26%)	15 (14%)	15 (15%)	8 (8%)
<i>P</i>		0.005 <sup>a</sup>		0.019 <sup>a</sup>		0.0906
Confusion	6 (5%)	0 (0%)	14 (13%)	4 (4%)	9 (9%)	4 (4%)
<i>P</i>		0.013 <sup>a</sup>		0.011 <sup>a</sup>		0.123
Dizziness	1 (1%)	1 (1%)	18 (17%)	12 (11%)	10 (10%)	8 (8%)
<i>P</i>		1.00		0.197		0.533
Headache	1 (1%)	0 (0%)	3 (3%)	0 (0%)	1 (1%)	0 (0%)
<i>P</i>		0.316		0.076		0.302
Dry mouth	3 (3%)	0 (0%)	7 (7%)	1 (1%)	5 (5%)	3 (3%)
<i>P</i>		0.081		0.027 <sup>a</sup>		0.421
Nausea	9 (8%)	10 (8%)	13 (12%)	16 (15%)	6 (6%)	8 (8%)
<i>P</i>		0.811		0.642		0.659
Vomiting	3 (3%)	3 (3%)	4 (4%)	6 (6%)	1 (1%)	3 (3%)
<i>P</i>		1.00		0.479		0.341
Pruritus	1 (1%)	6 (5%)	4 (4%)	8 (7%)	1 (1%)	3 (3%)
<i>P</i>		0.055		0.262		0.341
Peripheral edema	0 (0%)	0 (0%)	0 (0%)	1 (1%)	0 (0%)	0 (0%)
<i>P</i>		1.00		0.316		1.00
Diplopia	1 (1%)	0 (0%)	1 (1%)	0 (0%)	0 (0%)	0 (0%)
<i>P</i>		0.316		0.323		1.00

<sup>a</sup> There was a statistically significant difference ( $P < 0.05$ ) between groups.

operated leg was also lower ( $P = 0.002$ ) at 6 months for the pregabalin group (0%, 0 of 113) than for the placebo group (8%, 9 of 115); the incidence of hyperalgesia in the operated leg was lower ( $P = 0.006$ ) at 6 months for the pregabalin group (2%, 2 of 113) than for the placebo group (11%, 12 of 115). The neuropathic pain in all 6 patients with an S-LANSS score of 12 or more at 6 months was confirmed by physical examination by the physician. All 6 patients had allodynia and hyperalgesia to touch, and 5 of 6 had abnormal response to pinprick. There was no difference in preoperative pain scores ( $P = 0.343$ ) between the pregabalin group (NRS =  $7.7 \pm 1.9$ ,  $n = 67$ ) and the placebo group (NRS =  $8.0 \pm 1.3$ ,  $n = 66$ ). As for concomitant analgesic use, 32 of 240 patients used NSAIDs during this 6-month postoperative period, 16 in the pregabalin group and 16 in the placebo group ( $P = 1.000$ ). Twenty-four of 240 patients used opioids during this postoperative period, 15 in the pregabalin group and 9 in the placebo group ( $P = 0.282$ ). Eight of 240 patients used gabapentin or pregabalin during this postoperative period, 0 in the pregabalin group and 8 in the placebo group ( $P = 0.007$ ). Twenty-four of 240 patients used acetaminophen/tramadol during this postoperative period, 11 in the pregabalin group and 13 in the placebo group ( $P = 0.830$ ).

The KOOS-PS knee function score (0-100) for patients with chronic pain at 6 months (all 6 in placebo group) was increased,  $49.0 \pm 16.2$ , compared with 6 age-matched pregabalin patients,  $12.4 \pm 5.5$  ( $P = 0.003$ ), and also compared with 6 age-

matched placebo non-chronic-pain patients,  $25.7 \pm 7.2$  ( $P = 0.012$ ).

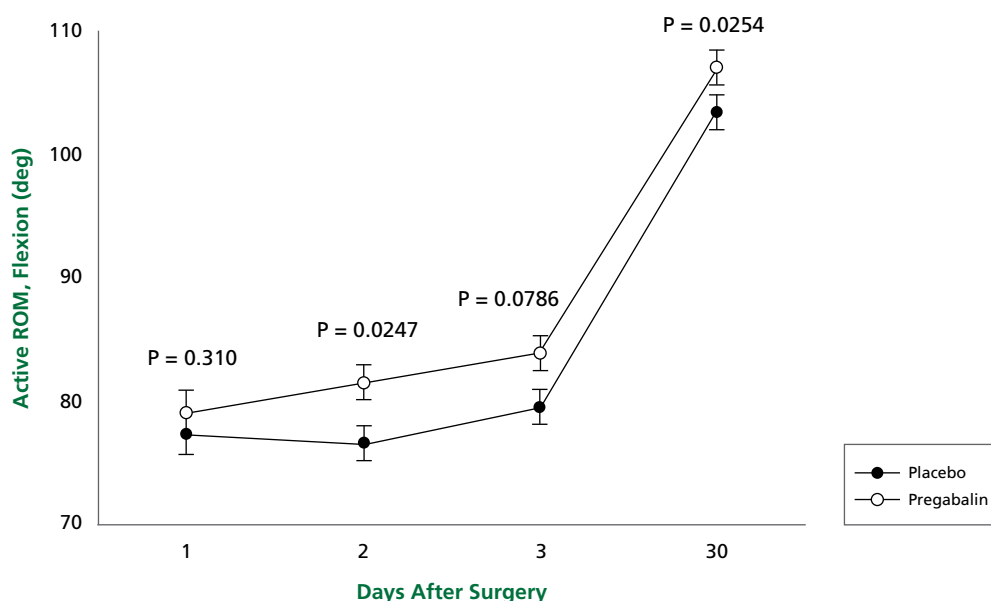
#### Range of Motion

Patients in the pregabalin group had greater active flexion of the operated knee during postoperative days 1-30, compared with placebo patients (mixed model: fixed effect,  $F = 6.23$ ,  $P = 0.013$ ), and change across time was highly significant ( $P < 0.0001$ ) (Figure 2). Passive ROM during postoperative days 1-3 was also improved in the pregabalin group compared with the placebo group (mixed model: fixed effect,  $F = 4.41$ ,  $P = 0.037$ ), and change across time was highly significant ( $P = 0.0013$ ). Passive ROM on day 2 was  $88.9^\circ \pm 9.9^\circ$  in pregabalin patients compared with  $83.7^\circ \pm 15.2^\circ$  in placebo patients ( $P = 0.012$ ).

#### Epidural Drug Use and Pain Assessment

In the immediate postoperative period, epidural drug consumption was less in the pregabalin group ( $5.77 \pm 1.31$  mL/h) than in the placebo group ( $6.40 \pm 1.26$  mL/h;  $P = 0.003$ ). In addition, fewer epidural PCEA boluses were delivered in the pregabalin group (0.36/h [0.21-0.55], median [interquartile range]) than in the placebo group (0.63/h [0.30-0.98]) ( $P = 0.009$ ). However, the frequency of a PCEA bolus is a difficult assessment of pain because a patient taking pregabalin who is sedated will likely not push the button for a bolus. In accordance with the study protocol, the NRS values at rest, during the immediate postoperative phase, did not differ between treatment groups (mixed

**Figure 2.** Active range of motion (ROM) of operated knee over postoperative days 1-30 showing greater flexion in the pregabalin group. Data plotted as mean  $\pm$  SE.



model: fixed effect,  $F = 2.77$ ,  $P = 0.098$ ; and no change across time [ $F = 2.14$ ,  $P = 0.0750$ ]). This is consistent with the instruction given to the study patients to maintain their pain score between 2 and 4 using PCEA bolus doses. However, the NRS values tended to be lower with pregabalin than with placebo at the discharge physical therapy session, during both active ROM ( $5.2 \pm 2.4$  vs  $6.1 \pm 2.4$ ;  $P = 0.059$ ) and passive ROM ( $6.0 \pm 2.3$  vs  $7.0 \pm 2.2$ ;  $P = 0.032$ ) testing. Supplemental postoperative oral opioid use (in morphine equivalents) to control pain for the entire hospital stay was less in the pregabalin group, 4.55 mg (2.40 [SET-MINUS] 9.16), compared with the placebo group, 7.32 mg (4.32 [SET-MINUS] 10.70) ( $P = 0.005$ ). The dosage of metoclopramide and ondansetron used postoperatively by the patients with neuropathic pain at 6 months (all in the placebo group) versus those without pain (all remaining patients combined) did not differ for either metoclopramide ( $P = 0.8099$ ) or ondansetron ( $P = 0.4374$ ).

#### *Time to Meeting Hospital Discharge Criteria*

Patients who were in the pregabalin group met hospital discharge criteria faster than did patients in the control group ( $60.2 \text{ h} \pm 15.8$ ) compared with  $69.0 \text{ h} \pm 16.0$ , respectively;  $P = 0.001$ ). The actual hospital discharge time, however, was not different between the 2 groups (mean time to discharge with pregabalin was  $72.1 \text{ h} \pm 18.8$  compared with  $73.2 \text{ h} \pm 15.6$  with placebo;  $P = 0.702$ ).

#### *Sleep Disturbance*

The pregabalin patients had less sleep interference compared with placebo patients (mixed model: fixed effect,  $F = 4.50$ ,  $P = 0.038$ ), and change across time was highly significant ( $P < 0.0001$ ) while in the hospital. On the first postoperative night, the sleep interference score was  $2.9 \pm 3.3$  for the pregabalin group, compared with  $4.6 \pm 3.2$  for the placebo group (step-down Bonferroni:  $P = 0.035$ ). On each succeeding night, there were no statistical differences between groups.

### **Discussion**

The principal finding from this randomized, placebo-controlled trial of perioperative administration of pregabalin to patients undergoing TKA was a significant decrease in the incidence of chronic neuropathic pain (0% compared with 5.2% in the placebo group) at 6 months after the operation. The reported incidence of chronic neuropathic pain after TKA has varied between 0.8%<sup>20</sup> and 12.7%<sup>4</sup> at 6 months postoperatively. In a recent report on a small number of patients ( $n = 20$ ) undergoing TKA, none of the patients had tactile allodynia, or decreased mechanical or thermal pain thresholds (signs and symptoms of neuropathic pain), but 20% of the patients had moderate chronic pain at 4 months postoperatively.<sup>21</sup> The wide variation in prevalence estimates is likely related to retrospective

study designs, variable criteria for neuropathic pain, or small sample size.<sup>4</sup> Neuropathic pain of the operated knee can result in substantial discomfort and limit activities of daily living. This is the first large prospective clinical trial examining the incidence of chronic neuropathic pain after TKA and defining a strategy to prevent the development of this distressing chronic pain syndrome.

In a similar study, the administration of gabapentin to women undergoing total abdominal hysterectomy did not reduce acute postoperative pain, but there was a decrease in pain at 1 month postoperatively.<sup>22</sup> A preoperative dose of 1200 mg was chosen for that study, and it was repeated daily for the first 7 days postoperatively. In another study of abdominal hysterectomy, gabapentin was given at 1800 mg/day starting 1 hour preoperatively for 72 hours, but long-term pain was not evaluated.<sup>23</sup> Similarly, we designed our study with the intent to prevent spinal cord sensitization by a preoperatively recommended upper-limit dose (300 mg) of pregabalin that was continued for 14 days after the operation (150 mg twice daily for 10 days and then titrated down for another 4 days). Although we chose a 14-day postoperative regimen, the minimum duration or the dose required to prevent the long-term sequelae of spinal cord sensitization after a major surgery such as TKA cannot be determined from this study.

Chronic neuropathic pain is a complex condition that has a profound effect on both quality of life and expenditures for health care.<sup>24</sup> This was evident by the results of our study, demonstrating reduced knee function (higher level of KOOS-PS scores) at 6 months postoperatively in patients with neuropathic pain (in the placebo group of patients) compared with patients without chronic pain. Treatment options for patients who develop neuropathic pain after TKA are challenging and expensive. Patients who undergo repeated TKA for chronic pain of the knee invariably have further exacerbation in knee pain, and in very rare instances, above-knee amputations have been reported.<sup>25</sup>

In a large study of 10 000 patients with osteoarthritis who underwent TKA, a 2-year postoperative survey showed that patients who had persistent pain in the knee had decreased functional improvements.<sup>26</sup> Oral perioperative administration of pregabalin improved active and passive ROM after TKA in our study. ROM is an important measure of outcome after TKA.<sup>27</sup> It has been demonstrated that  $67^\circ$  of knee flexion is needed for the swing phase of gait,  $83^\circ$  to climb stairs,  $90^\circ$  to descend stairs, and  $93^\circ$  to rise from a chair after TKA.<sup>28</sup> Higher degrees of ROM to  $106^\circ$  are required for activities such as shoe tying.<sup>29</sup> The active knee flexion ( $79.5^\circ$ ) attained in our placebo group by day 3 (typical discharge day) is similar to that reported in other studies using postoperative regional analgesia after TKA.<sup>30,31</sup> The pregabalin group, however, demonstrated greater knee



functionality (83.9° active flexion = stair climbing) at discharge. It is likely that this beneficial effect on knee function at time of discharge facilitated attainment of nearly full functionality in the pregabalin group (107.0° active flexion = shoe tying) at 1 month after the operation, versus 103.4° in the placebo group. These beneficial effects have important economic implications for reducing the costs associated with the additional time in physical therapy necessary to achieve full knee function.<sup>32</sup>

The beneficial outcomes associated with pregabalin in this study may be related to preoperative administration of a large initial dose and/or a continued large dose for 10 days after TKA. Our first dose at 1-2 hours before the operation was not intended to be “preemptive analgesia.” Instead, it was to provide coverage immediately after the operation, when it would have been difficult to administer this oral medication. A recent study with the cyclooxygenase-2 inhibitor celecoxib failed to find a benefit to perioperative administration compared with postoperative administration alone.<sup>33</sup> Further studies are needed to assess the benefit, if any, of preoperative administration of pregabalin, given the recent studies questioning its analgesic benefit in the early postoperative period and well-documented side effects.<sup>11-13,34</sup> It has been suggested that aggressive management of early postoperative pain may reduce the likelihood of long-term pain,<sup>35</sup> and this concept has been extended to other operative procedures that are followed by persistent pain.<sup>3</sup> Because our protocol was designed to actively manage acute postoperative pain equally in both the pregabalin and the placebo groups, the reduction in the incidence of long-term postoperative pain after TKA cannot be attributed to amelioration of acute pain. Nevertheless, the ability of pregabalin to reduce short-term central nervous system hypersensitivity in humans<sup>36</sup> makes it likely that early and maintained reduction of neuronal excitability by this drug is one possible mechanism for suppression of long-term neuropathic pain. The mechanism of action of pregabalin probably involves binding to voltage-gated calcium channels,<sup>37</sup> which are upregulated in the dorsal root ganglia and spinal cord in rat neuropathic pain models.<sup>38</sup> The reduction in sleep interference in the pregabalin group may be attributable, in part, to the increased sedation also seen in that group.

There were no statistically significant differences in the actual recorded duration of hospitalization between the 2 groups. With newer treatment strategies for TKA patients, multidisciplinary operational changes are needed to facilitate an earlier discharge from the hospital.<sup>39</sup>

The 300-mg initial pregabalin dose (before the operation), without the slow dose escalation that is standard practice when pregabalin (or gabapentin) is administered for chronic pain, most likely led to the increased incidence of sedation and confusion in the pregabalin-treated patients during the im-

mediate postoperative period. In a study of pregabalin 100 mg given before minor gynecological operations, the incidence of lightheadedness, visual disturbance, and difficulty with walking was more frequent with pregabalin than with placebo at 24 hours after the operation.<sup>11</sup> The 300 mg dose of pregabalin given before the operation produced higher sedation scores at 90 and 120 minutes after elective ambulatory and short-stay operations compared with placebo.<sup>12</sup> When given to reduce shoulder pain after laparoscopic cholecystectomy, 150 mg of pregabalin given preoperatively produced oversedation at the 2-hour time point after the operation compared with placebo.<sup>13</sup> Therefore, lower pregabalin doses should be considered in future studies to minimize such side effects, hopefully maintaining therapeutic efficacy. One of the limitations of this study is the absence of dose-response data. Our initial intent with this study was to establish whether administering pregabalin at this selected high dose was effective in preventing chronic pain. Furthermore, large clinical studies with lower doses and shorter duration are necessary to determine the optimal dose and duration of intervention required to achieve similar results in this and other operational pain models. Although the S-LANSS neuropathic pain ratings are a validated assessment tool,<sup>16</sup> a full clinical examination of all patients enrolled in the study is always preferred. There was no difference in use of NSAIDs, opioids, or acetaminophen/tramadol between the pregabalin and placebo groups in the 6-month postoperative period. Placebo group patients were prescribed more gabapentin or pregabalin during this postoperative period than were the patients in the pregabalin group. Interpretation of this increase in independently prescribed pregabalin for treatment of placebo patients is inconclusive without additional timeline and prescribing information, but it does support the fact that the pregabalin group effect was the result of treatment dosing. Although ondansetron has been shown to produce modest transient analgesia in patients with neuropathic pain,<sup>40</sup> the use of this drug was not increased in patients who did not develop neuropathic pain. Finally, because all of our patients had epidural analgesia, the results of this study may not apply to patients receiving perioperative IV or oral analgesics for TKA.

In summary, this study validates the efficacy of the perioperative use of pregabalin to reduce chronic neuropathic pain after TKA. In addition, pregabalin also shortens the time to achieve effective joint ROM.

### Acknowledgment

This research was supported by a medical school grant from Pfizer, Inc.

## References

- Hootman JM, Helmick CG. Projections of US prevalence of arthritis and associated activity limitations. *Arthritis Rheum*. 2006;54:226-229.
- Healthcare Cost and Utilization Project. 2007 outcomes by patient and hospital characteristics for ICD-9-CM principal procedure code 81.54 Total Knee Replacement. <http://hcupnet.ahrq.gov/Hcupnet.jsp>. Accessed August 21, 2009.
- Kehlet H, Jensen TS, Woolf CJ. Persistent postsurgical pain: risk factors and prevention. *Lancet*. 2006;367:1618-1625.
- Harden RN, Bruehl S, Stanos S, et al. Prospective examination of pain-related and psychological predictors of CRPS-like phenomena following total knee arthroplasty: a preliminary study. *Pain*. 2003;106:393-400.
- Gilron I. Gabapentin and pregabalin for chronic neuropathic and early postsurgical pain: current evidence and future directions. *Curr Opin Anaesthesiol*. 2007;20:456-472.
- Gajraj NM. Pregabalin: its pharmacology and use in pain management. *Anesth Analg*. 2007;105:1805-1815.
- van de Vusse AC, Stomp-van den Berg SG, Kessels AH, Weber WE. Randomised controlled trial of gabapentin in Complex Regional Pain Syndrome type 1. *BMC Neurol*. 2004;4:13-28.
- Hill CM, Balkenohl M, Thomas DW, Walker R, Mathé H, Murray G. Pregabalin in patients with postoperative dental pain. *Eur J Pain*. 2001;5:119-124.
- Mathiesen O, Jacobsen LS, Holm HE, et al. Pregabalin and dexamethasone for postoperative pain control: a randomized controlled study in hip arthroplasty. *Br J Anaesth*. 2008;101:535-541.
- Agarwal A, Gautam S, Gupta D, Agarwal S, Singh PK, Singh U. Evaluation of a single preoperative dose of pregabalin for attenuation of postoperative pain after laparoscopic cholecystectomy. *Br J Anaesth*. 2008;101:700-704.
- Paech MJ, Goy R, Chua S, Scott K, Christmas T, Doherty DA. A randomized, placebo-controlled trial of preoperative oral pregabalin for postoperative pain after minor gynecological surgery. *Anesth Analg*. 2007;105:1449-1453.
- White PF, Tufanogullari B, Taylor J, Klein K. The effect of pregabalin on anxiety and sedation levels: a dose-ranging study. *Anesth Analg*. 2009;108:1140-1145.
- Chang SH, Lee HW, Kim HK, Kim SH, Kim DK. An evaluation of perioperative pregabalin for prevention and attenuation of postoperative shoulder pain after laparoscopic cholecystectomy. *Anesth Analg*. 2009;109:1284-1286.
- Buvanendran A, Kroin JS, Tuman KJ, et al. Effects of perioperative administration of a selective cyclooxygenase-2 inhibitor on pain management and recovery of function after knee replacement: a randomized controlled trial. *JAMA*. 2003;290:2411-2418.
- Recart A, Issioui T, White PF, et al. The efficacy of celecoxib premedication on postoperative pain and recovery times after ambulatory surgery: a dose-ranging study. *Anesth Analg*. 2003;96:1631-1635.
- Bennett MI, Smith BH, Torrance N, Potter J. The S-LANSS score for identifying pain of predominantly neuropathic origin: validation for use in clinical and postal research. *J Pain*. 2005;6:149-158.
- Perruccio AV, Stefan Lohmander L, Canizares M, et al. The development of a short measure of physical function for knee OA KOOS-Physical Function Shortform (KOOS-PS)—an OARSI/OMERACT initiative. *Osteoarthritis Cartilage*. 2008;16:542-550.
- Norkin CC, White DJ. *Measurement of joint movement: a guide to goniometry*. 2nd ed. Philadelphia, PA: FA Davis Company; 1995:142.
- Berger RA, Sanders S, Gerlinger T, Della Valle C, Jacobs JJ, Rosenberg AG. Outpatient total knee arthroplasty with a minimally invasive technique. *J Arthroplasty*. 2005;20(suppl 3):33-38.
- Katz MM, Hungerford DS, Krackow KA, Lennox DW. Reflex sympathetic dystrophy as a cause of poor results after total knee arthroplasty. *J Arthroplasty*. 1986;1:117-124.
- Martinez V, Fletcher D, Bouhassira D, Sessler DI, Chauvin M. The evolution of primary hyperalgesia in orthopedic surgery: quantitative sensory testing and clinical evaluation before and after total knee arthroplasty. *Anesth Analg*. 2007;105:815-821.
- Fassoulaki A, Stamatakis E, Petropoulos G, Siafaka I, Hassiakos D, Sarantopoulos C. Gabapentin attenuates late but not acute pain after abdominal hysterectomy. *Eur J Anaesthesiol*. 2006;23:136-141.
- Gilron I, Orr E, Tu D, O'Neill JP, Zamora JE, Bell AC. A placebo-controlled randomized clinical trial of perioperative administration of gabapentin, rofecoxib and their combination for spontaneous and movement-evoked pain after abdominal hysterectomy. *Pain*. 2005;113:191-200.
- Schmader KE. Epidemiology and impact on quality of life of postherpetic neuralgia and painful diabetic neuropathy. *Clin J Pain*. 2002;18:350-354.
- Isiklar ZU, Landon GC, Tullos HS. Amputation after failed total knee arthroplasty. *Clin Orthop Relat Res*. 1994;299:173-178.
- Baker PN, van der Meulen JH, Lewsey J, Gregg PJ. The role of pain and function in determining patient satisfaction after total knee replacement: data from the National Joint Registry for England and Wales. *J Bone Joint Surg Br*. 2007;89:893-900.
- Chiu KY, Ng TP, Tang WM, Yau WP. Review article: knee flexion after total knee arthroplasty. *J Orthop Surg*. 2002;10:194-202.
- Laubenthal KN, Smidt GL, Kettelkamp DB. A quantitative analysis of knee motion during activities of daily living. *Phys Ther*. 1972;52:34-43.
- Jevsevar DS, Riley PO, Hodge WA, Krebs DE. Knee kinematics and kinetics during locomotor activities of daily living in subjects with knee arthroplasty and in healthy control subjects. *Phys Ther*. 1993;73:229-239.
- Capdevila X, Barthelet Y, Biboulet P, Ryckwaert Y, Rubenovitch J, d'Athis F. Effects of perioperative analgesic technique on the surgical outcome and duration of rehabilitation after major knee surgery. *Anesthesiology*. 1999;91:8-15.
- Wang H, Boctor B, Verner J. The effect of single-injection femoral nerve block on rehabilitation and length of hospital stay after total knee replacement. *Reg Anesth Pain Med*. 2002;27:139-144.
- Worland RL, Arredondo J, Angles F, Lopez-Jimenez F, Jessup DE. Home continuous passive motion machine versus professional physical therapy following total knee replacement. *J Arthroplasty*. 1998;13:784-787.
- Sun T, Sacan O, White PF, Coleman J, Rohrich RJ, Kenkel JM. Premedication with pregabalin 75 or 150 mg with ibuprofen to control pain after day-case gynaecological laparoscopic surgery. *Br J Anaesth*. 2008;100:834-840.
- Jokela R, Ahonen J, Tallgren M, Haanpää M, Korttila K. Premedication with pregabalin 75 or 150 mg with ibuprofen to control pain after day-case gynaecological laparoscopic surgery. *Br J Anaesth*. 2008;100:834-840.
- Katz J, Jackson M, Kavanagh BP, Sandler AN. Acute pain after thoracic surgery predicts long-term post-thoracotomy pain. *Clin J Pain*. 1996;12:50-55.
- Chizh BA, Göhring M, Tröster A, Quartey GK, Schmelz M, Koppert W. Effects of oral pregabalin and aprepitant on pain and central sensitization in the electrical hyperalgesia model in human volunteers. *Br J Anaesth*. 2007;98:246-254.
- Field MJ, Cox PJ, Stott E, et al. Identification of the alpha 2 delta-1 subunit of voltage-dependent calcium channels as a molecular target for pain mediating the analgesic actions of pregabalin. *Proc Natl Acad Sci USA*. 2006;103:17537-17542.
- Luo ZD, Calcutt NA, Higuera ES, et al. Injury type-specific calcium channel alpha 2 delta-1 subunit up-regulation in rat neuropathic pain models correlates with antiallodynic effects of gabapentin. *J Pharmacol Exp Ther*. 2002;303:1199-1205.
- White PF, Kehlet H, Neal JM, Schrickler T, Carr DB, Carli F; Fast-Track Surgery Study Group. The role of the anesthesiologist in fast-track surgery: from multimodal analgesia to perioperative medical care. *Anesth Analg*. 2007;104:1380-1396.
- McCleane GJ, Suzuki R, Dickenson AH. Does a single intravenous injection of the 5HT3 receptor antagonist ondansetron have an analgesic effect in neuropathic pain? A double-blinded, placebo-controlled cross-over study. *Anesth Analg*. 2003;97:1474-1478.

## THE EXPECTED VALUE OF HIP RESURFACING ARTHROPLASTY VERSUS TOTAL HIP ARTHROPLASTY FOR 50-YEAR-OLD PATIENTS WITH OSTEOARTHRITIS OF THE HIP

W. Randall Schultz, MD, MS; James D. Slover, MD, MS; Scott Sporer, MD, MS

Author Affiliations: Department of Orthopedic Surgery, Massachusetts General Hospital, Boston, Massachusetts (Dr Slover); and Department of Orthopedic Surgery, Rush University Medical Center, Chicago, Illinois (Dr Sporer). Dr Schultz is in private practice in Austin, Texas.

Corresponding Author: Scott Sporer, MD, MS, Midwest Orthopaedics at Rush, One Westbrook Corporate Center, Suite 240, Westchester, IL 60154 (scottsporer@gmail.com).

### Introduction

The prevalence of hip arthritis in the United States is expected to increase throughout the next several decades. Total hip arthroplasty (THA) has become a well-accepted surgical option for patients with severe joint arthritis and can provide predictable pain relief and improvement in function. However, past studies have shown decreased long-term survival of total hip arthroplasty in the younger patient population,<sup>1</sup> although recent clinical investigations have shown improved results in this patient group.<sup>2-5</sup> Younger patients require the implant to provide stable function for a longer period of time and also expect to return to a higher level of activity following the joint replacement. These expectations present a unique set of challenges for the orthopedic surgeon, and hip resurfacing arthroplasty (HRA) has emerged as an alternative to conventional total hip arthroplasty in the younger patient in an attempt to address these issues.

Hip resurfacing arthroplasty preserves bone in the proximal femur by resurfacing rather than replacing the femoral head. It has several theoretical advantages over conventional THA. The greatest advantage of HRA is proximal femoral bone preservation. If a femoral-sided failure is encountered, a femoral neck osteotomy can be performed at a level similar to that of a primary THA. This may allow a surgeon to reconstruct the femoral side with primary implants rather than the revision components frequently required with revision of a conventional THA, which could lead to superior results.<sup>6</sup> A second advantage of HRA is proximal stress transfer to the femoral neck. This may preserve additional proximal bone and avoid problems of stress shielding seen with intramedullary stems that obtain distal fixation. Preservation of proximal bone may be especially important in a young patient population, where many patients will require a future revision procedure. HRA simulates a more physiologic loading of the proximal femur and may provide improved proprioception compared with THA. HRA also allows the use of a larger femoral head, which may help minimize the risk of postoperative dislocation.

HRA also has several disadvantages as compared to conventional THA. Several early-generation resurfacing procedures demonstrated dismal results with metal-on-polyethylene bearings due to the high volumetric wear.<sup>7,8</sup> The success of metal-on-metal bearings and the development of hip resurfacing implants using this type of bearing have once again made HRA an option for surgically treating arthritis in this population.<sup>9</sup> However, one reason for the hesitation to use HRA for our patients today is the paucity of long-term results. The early (8-year) results are promising, but long-term outcomes are unknown. HRA also has other disadvantages as compared to THA.

One potential failure mechanism unique to HRA is the risk of femoral neck fracture. The prevalence of femoral neck fracture is estimated between 0% and 4%.<sup>10-12</sup> Additional concerns regarding current-generation resurfacing procedures include the increased metal ion levels in patients' blood and urine believed to be secondary to the metal-on-metal articulation.<sup>13,14</sup> The long-term effect of elevated metal ion levels is unknown, but delayed hypersensitivity reactions, renal failure, and malignancy are potential concerns.<sup>15,16</sup>

Given the real and theoretical advantages and disadvantages of both THA and HRA, the ideal surgical procedure for addressing end-stage arthritis in the young patient population remains unknown. This study used a Markov decision analysis model to determine whether currently available data support the concept of HRA by assessing the expected value of the average quality-of-life gain obtained with each treatment option.

## Methods

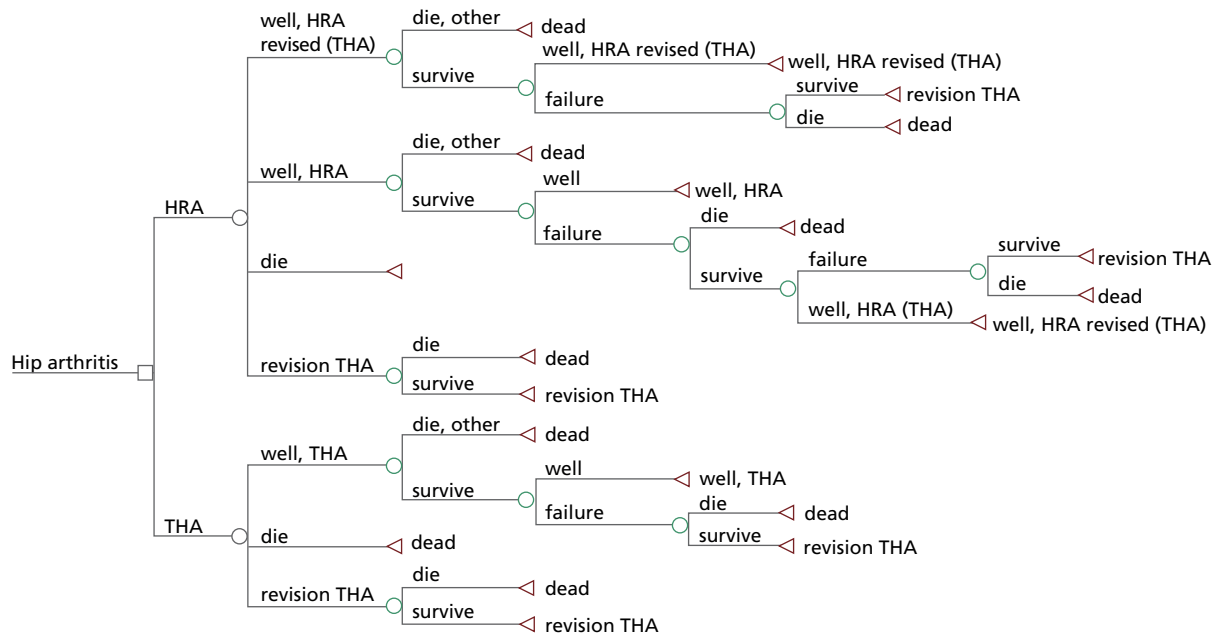
### Patient Population

We evaluated a theoretical cohort of 50-year-old patients, meant to simulate young patients with arthritis of the hip for which nonsurgical management was unsuccessful. All patients were assumed to have no contraindications to THA or HRA.

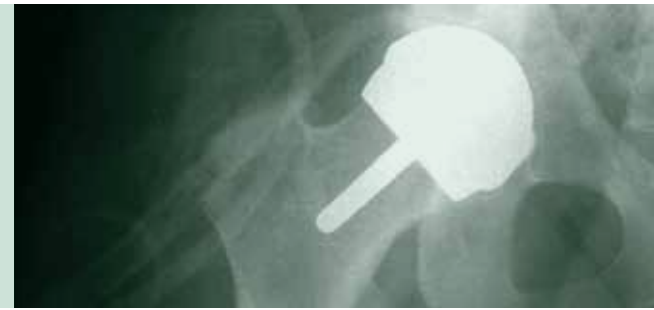### Model Design

A Markov decision model was used to determine whether THA or HRA is most effective for the management of hip arthritis in a young population in need of hip arthroplasty surgery. A utility value was assigned to every health state in the model (Figure 1). Utilities, which represent how health states are valued, are measured in quality-adjusted life-years (QALYs). Patients transition between health states at an age-dependent frequency determined by specific transition probabilities. The methods used to obtain the transition probabilities associated

**Figure 1.** The Markov model used to model patients with end-stage arthritis of the hip. Each patient receives a total hip arthroplasty (THA) or hip resurfacing arthroplasty (HRA). Patients who survive the operation stay well until they die from other causes or need a revision. Patients who have a revision and survive are assumed to stay well with that revision until they die from other causes. The model continues until all patients reach death.



“The results of this expected-value analysis indicate an improved average expected quality of life for 50-year-old patients who choose HRA for treatment of osteoarthritis of the hip based on the best data presently available.”



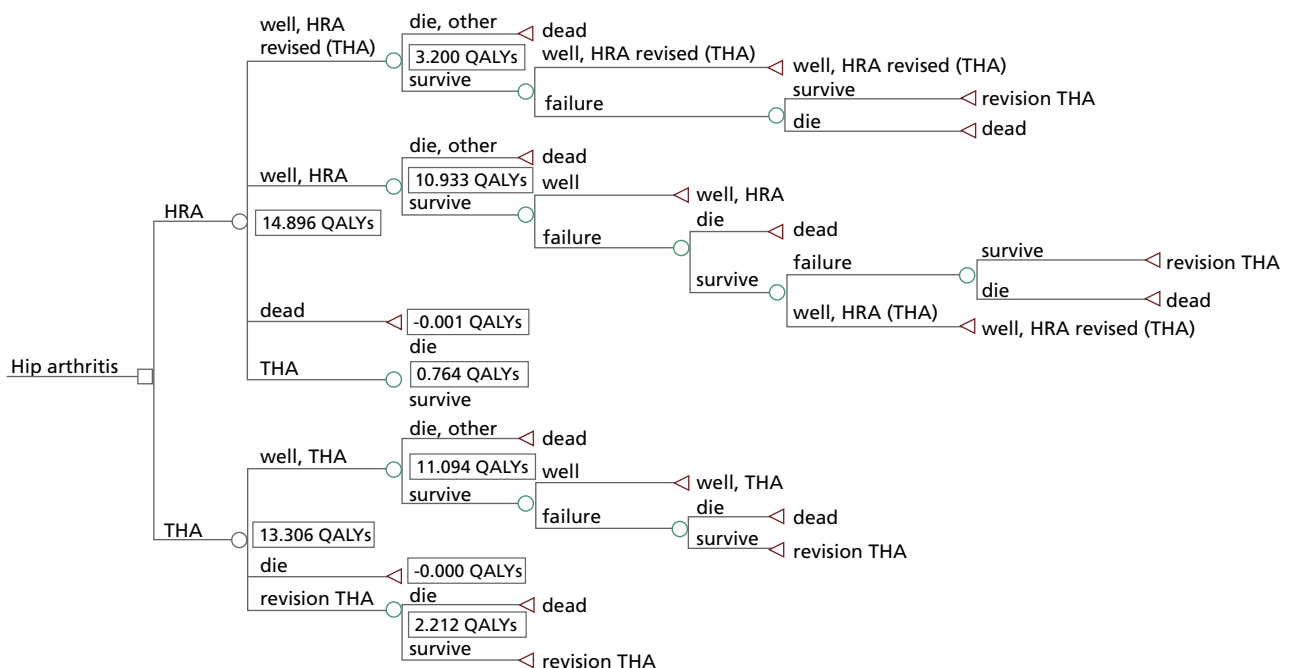
with changing health states, including the probability of revision and the probability of death, are explained in detail below. The theoretical patient cohort accumulates utilities that are used to estimate the total accumulated QALYs for each patient over time. After completion of the model, the total tabulated QALYs are used to evaluate the effectiveness of the THA and HRA strategies. The treatment with the greatest accumulated QALY value was deemed to provide the greatest long-term benefit for the cohort of patients. All utilities incurred after time 0 are discounted at a rate of 3% per year to be consistent with current practices of outcome analysis in medicine.<sup>17</sup> The model was

constructed using decision analysis software (TreeAge Pro 2007, Williamstown, Massachusetts).

### Model Parameters

The following general assumptions were made in constructing the model: (1) patients undergoing a successful THA or HRA have the same utility, or QALY value, after the initial postoperative period; (2) patients receiving THA receive an uncemented prosthesis, which is more commonly used for young, active arthroplasty patients; (3) patient mortality rates after surviving a hip arthroplasty operation are not different than the

**Figure 2.** Results of the Markov model for the base case. A patient in the hip resurfacing arthroplasty (HRA) group obtains an average of 14.90 quality-adjusted life-years (QALYs), whereas a patient in the total hip arthroplasty (THA) group obtains an average of 13.31 QALYs.



age-adjusted mortality rate of a patient in the United States who has not had a hip arthroplasty; (4) patients undergo only a single revision procedure and then remain in the “well with revision” health state until death; and (5) revision of HRA will be a THA. The parameter values used in the decision model (Figure 1) are shown in Table 1 and are individually described in further detail below.

### Arthroplasty Survival Rates

Data from the 2005 Swedish Hip Arthroplasty Register were used to estimate the probability of revision of an uncemented THA. These data were used to set the annual probability of revision of a primary THA for patients in the model equal to the annual probability of revision of an uncemented THA in the Swedish Hip Arthroplasty Register for a large cohort of patients all under the age of 50 at the time of their primary procedure, for years 1 through 12.<sup>18</sup> To estimate the failure rate beyond 12 years, we set the annual revision rate to 1% per year. The implant survival rates for THAs at 5, 10, 15, and 20 years in the model using these methods for determining the annual probability of revision are shown in Table 2. The probability of revision of a primary HRA was set relative to the probability of revision of an uncemented THA in the same population. Data from the Australian National Joint Replacement Registry show

that the cumulative revision rate of primary HRA is 1.25 times the revision rate of primary THA in the same patient population, with the 4-year cumulative revision rate equaling 3.02% for patients undergoing HRA and 2.4% for patients undergoing primary THA.<sup>11</sup> Therefore, we set the annual probability of revision for HRA at 1.25 times the annual rate, as determined from Swedish Hip Arthroplasty Register<sup>8</sup> data, for the base case.

### Mortality Rates

The age-specific probability of death from causes unrelated to hip replacement was made equal to the probability of death at each specific age and was taken from the 2001 United States Life Tables.<sup>19</sup> The probability of perioperative death was estimated from a Medicare study of 61 568 primary THAs and 13 483 revision THAs, which found 90-day mortality rates of 1.0% and 2.6% respectively.<sup>20</sup> We assumed the probability of perioperative death was the same for a primary or revision HRA as for a primary or revision THA for the base case.

### Outcome Parameters (Utilities)

Patients undergoing THA or HRA were assumed to have the same health utility value after the immediate postoperative period had passed and rehabilitation was complete. To date, the utility of HRA remains to be clearly defined. However, several

**Figure 3.** Sensitivity analysis examining the effect of varying the utility (in quality-adjusted life-years, or QALYs) of hip resurfacing arthroplasty (HRA) and the utility (in QALYs) of total hip arthroplasty (THA). Green shading indicates where THA is the favored procedure; blue indicates where HRA is favored. The red line is where the utility of HRA equals the utility of THA.

**Figure 4.** Sensitivity analysis examining the effect of varying the utility (in quality-adjusted life-years, or QALYs) of hip resurfacing arthroplasty (HRA) and the utility (in QALYs) of a revision of HRA to a total hip arthroplasty (THA). Green shading indicates where THA is the favored procedure; blue indicates where HRA is favored.

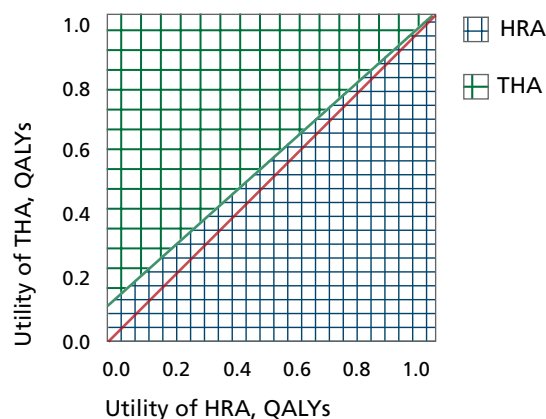


Figure 3

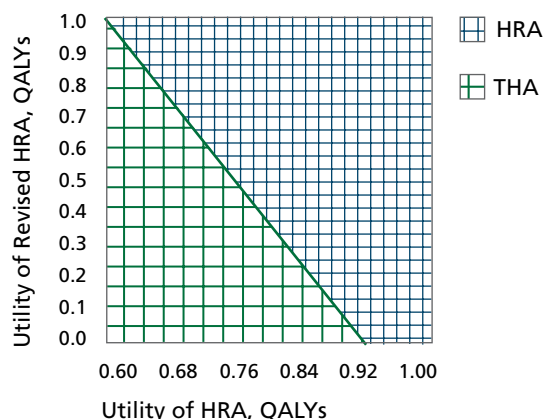


Figure 4

studies have shown similar or improved functional results after HRA, making this assumption justified.<sup>21-24</sup> Utilities used in the model were based on scores for joint arthroplasty reported in the literature.<sup>25</sup> The utility value after a primary THA or HRA was set at 0.73.<sup>26</sup> This is similar to values recently reported for hip arthroplasty in the Swedish Hip Arthroplasty Register. Recent studies have shown that patients undergoing a revision of HRA to THA have equivalent outcomes to primary THA patients in the short term.<sup>6</sup> Therefore, we set the utility value of a revised HRA to 0.70, just below the value of a primary THA. Studies have shown that the results of revision THA are poorer than the results of a primary procedure.<sup>27</sup> Furthermore, a study of 609 hip revision patients found the mean utility value, measured by EuroQol EQ-5D scores, to be 0.62 at 1 year.<sup>28</sup> For this analysis, the utility value after the revision of a THA was assigned an initial value of 0.60.

Disutilities represent the negative preference patients have for a particular health state or outcome. In this model, disutilities represent the decreased preference patients have for the temporary health state associated with undergoing a primary or revision hip arthroplasty procedure, including all of its perioperative morbidity and recovery. The disutility accounts for the decreased mobility, increased pain, and potential complications that are incurred during the perioperative period. Disutilities are assessed at the time a patient undergoes any procedure within the model (acute procedure toll). The disutilities of having THA, HRA, and revision arthroplasty were included in the model as

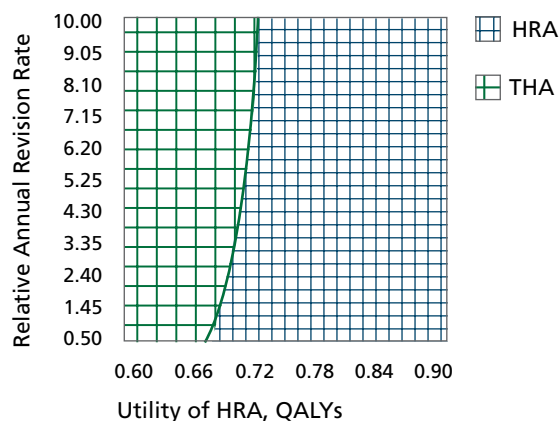
a decrement in QALYs assigned to the patient's total QALY count. The disutility of having THA or HRA was set at  $-0.1$ . This is equivalent to losing 0.1 year (just over 5 weeks) of perfect health. Revision, which has been shown to have a much higher complication rate and recovery time than a primary procedure, was assessed a disutility of  $-0.2$  QALYs, which is double that of a primary THA or HRA, for both HRA and THA patients in the model.

### Analysis

In this study, the difference in the total accumulated QALYs for the THA and HRA treatment options is tabulated over a 20-year period to determine the expected value of each treatment option. The expected value represents the average number of accumulated QALYs for patients in each group, with a higher number of QALYs representing a better average outcome. As noted above, future utilities were discounted at 3% to be consistent with current practices in outcome analysis.<sup>17</sup>

Sensitivity analysis is a test of the stability of conclusions that is conducted by varying a variable or variables over a stated range and evaluating the effect of this variation on the outcome of the model. In this study, two-way sensitivity analyses were used to examine the relationships of the parameters and transition probabilities with the outcome of the model, in this case the expected utility value, measured by accumulated QALYs, of each procedure.

**Figure 5.** Sensitivity analysis examining the effect of varying the utility (in quality-adjusted life-years, or QALYs) of hip resurfacing arthroplasty (HRA) and the relative annual revision rate (RARR) of resurfacing compared with total hip arthroplasty (THA). For example, if the RARR is 2, the revision rate of primary HRA is assumed to be twice the revision rate of primary THA. If the RARR is 0.5, the revision rate of primary HRA is assumed to be half the revision rate of primary THA. Green shading indicates where THA is the favored procedure; blue indicates where HRA is favored.



**Figure 5**

## Results

For the base case, the model found that the average number of QALYs obtained by a patient in the HRA group is 14.90, compared with 13.31 for a patient in the THA group (Figure 2). Therefore, HRA provides the greatest expected gain in average QALYs for the base case.

Sensitivity analysis was used to examine the impact of varying the utility values used in the model and revision rates on the effectiveness, measured by the total accumulated QALYs, of the hip resurfacing and total hip arthroplasty strategies. Figure 3 demonstrates that as the utility of THA decreases, HRA becomes the more favored option. Likewise, as the utility of HRA decreases, THA becomes the more favored option. Figure 4 demonstrates that if the utility value of HRA is greater than 0.92, HRA is the favored treatment strategy regardless of the outcome of revisions. In addition, if the utility value of HRA is

0.8, the utility of revision of HRA can be as low as 0.38 for HRA to be the preferred strategy. Figure 5 illustrates the impact of varying the relative annual revision rate of HRA. As the revision rate increases, the utility of HRA must also increase for HRA to remain the favored strategy.

## Discussion

This study uses Markov decision analysis techniques to analyze whether HRA is a viable strategy in the absence of long-term follow-up data. The results of this expected-value analysis indicate an improved average expected quality of life for 50-year-old patients who choose HRA for treatment of osteoarthritis of the hip based on the best data presently available. Although these results make long-term predictions based on shorter-term data, they do suggest that HRA may lead to a better quality of life for these patients over the long term, and that this

**Table 1.** Model Parameters Used for Base Case

Parameter	THA	Revision THA	HRA	HRA Revision (THA)
<b>Transition Probabilities</b>				
Perioperative death	0.01	0.026	0.01	0.026
<b>Outcome Data</b>				
Utility (QALYs)	0.73	0.6	0.73	0.70
Disutility (acute procedure toll, QALYs)	-0.1	-0.2	-0.1	-0.2

Abbreviations: THA, total hip arthroplasty; HRA, hip resurfacing arthroplasty; QALY, quality-adjusted life-year.

**Table 2.** Implant Survival Rates Used in Model for Total Hip Arthroplasty and Hip Resurfacing Arthroplasty

Time	THA Implant Survival <sup>a</sup>	HRA Implant Survival <sup>a</sup>
5 years	97%	96.25%
10 years	86%	82.50%
15 years	78%	72.50%
20 years	73%	66.75%

Abbreviations: THA, total hip arthroplasty; HRA, hip resurfacing arthroplasty.

<sup>a</sup> Implant survival rates are determined from the Swedish Hip Arthroplasty Register and the techniques described in the "Methods" section. The revision rate for HRA was estimated to be 1.25 times that for THA, based on early results from the Australian National Joint Replacement Registry, as described in the "Methods" section.



treatment strategy merits future study. Long-term follow-up data will be necessary to definitively determine the effectiveness of HRA in younger patients, but until such data are available, predictive modeling allows us to formally quantify the currently known data, gives us an estimation of future outcome, and allows us to educate our patients based on the best currently available scientific and statistical data.

Among the limitations of this analysis, perhaps the most significant is the lack of long-term follow-up data on HRA. Although data have been published approaching 10 years of follow-up,<sup>29-31</sup> these numbers are relatively small and broad conclusions cannot be drawn. Thus, the revision rates in this model for HRA were compared to THA over a 4-year period and held constant relative to the THA revision rate at this ratio over the life span of the implant. An argument can be made that the registry data on revisions may be artificially high for either implant given the improved performance of metal-on-metal bearings in lab testing with regard to wear rates as compared with conventional metal-on-polyethylene bearings.<sup>32-36</sup> Consequently, as continued long-term follow-up reveals more accurate revision rates for these implants, the analysis and conclusions may change. Figure 5 illustrates that as the revision rate increases, the utility of HRA must also increase for HRA to be the favored strategy. However, the effect of increasing the revision rate is minimal, and provided that the utility value of HRA is greater than or equal to the utility value of THA (0.73), HRA appears to be favored regardless of the relative annual revision rate, as long as the utility of a revision of HRA is greater than 0.7. This indicates that the utility values associated with THA, HRA, revision of THA, and revision of HRA appear to be more important factors than the revision rates associated with each procedure.

This model does not take gender into account, although revision rates for HRA are considerably higher in women than in men.<sup>37</sup> This model also does not account for the nature of the hip pathology that led to either of the two treatment options. The effect of these omissions is not known, although it is possible that patients with the most severe hip disease were not selected for HRA, thus presenting a source of potential bias when considering the outcome of HRA. For this reason, we elected to set the outcome of HRA equal to that of THA despite the literature suggesting that HRA results in better functional outcome when compared to THA.<sup>6,24</sup> Figure 3 demonstrates the impact of varying the outcome of each procedure. As expected, it shows that as the utility value of THA or HRA increases, the likelihood of that procedure producing the highest average expected gain in QALYs also increases. Interestingly, it also demonstrates that HRA is favored in all cases where the utility value of the two procedures is equal, as we assumed for the base

case. This is due to the improved outcome of revisions of HRA, which have been shown to be similar to primary THA outcomes in the short term.

Figure 4 demonstrates that if the utility associated with HRA is 0.73, the equivalent value of THA as we assumed in our analysis, then the utility of a revised HRA must be greater than 0.7 for HRA to be the preferred option. However, if the utility value of HRA is 0.8, which represents a 10% improvement in outcome compared with THA, then the utility of HRA revision can be as low as 0.38 for HRA to be the preferred strategy. Furthermore, if the utility of HRA is greater than 0.92, HRA is the preferred strategy regardless of the utility of revised HRA. These findings will be important to understand as more information regarding the outcomes of THA and HRA in this patient population becomes available, and they highlight the need to determine the utility values associated with each of these procedures over time.

This model also does not incorporate the disutility of femoral neck fracture associated with a failed HRA, which is the most common cause of revision in the short term. We have assumed that this short-term deterioration in health state would be similar to that of the patients awaiting revision of a failed THA, who experience the disability associated with such factors as recurrent dislocation, infection, leg length discrepancy, or loose components.

The resurgence of HRA has drawn much attention in the orthopedic community and among young, active patients with hip arthritis. Most initial studies citing the benefit of HRA report significant improvements in activity level, biomechanics, and bone conservation.<sup>12,21,22,29,31,38,39</sup> This study demonstrates that the greatest value in terms of patient quality of life may lie in the improved quality of life experienced with revisions of HRA, which can have results similar to primary THA in the short term,<sup>6</sup> compared with the relatively poorer quality of life associated with revisions of conventional THA. These results are largely contingent upon the assumption that survival rates of HRA will continue at rates similar to the current short-term survival trends and also are contingent upon the outcome data for primary and revision THA and HRA. Consequently, further studies examining the health utility and precise long-term survival rates of primary and revision THA and HRA are necessary.

In conclusion, this analysis demonstrates that the current data suggest an improved quality-of-life outcome for younger patients who elect to undergo HRA rather than THA. This analysis cannot replace data obtained from large, randomized trials or arthroplasty registry studies, but results from those types of studies will not be available for many years. In their absence, this analysis provides evidence that the currently available data support HRA as a treatment strategy in the younger patient

population with end-stage hip osteoarthritis. Therefore, based on presently available data, HRA appears to be a viable option in the treatment of hip osteoarthritis in male patients of 50 years of age.

## References

1. Dorr LD, Lockett M, Conaty JP. Total hip arthroplasties in patients younger than 45 years: a nine- to ten-year follow-up study. *Clin Orthop Relat Res.* 1990;(260):215-219.
2. Eskelinen A, Remes V, Helenius I, Pulkkinen P, Nevalainen J, Paavolainen P. Total hip arthroplasty for primary osteoarthritis in younger patients in the Finnish arthroplasty register: 4,661 primary replacements followed for 0-22 years. *Acta Orthop.* 2005;76(1):28-41.
3. Kerboul L, Hamadouche M, Courpied JP, Kerboul M. Long-term results of Charnley-Kerboul hip arthroplasty in patients younger than 50 years. *Clin Orthop Relat Res.* 2004;(418):112-118.
4. Kearns SR, Jamal B, Rorabeck CH, Bourne RB. Factors affecting survival of uncemented total hip arthroplasty in patients 50 years or younger. *Clin Orthop Relat Res.* 2006;453:103-109.
5. McAuley JP, Szuszczewicz ES, Young A, Engh CA Sr. Total hip arthroplasty in patients 50 years and younger. *Clin Orthop Relat Res.* 2004;(418):119-125.
6. Ball ST, Le Duff MJ, Amstutz HC. Early results of conversion of a failed femoral component in hip resurfacing arthroplasty. *J Bone Joint Surg Am.* 2007;89(4):735-741.
7. Howie DW, Campbell D, McGee M, Cornish BL. Wagner resurfacing hip arthroplasty: the results of one hundred consecutive arthroplasties after eight to ten years. *J Bone Joint Surg Am.* 1990;72(5):708-714.
8. Schmalzried TP, Fowble VA, Ure KJ, Amstutz HC. Metal on metal surface replacement of the hip: technique, fixation, and early results. *Clin Orthop Relat Res.* 1996;(329)(suppl):S106-S114.
9. Schmalzried TP. The optimal metal-metal arthroplasty is still a total hip arthroplasty: in opposition. *J Arthroplasty.* 2006;21(4)(suppl 1):77-79.
10. Shimmin AJ, Back D. Femoral neck fractures following Birmingham hip resurfacing: a national review of 50 cases. *J Bone Joint Surg Br.* 2005;87(4):463-464.
11. Australian Orthopaedic Association National Joint Replacement Registry Annual Report 2006. <http://www.dmac.adelaide.edu.au/aoanjrr/publications.jsp>. Published October 2006. Accessed February 2008.
12. Mont MA, Ragland PS, Etienne G, Seyler TM, Schmalzried TP. Hip resurfacing arthroplasty. *J Am Acad Orthop Surg.* 2006;14(8):454-463.
13. Clarke MT, Lee PT, Arora A, Villar RN. Levels of metal ions after small- and large-diameter metal-on-metal hip arthroplasty. *J Bone Joint Surg Br.* 2003;85(6):913-917.
14. Brodner W, Bitzan P, Meisinger V, Kaider A, Gottsauner-Wolf F, Kotz R. Serum cobalt levels after metal-on-metal total hip arthroplasty. *J Bone Joint Surg Am.* 2003;85-A(11):2168-2173.
15. Tharani R, Dorey FJ, Schmalzried TP. The risk of cancer following total hip or knee arthroplasty. *J Bone Joint Surg Am.* 2001;83-A(5):774-780.
16. Willert HG, Buchhorn GH, Fayyazi A, et al. Metal-on-metal bearings and hypersensitivity in patients with artificial hip joints: a clinical and histomorphological study. *J Bone Joint Surg Am.* 2005;87(1):28-36.
17. Gold MR, Franks P, McCoy KI, Fryback DG. Toward consistency in cost-utility analyses: using national measures to create condition-specific values. *Med Care.* 1998;36(6):778-792.
18. Swedish Hip Arthroplasty Register. *Swedish Hip Arthroplasty Register Annual Report 2006.* <http://www.jru.orthop.gu.se>. Published August 2007. Accessed February 2008.
19. Arias E. *United States Life Tables, 2001.* Washington, DC: Centers for Disease Control and Prevention, US Dept of Health and Human Services; 2004.
20. Mahomed NN, Barrett JA, Katz JN, et al. Rates and outcomes of primary and revision total hip replacement in the United States Medicare population. *J Bone Joint Surg Am.* 2003;85-A(1):27-32.
21. Mont MA, Rajadhyaksha AD, Hungerford DS. Outcomes of limited femoral resurfacing arthroplasty compared with total hip arthroplasty for osteonecrosis of the femoral head. *J Arthroplasty.* 2001; 16(8)(suppl 1):134-139.
22. Pollard TC, Baker RP, Eastaugh-Waring SJ, Bannister GC. Treatment of the young active patient with osteoarthritis of the hip: a five- to seven-year comparison of hybrid total hip arthroplasty and metal-on-metal resurfacing. *J Bone Joint Surg Br.* 2006;88(5):592-600.
23. Vail TP, Mina CA, Yergler JD, Pietrobon R. Metal-on-metal hip resurfacing compares favorably with THA at 2 years followup. *Clin Orthop Relat Res.* 2006;453:123-131.
24. Vendittoli PA, Lavigne M, Roy AG, Lusignan D. A prospective randomized clinical trial comparing metal-on-metal total hip arthroplasty and metal-on-metal total hip resurfacing in patients less than 65 years old. *Hip Int.* 2006;16(suppl 4):73-81.
25. Laupacis A, Bourne R, Rorabeck C, et al. The effect of elective total hip replacement on health-related quality of life. *J Bone Joint Surg Am.* 1993;75(11):1619-1626.
26. Ethgen O, Bruyère O, Richy F, Dardennes C, Reginster JY. Health-related quality of life in total hip and total knee arthroplasty: a qualitative and systematic review of the literature. *J Bone Joint Surg Am.* 2004; 86-A(5):963-974.
27. Hozack WJ, Rothman RH, Albert TJ, Balderston RA, Eng K. Relationship of total hip arthroplasty outcomes to other orthopaedic procedures. *Clin Orthop Relat Res.* 1997;(344):88-93.
28. Dawson J, Fitzpatrick R, Frost S, Gundle R, McLardy-Smith P, Murray D. Evidence for the validity of a patient-based instrument for assessment of outcome after revision hip replacement. *J Bone Joint Surg Br.* 2001; 83(8):1125-1129.
29. Amstutz HC, Ball ST, Le Duff MJ, Dorey FJ. Resurfacing THA for patients younger than 50 years: results of 2- to 9-year followup. *Clin Orthop Relat Res.* 2007;460:159-164.
30. Revell MP, McBryde CW, Bhatnagar S, Pynsent PB, Treacy RB. Metal-on-metal hip resurfacing in osteonecrosis of the femoral head. *J Bone Joint Surg Am.* 2006;88(suppl 3):98-103.
31. Treacy RB, McBryde CW, Pynsent PB. Birmingham hip resurfacing arthroplasty: a minimum follow-up of five years. *J Bone Joint Surg Br.* 2005;87(2):167-170.
32. Dorr LD, Long WT. Metal-on-metal: articulations for the new millennium. *Instr Course Lect.* 2005;54:177-182.
33. Fisher J, Jin Z, Tipper J, Stone M, Ingham E. Tribology of alternative bearings. *Clin Orthop Relat Res.* 2006;453:25-34.
34. Heisel C, Silva M, Schmalzried TP. Bearing surface options for total hip replacement in young patients. *Instr Course Lect.* 2004;53:49-65.
35. Schmalzried TP, Silva M, de la Rosa MA, Choi ES, Fowble VA. Optimizing patient selection and outcomes with total hip resurfacing. *Clin Orthop Relat Res.* 2005;441:200-204.
36. Silva M, Heisel C, Schmalzried TP. Metal-on-metal total hip replacement. *Clin Orthop Relat Res.* 2005;(430):53-61.
37. Beaulé PE, Dorey FJ, LeDuff M, Gruen T, Amstutz HC. Risk factors affecting outcome of metal-on-metal surface arthroplasty of the hip. *Clin Orthop Relat Res.* 2004;(418):87-93.
38. Loughhead JM, Chesney D, Holland JP, McCaskie AW. Comparison of offset in Birmingham hip resurfacing and hybrid total hip arthroplasty. *J Bone Joint Surg Br.* 2005;87(2):163-166.
39. Silva M, Lee KH, Heisel C, Dela Rosa MA, Schmalzried TP. The biomechanical results of total hip resurfacing arthroplasty. *J Bone Joint Surg Am.* 2004;86-A(1):40-46.

## WEAR MECHANISMS IN METAL-ON-METAL BEARINGS: THE IMPORTANCE OF TRIBOCHEMICAL REACTION LAYERS

Markus A. Wimmer, PhD;  
Alfons Fischer, PhD; Robin  
Büscher, PhD; Robin  
Pourzal, MS; Christoph  
Sprecher, MS; Roland  
Hauert, PhD; Joshua J.  
Jacobs, MD

Author Affiliations: Department of Orthopedic Surgery, Rush University Medical Center, Chicago, Illinois (Drs Wimmer and Jacobs); Materials Science and Engineering II, University of Duisburg-Essen, Duisburg, Germany (Drs Fischer and Büscher and Mr Pourzal); AO Research Institute, AO Foundation, Davos, Switzerland (Mr Sprecher); and Swiss Federal Laboratories for Materials Testing and Research, Dübendorf, Switzerland (Dr Hauert).

Corresponding Author: Markus A. Wimmer, PhD, Rush University Medical Center, 1611 W Harrison St, Suite 205, Chicago, IL 60612 (markus\_a\_wimmer@rush.edu).

Previous Publication: This article was previously published in the *Journal of Orthopedic Research* (2010;28[4]:436-443). Minor edits have been made.

### Introduction

Replacement of the arthritic or traumatized hip joint is a routinely performed procedure. Because of an aging population and the extension of the procedure to younger patients, technological and surgical aspects of joint replacement strategies are continually reviewed and advanced. Hip resurfacing arthroplasty has regained significant popularity in recent years, combining the preservation of bone stock and a reduced risk of dislocation with a contemporary, low-wearing metal-on-metal (MoM) joint articulation.<sup>1</sup> Hip resurfacing has increased the popularity of the MoM articulation. For example, hip resurfacing accounts already for 7.5% of all hip replacements in Australia.<sup>2</sup> Thus, the MoM market share of 9.1% worldwide (April 2009 internal estimation of Zimmer GmbH, Winterthur, Switzerland) will be growing. A cause for concern with MoM joints, however, has been systemic metal ion release. Despite today's very low wear rates, ranging from 0.5 to 2.5  $\mu\text{m}/\text{year}$ ,<sup>3,5</sup> increased ion levels in serum compared with other established bearing combinations are observed.<sup>6</sup> Metal ion release, which can form metal-protein complexes,<sup>7</sup> and the generation of nanoscopic wear debris<sup>8-10</sup> raise concerns regarding particle-induced osteolysis, perivascular lymphocytic tissue responses, and metal hypersensitivity.<sup>11-14</sup>

Considerable progress has been made in understanding and controlling manufacturing variables, such as alloy composition, bearing diameter, design and clearance tolerances, and surface finish. Further wear reductions will only be possible if underlying wear mechanisms are better understood. In vitro<sup>15</sup> and retrieval<sup>16</sup> studies found that the governing wear mechanisms are not adhesion and abrasion as in other bearings, but predominantly tribochemical reactions (TCRs) and surface fatigue. TCRs occur when the surfaces of 2 contacting metal bearings react with the interfacial medium (eg, synovial fluid), resulting in the alternating formation and removal of chemical reaction products at the surfaces.<sup>17</sup> The observed nanometer-sized wear debris must stem from the uppermost tribochemically transformed zone; otherwise, small wear rates would be impossible. Indeed, when observed using transmission electron microscopy (TEM), the top surface layer can be seen to recrystallize to nanometer grain sizes.<sup>18</sup> The interplay between lubricant and the nanocrystalline surface layer is not well defined. An investigation into this interaction is critical because TCRs affect the composition of the layer and determine its mechanical and chemical properties (and thus stability). Our purpose was to provide a better understanding of

TCRs in MoM joints by virtue of chemical and microstructural analyses of retrieved MoM bearing couples.

## Materials and Methods

### Samples

This chemical and microstructural investigation of TCR layers is based on the same MoM retrieval collection described in earlier studies.<sup>16,18,19</sup> Briefly, the collection consists of 42 retrieved McKee-Farrar prostheses from 5 manufacturers worn by 14 male and 28 female patients. All prostheses were implanted and retrieved by a single surgeon.<sup>20</sup> The average patient age at implantation was 61 years (range, 38-82 years), and the prostheses lasted for 13.6 years (range, 1.3-22 years). None of the components (acetabular cup or femoral stem) was removed for excessive wear. The implants came in femoral head diameters ranging from 35 to 42 mm. All implants were made of low-carbon cast cobalt alloys according to ASTM F75/ISO 5832-4 with about 26 wt% chromium (Cr) and 5-6 wt% molybdenum (Mo). Differences regarding the elemental composition among manufacturers were summarized previously.<sup>16</sup> At the time of removal, all prostheses were carefully rinsed to remove blood and subsequently sterilized and packed.

### Light Microscopy

All samples were inspected for the presence of macroscopically visible TCR layers using a stereo light microscope (Wild Microscope M420; Leica, Glattbrugg, Switzerland). The presence and location of layers on the bearing surfaces were mapped for both heads and cups. Additional surface details, in particular the characteristics of the layers, were obtained with a reflective light microscope in the bright-field mode (Axiotech Vario 100;

Carl Zeiss, Oberkochen, Germany). Here, a relatively thin 5× objective allowed unrestrained views of the cups' inner bearing surfaces.

### Scanning Electron Microscopy and Energy Dispersive X-Ray Spectroscopy

The articulating areas of the cups and heads of several samples were investigated by means of field-emission scanning electron microscopy (SEM) (Hitachi S-4100; Hitachi, Kyoto, Japan). The surfaces remained uncoated to allow later chemical analyses. Secondary electron (SE) and backscattered electron (BSE) images were recorded from 2 to 10 keV, where the low voltage contributed to more topographic detail in both imaging modes. Energy dispersive X-ray spectroscopy (EDS) was used to evaluate differences in chemical composition between areas. EDS (Model 6816; Oxford Instruments, High Wycombe, UK) was performed at 5 and 10 keV. The system allows quantitative chemical analyses with an accuracy of about 1 wt% for elements with an atomic number greater than 14. Lighter elements are detected qualitatively.

Based on the light microscopy and SEM results, 5 representative MoM couplings were chosen to undergo detailed analyses using SEM and further sophisticated techniques as described below. Manufacturer origin and demographic details of those implants are listed (Table).

### Photoelectron Spectroscopy

To locate the areas of interest, light microscopy and integrated X-ray fluorescence were used prior to photoelectron spectroscopy (XPS) analysis. The distributions of chemical elements on and beneath the surface were resolved by means of XPS analyses (PHI Quantum 2000; Physical Electronics Inc, Eden

**Table.** Demographic Details of the XPS/TEM Subgroup

	Couple A	Couple B	Couple C	Couple D	Couple E
Alloy trade name	Coballoy	Vinertia	Vinertia	Zimaloy	Zimaloy
Manufacturer	Dow, UK	Howmedica, USA	Howmedica, USA	Zimmer, USA	Zimmer, USA
Head diameter (mm)	35	40	35	42	37
Cup inclination (°)	40	48	50	38	37
Gender	female	female	male	male	male
Implantation side	right	left	left	left	right
Age at surgery (years)	73	51	66	58	52
Time in situ (years)	7.5	17.9	19	13.6	12.1

Abbreviations: XPS, photoelectron spectroscopy; TEM, transmission electron microscopy.

“[T]he specific composition of the TCR layers explains the success of self-mating cobalt-chromium alloy joints in the human body: direct metal-metal contact never occurs in the presence of a TCR layer—even without fluid film separation.”



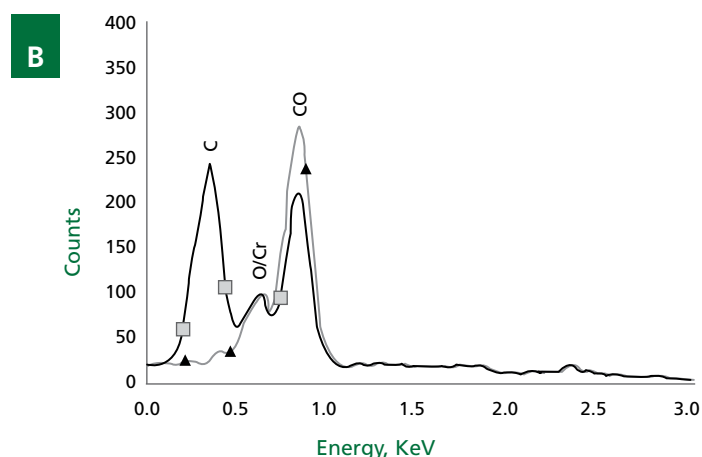

Prairie, Minnesota). Samples were exposed to a monochromatized X-ray beam (Al  $K\alpha = 1486.6$  eV) with 20, 50, or 100  $\mu$ [set Greek letter mu (Unicode character 181)]m lateral resolution. Low-energy electrons and argon ions were used simultaneously to compensate for electrical charging of insulating surface areas during analysis. Emitted photoelectrons were analyzed with a hemispherical electron energy analyzer equipped with a channel plate and a position sensitive detector. The electron take-off angle was 45°. The analyzer was operated in the constant pass energy mode of 117.40 or 58.7 eV, giving a total energy resolution of 1.70 or 1.04 eV, respectively. The residual background pressure inside the spectrometer was better than  $2 \times 10^{-9}$  mbar during analysis. The binding energy scale was calibrated for the Au-4f electrons at 84.0 eV. Elemental concentrations are given in atomic percent (normalized to a total of 100 at%) using the photoelectron peak areas after Shirley background subtraction (Multi-Pack, Version 6.0, Physical Electronics Inc) and the built-in PHI sensitivity factors for the calculation. Next to the expected alloy elements, special attention was directed toward the occurrence of carbon (C), oxygen (O), nitrogen (N), phosphorus

(P), sulfur (S), sodium (Na), magnesium (Mg), and calcium (Ca). The detection limit was 1 at%. The elemental concentrations are presented as a function of distance from the surface as obtained by acquiring sputter depth profiles. The latter were acquired by material removal using 4 kV argon ion etching between consecutive analysis of the elemental concentrations. The sputter rate is material dependent and was determined to be 20 nm/min for  $\text{SiO}_2$ .

#### Transmission Electron Microscopy

To validate the XPS findings and to gain additional information about the subsurface microstructure, head and cup sections were further investigated by means of TEM (EM400; Phillips, Eindhoven, the Netherlands, and Tecnai F20ST; FEI, Eindhoven, the Netherlands) with the use of EDS and electron energy loss spectroscopy (EELS). A custom preparation technique was employed using 2 parallel cuts of the contacting areas with a thickness of 500  $\mu\text{m}$ , which were glued together with a 2-component adhesive. To minimize the gap between the contacting surfaces, the convex head was glued to the concave cup. The

**Figure 1.** A, SEM picture and B, EDS spectra, both within the primary articulating surface area of a retrieved MoM head depicting the high C content within tribochemical reaction layers (square symbol). For comparison, the area adjacent to the TCR layer (the triangle on A) shows no indication of C.



prepared samples were then fixed in a brass cylinder (3 mm diameter) using a slotted pipe (2.5 mm diameter) and a suitable adhesive. A heat treatment at room temperature for 30 minutes and at 150°C for 2 hours resulted in a sufficient bonding strength of the composite setup. After drying, the compounds were cut into 400- $\mu\text{m}$ -thin slices, using a corundum wheel on a low-speed saw. After conventional wet grinding to a thickness of 100  $\mu\text{m}$ , specimens were further thinned from both sides by means of a dimple grinder (Model 656; Gatan GmbH, Munich, Germany) and an ion mill (PIPS 691; Gatan GmbH, Munich, Germany). TEM investigations were performed under an accelerating voltage of 120 kV after a sample thickness of less than 100 nm had been reached. In a recent study with worn high-nitrogen steel samples, this technique did not introduce artifacts into the surface.<sup>21</sup> EDS line scans were performed on these cross-sectional samples to plot the elemental composition from surface to depth. EELS was used to verify the results of EDS measurements. This technique requires an electron spectrometer, which measures the energy of randomly deflected electrons of the electron beam; energy loss can be associated with a specific element. EELS mapping was used to determine the relative local distribution of cobalt (Co), chromium, and carbon on the section of interest.

## Results

### Light Microscopy

All 42 samples, heads and cups, displayed TCR layers. Most were visible with the unaided eye and were found in or adjacent to the articulating areas.

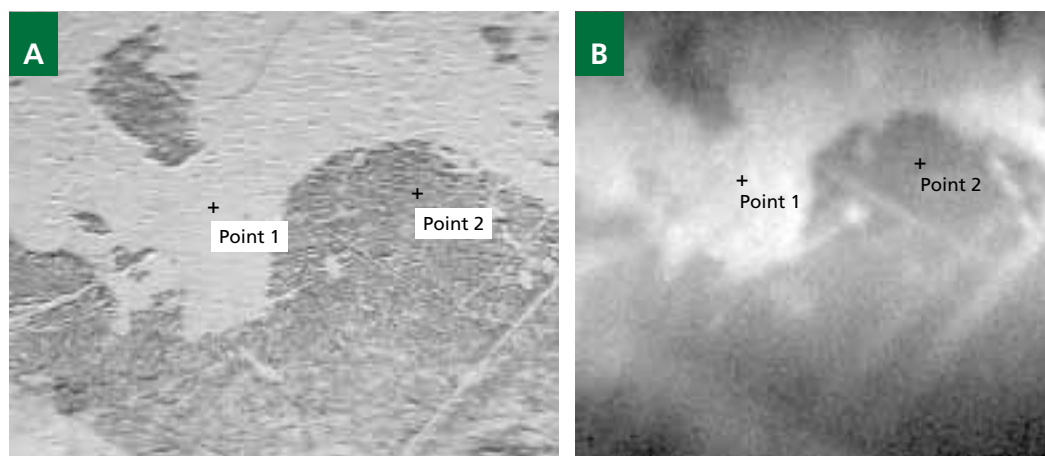
### SEM and EDS Analyses

Large quantities of TCR layers were identified on nearly every component. By SEM, thick layers appeared fragmented; thin ones appeared smooth. Quite often the thick layers were scratched. EDS analyses revealed high carbon contents (Figure 1B). In addition, traces of nitrogen, oxygen, phosphorus, sulfur, chlorine (Cl), sodium, magnesium, potassium (K), and calcium were found occasionally. In areas without TCR layer, carbon and trace elements were not detected.

### XPS Analyses

As was shown earlier,<sup>22</sup> thick denatured protein layers might stick rigidly onto the passive layer of cobalt alloys. Because chromium oxide forms in a moist environment, this is expected and was verified using XPS (data not shown). Here, the focus is on TCR layers with an appearance similar to those in Figure 1A. These layers seem level with metallic-like surface areas in the immediate surroundings and are predominantly found within the contact area. Figure 2A displays a light microscopy image,

**Figure 2.** The primary articulating surface section of a retrieved MoM head being about 1x1 mm in size. **A,** Light microscopy image showing a tribochemical reaction layer, which discriminates from the bright-looking metal surface. **B,** X-ray fluorescence area pattern of the same region, highlighting the differences in chemical composition. Point 1 and Point 2 indicate locations for XPS measurements.

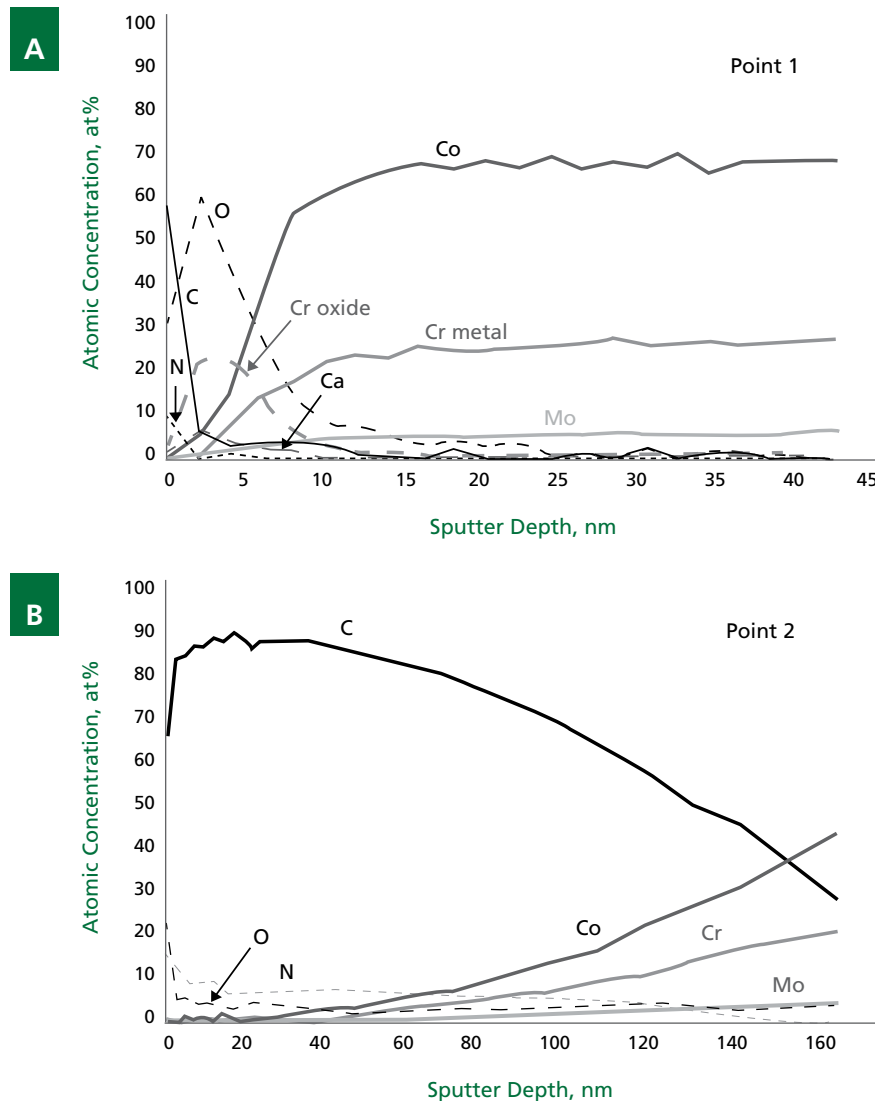


and Figure 2B gives the corresponding X-ray fluorescence overview of the same location. The two areas in question are named Point 1 (on the metallic-looking surface) and Point 2 (on the layer). Due to differences in light reflection, the two areas can easily be distinguished from each other. The X-ray fluorescence overview image (Figure 2B) suggests a difference in chemical composition between these two areas, which were further investigated using XPS.

#### Point 1

The first 2 nm show a combination of carbon, oxygen, nitrogen, and phosphorus. Further below, chromium and oxygen prevail for about 5 nm. The chromium signal shows mostly chromium oxide with a binding energy of 576.8 eV. Then the concentrations of these elements gradually decrease, while the levels of cobalt, metallic chromium (574.2 eV), and molybdenum increase toward the expected concentration (Figure 3A). This XPS profile represents the expected chromium oxide passivated cobalt-alloy surface with some organic carbon-oxygen-nitrogen contamination on top of it.

**Figure 3.** XPS charts showing the elemental distribution of Points 1 and 2 (see Figure 2) in atomic concentrations versus depth from the surface. **A**, At Point 1, a thin contamination layer (containing C) is followed by an O-rich Cr layer with about 8 nm in thickness before the base material is reached. **B**, At Point 2, C prevails down to a depth of 120 nm before the elements of the base material take over. Note the difference in scale between charts.



### Point 2

A completely different picture emerges from the chemical analysis of Point 2, which is only 200 to 300  $\mu\text{m}$  away from Point 1. Atomic concentrations versus depth for Point 2 are displayed in Figure 3B, which shows that, again, carbon-oxygen-nitrogen contamination prevails at the surface. Subjacent to this layer, carbon is the most prominent element for the next 120 nm. The carbon binding energy peaks at 285 eV throughout depth without indication of carbides (281-283 eV). Some carbon-oxygen bonding near the surface is indicated. At about 50 nm depth, the alloy's base elements (cobalt, chromium, molybdenum) begin to appear and rise to their expected concentration levels, while the carbon concentration slowly starts to decrease. Throughout, the chromium signal is 90% metallic, 10% oxidic. Hence, the presence of a distinct passivation layer has vanished.

### TEM Analyses

In agreement with previous investigations,<sup>18</sup> directly below the contact surface, the microstructure is nanocrystalline (Figure 4). Except for some face-centered cubic (fcc) crystals, most crystals have a hexagonal close-packed (hcp) lattice structure and stem from strain-induced phase transformation. Figure 5A displays the TEM micrograph of a location similar to Point 2 in the EDS mode (Figure 2B), which blurs the nanocrystalline microstructure of the material and lacks the level of contrast as the standard bright-field mode depicted in Figure 4A. However, the EDS mode allows for elemental identification. The EDS profile along the dotted line is depicted in Figure 5B. Because of the wedge shape of the TEM specimen (required for its preparation), the base material elements cobalt, chromium, and molybdenum show a steady increase with distance from the surface because more signal is reaching the detector. Nevertheless, within


the first nanometers of the surface, the gradient is obviously steeper, indicating a thin zone of reduced metal content. Interestingly, the carbon and oxygen lines show a distinctly different behavior with a steep increase directly at the surface. In particular, the carbon distribution seems to fit the XPS results suggesting that carbon prevails at the surface and then decreases to a depth of 150 nm. These results were repeatedly verified on samples taken from 3 other retrievals, whereby the thickness of the carbon-rich layer varied from 50 to 200 nm. Furthermore, EELS mapping confirmed the presence of high amounts of carbon below the surface (Figure 6A). The specific structure suggests clusters of carbon within the cobalt alloy substrate.

### Discussion

Considering the environmental conditions of the specific tribosystem of the artificial hip joint, all 4 major wear mechanisms (abrasion, adhesion, surface fatigue, and tribochemical reactions) can apply.<sup>17</sup> Typically, MoM hip joints operate in boundary or mixed lubrication mode,<sup>23</sup> depending on the head diameter and clearance tolerances. Hence, TCR layers are expected for MoM joints and have been described.<sup>24-28</sup> TCR layers were recognized as "deposits" and/or "precipitates," which belies their importance in the tribosystem. In this study we demonstrated that TCR layers do not simply adsorb onto the bearing surface; TCRs also modify the cobalt-alloy substrate, transforming subsurface layers from purely metallic to composite like.

The TCR layer consists of organic, ceramic, and metallic constituents that are well mixed. At first glance these findings are unexpected, but the specific composition of the TCR layers explains the success of self-mating cobalt-chromium alloy joints in the human body: direct metal-metal contact never occurs in the presence of a TCR layer—even without fluid film separation.

**Figure 4.** TEM micrograph showing a nanocrystalline subsurface microstructure. **A**, Bright-field image. **B**, Dark-field image showing the positions of the strain-induced hexagonally close-packed CoCrMo nanocrystals.





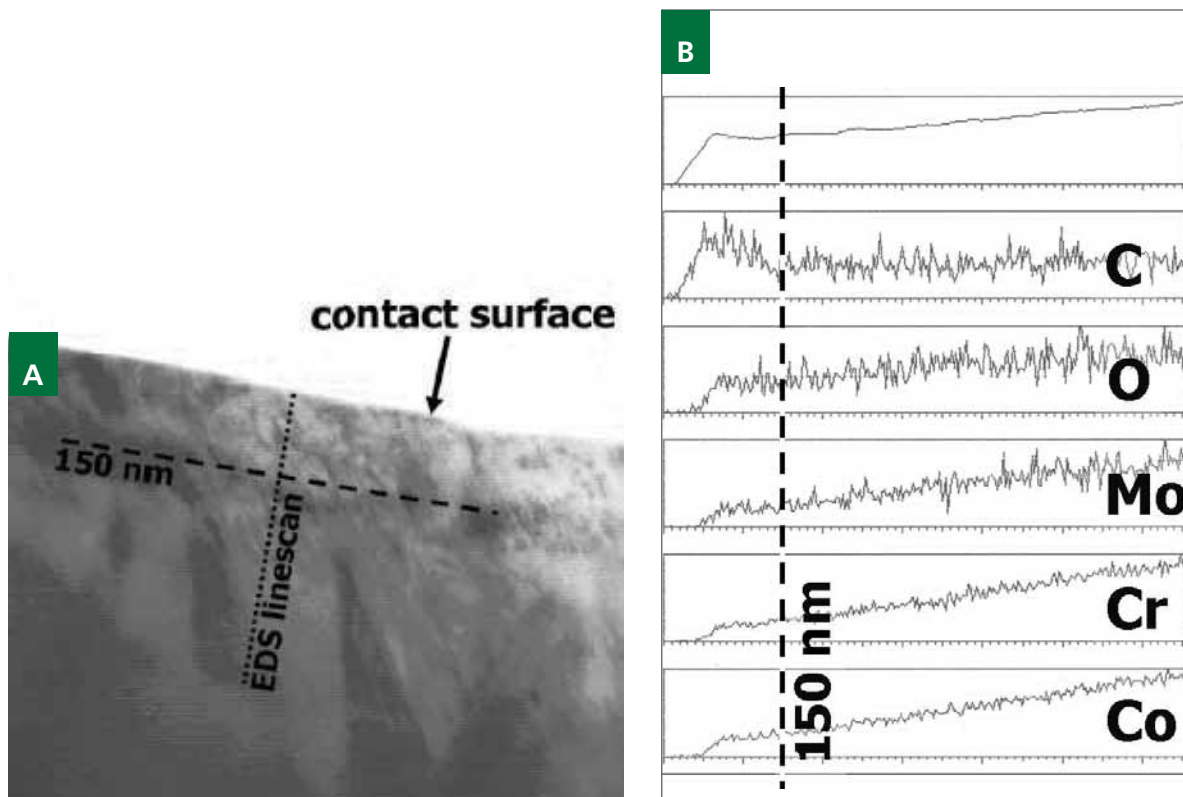
Thus, adhesion, which could lead to catastrophic seizure of the contacting surfaces, is prevented. Indeed, no signs of adhesion were identified on 84 articulating surfaces of this retrieval collection.<sup>16</sup> Obviously, TCR layers are essential to keeping wear rates low.

Tribochemical reactions depend on the mechanical and chemical interaction between body and counterbody, the interfacial medium, and the environment. According to classical theory, reaction layers are generated within or adjacent to the contacting areas and require mechanical action. Friction between the contacting bodies causes an increase in temperature and a rise of the inner energy of the uppermost layers of the deformed materials in contact. Both features enhance the surface reactivity, and oxidized islands are generated.<sup>29-32</sup> These oxide layers flake off the surface after reaching a critical thickness. Now, freshly activated bare metal is presented to the interfacial medium, causing metal ion release. The interfacial medium is likely involved in the generation (reformation) of TCR layers. For example, proteins can stick to the activated surfaces,

forming deposits. This may slow the repassivation process, yet a chromium oxide layer is still generated.<sup>33</sup> The specific bonding mechanism is not well understood but can be attributed to the high number of free Co and Cr ions close to the surface, which easily form metal-protein complexes.<sup>7</sup> In turn, these complexes are adsorbed onto the metallic surfaces.<sup>34</sup> These protein layers adhere rigidly to the surfaces<sup>22</sup> and are typically found on passive metal films.<sup>16</sup>

The subsurface carbon must stem from these or other environmental carbon sources. At Point 2, within the first 100 nm of the TCR layer, the nonmetallic elements were 89% carbon, 7% nitrogen, and 4% oxygen (Figure 3B). This is similar (though not equal) to albumin, a major protein constituent of synovial fluid. Human albumin contains 63% carbon, 17% nitrogen, 19% oxygen, and less than 1% sulfur (neglecting hydrogen).<sup>35</sup> XPS and EELS readings suggested the presence of carbon clusters, not dissolved carbon (furthermore, the measured carbon content is far too high to be attributed to carbides). However, it is still unclear how carbon clusters can

**Figure 5.** **A**, High-resolution TEM picture of the subsurface microstructure directly at the worn surface using the EDS mode (nanocrystals do not show in this mode). **B**, EDS profiles. The dotted line on **A** depicts the measurement pathway for the EDS profiles (first profile: total detected signal). The dashed line marks the 150-nm depth line.



extend up to 200 nm into the bulk, given the thermodynamic conditions of the hip joint. Although locally elevated temperatures between 60°C and 80°C are conceivable,<sup>15</sup> no thermally driven diffusion process can be postulated that would account for driving organic matter into a metallic *solid* solution within a time frame of years. Similarly, a mechanically driven diffusion process<sup>36</sup> is implausible under mild sliding wear conditions: The essential impact energy for this process is not present in total hip joints. Therefore, another mechanism must be operant, capable of blending organic material with a metal substrate. Based on recent molecular dynamics (MD) simulations, such a mechanism was investigated by Rigney et al and was termed “mechanical mixing.”<sup>37-41</sup>

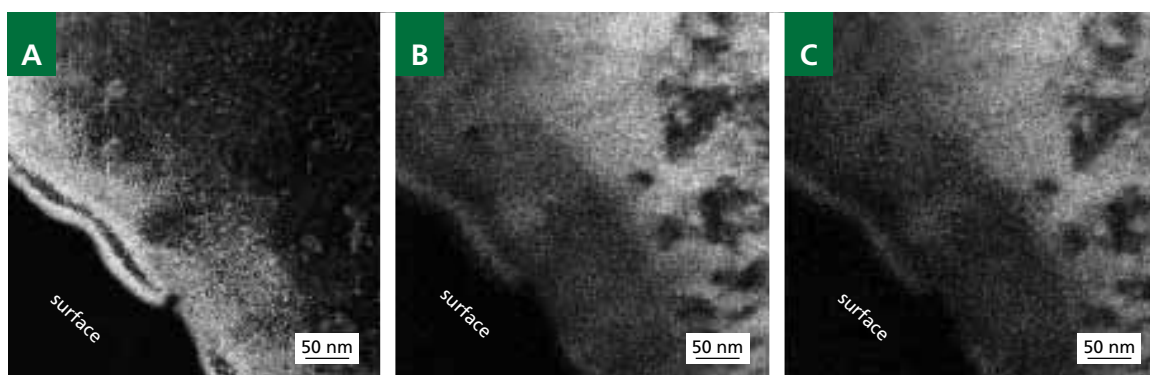
Putting two different metallic materials, A and B, into contact, MD simulations revealed the formation of vortices in the vicinity of the interface during sliding conditions. The convective material transport is most pronounced in regions with high vorticity. Interestingly, the material transport is not restricted by the interface A/B, but material exchange between both bodies can take place. Such a mechanism is capable of mixing materials over a number of atomic distances and has been experimentally validated for several tribosystems.<sup>42-44</sup> In the case of MoM hip replacements, the tribosystem is very complex, and the computer simulation of all aspects (eg, organic constituents of the synovial fluid, materials with strain-induced phase transformation) is currently impossible. However, the same principles apply, suggesting that areas with oxide layers and/or adsorbed proteins are incorporated in clusters into the convective material transport. This, in concert with the external shear stresses due to friction, facilitates the transformation of the uppermost

subsurface layers into a nanocrystalline microstructure of cobalt-chromium alloy. The nanocrystals are known to rotate under mechanical shear stresses,<sup>45</sup> which would then support the mixing process even further.

All retrievals were first-generation McKee-Farrar type MoM components from various manufacturers. They were made of cast cobalt-chromium alloy according to ASTM F75/ISO 5832-4. Today MoM bearings are typically manufactured from wrought (forged) low-carbon or high-carbon cobalt-chromium-molybdenum alloys (according to ASTM F1537 and ISO 5832/12). This is a limitation of the study; however, similar microstructural surface changes were observed for wrought low-carbon<sup>18</sup> and high-carbon<sup>15</sup> cobalt-chromium alloys after in vitro testing. Furthermore, microstructural surface changes were found in other tribosystems with austenitic stainless steels sliding against each other in boundary or mixed lubrication mode.<sup>21</sup> These reports suggest that our findings likely apply to current MoM bearings and thus provide a clear direction for investigating these bearings. Recently a mechanically mixed zone of nanocrystalline metal and organic constituents was documented for a modern, retrieved hip resurfacing implant.<sup>46</sup>

The mechanism is similar to the action of antiwear additives in high-performance engine lubricants. These additives form surface films that protect the underlying material.<sup>47</sup> Further work is required to determine if current MoM devices exhibit the protective nanocrystalline TCR layers and could benefit from strategies to stabilize them. To make MoM bearings more durable and further reduce their wear, the generation of nanocrystalline TCR layers might be enhanced. Strategies should be employed to stabilize these layers.

**Figure 6.** EELS elemental subsurface distribution at a location similar to that of Figure 2. **A**, Carbon map. **B**, Chromium map. **C**, Cobalt map. Bright areas indicate high amounts of element-specific material, whereas dark areas denote their absence. Close to the surface, increasing amounts of C can be found (A), while the main alloy constituents, Co and Cr, are decreased (B and C). In the C map (A), note the distribution of C, which suggests the occurrence of local clusters indicating mechanical mixing with the metal. These C clusters show as white spots.



In conclusion, TCR layers are found frequently on MoM bearing surfaces. These layers are generated through mechanical mixing, with organic carbon stemming from the synovial fluid, and are a nanocrystalline composite of metallic, ceramic, and organic material. One strategy to lower wear rates of these bearings is to promote the formation and stability of TCR layers.

## Acknowledgments

This study was sponsored by the Rush Arthritis and Orthopedics Institute, the AO Research Institute, and the Institute for Product Engineering (UDE). The authors thank Drs Dudzinski and Gleising for TEM support and Drs Sudfeld and Spasova for help regarding HR-TEM and EDS, which was conducted at the Farles Institute.

## References

- Schmalzried TP, Fowble VA, Bitsch RG, et al. Total hip resurfacing. In: Callaghan JJ, Rosenberg AG, Rubash HE, eds. *The Adult Hip*. 2nd ed. Philadelphia, PA: Lippincott; 2007:969-979.
- Hing C, Back D, Shimmin A. Hip resurfacing: indications, results, and conclusions. *Instr Course Lect*. 2007;56:171-178.
- Rieker CB, Schön R, Köttig P. Development and validation of a second-generation metal-on-metal bearing: laboratory studies and analysis of retrievals. *J Arthrop*. 2004;19(suppl 3):5-11.
- Semlitsch M, Willert HG. Clinical wear behaviour of UHMWPE cups paired with metal and ceramic ball heads in comparison to metal-on-metal pairings of hip joint replacements. *Proc Inst Mech Eng H*. 1997;211:73-88.
- Chan FW, Bobynd JD, Medley JB, et al. Wear and lubrication of metal-on-metal hip implants. *Clin Orthop Relat Res*. 1999;369:10-24.
- Rasquinha VJ, Ranawat CS, Weiskopf J, et al. Serum metal levels and bearing surfaces in total hip arthroplasty. *J Arthroplasty*. 2006;21(suppl 2):47-52.
- Hallab NJ, Mikecz K, Vermes C, et al. Differential lymphocyte reactivity to serum-derived metal-protein complexes produced from cobalt-based and titanium-based implant alloy degradation. *J Biomed Mater Res*. 2001;56:427-436.
- Doorn PF, Campbell PA, Worrall J, et al. Metal wear particle characterization from metal on metal total hip replacements: transmission electron microscopy study of periprosthetic tissues and isolated particles. *J Biomed Mater Res*. 1998;42:103-111.
- Catelas I, Campbell PA, Bobynd JD, et al. Wear particles from metal-on-metal total hip replacements: effects of implant design and implantation time. *Proc Inst Mech Eng H*. 2006;220:195-208.
- Brown C, Williams S, Tipper JL, et al. Characterisation of wear particles produced by metal on metal and ceramic on metal hip prostheses under standard and micro-separation simulation. *J Mater Sci Mater Med*. 2007;18:819-827.
- Korovessis P, Petsinis G, Repanti M, et al. Metallosis after contemporary metal-on-metal total hip arthroplasty: five to nine-year follow-up. *J Bone Joint Surg Am*. 2006;88:1183-1191.
- Milošev I, Trebše R, Kovac S, et al. Survivorship and retrieval analysis of Sikomet metal-on-metal total hip replacements at a mean of seven years. *J Bone Joint Surg Am*. 2006;88:1173-1182.
- Jacobs JJ, Hallab NJ. Loosening and osteolysis associated with metal-on-metal bearings: a local effect of metal hypersensitivity? *J Bone Joint Surg Am*. 2006;88:1171-1172.
- Lachiewicz PF. Metal-on-metal hip resurfacing: a skeptic's view. *Clin Orthop Relat Res*. 2007;465:86-91.
- Wimmer MA, Loos J, Nassutt R, et al. The acting wear mechanisms on metal-on-metal hip joint bearings—in vitro results. *Wear*. 2001;250:129-139.
- Wimmer MA, Sprecher C, Hauert R, et al. Tribochemical reaction on metal-on-metal hip joint bearings—a comparison between in-vitro and in-vivo results. *Wear*. 2003;255:1007-1014.
- Wimmer MA, Fischer A. Tribology. In: Callaghan JJ, Rosenberg AG, Rubash HE, eds. *The Adult Hip*. 2nd ed. Philadelphia, PA: Lippincott; 2007:215-226.
- Büscher R, Täger G, Dudzinski W, et al. Subsurface microstructure of metal-on-metal hip joints and its relation to wear particles generation. *J Biomed Mater Res Part B Appl Biomater*. 2005;72B:206-214.
- Sprecher CM, Schneider E, Wimmer MA. Verschleisserscheinungsformen und –mechanismen von explantierten Metall/Metall Hüftprothesen in Relation zur Lebensdauer. *Zeitschrift Mater*. 2005;47:96-100.
- Täger KH. Untersuchungen an Oberflächen und Neogelenkkapseln getragener McKee-Farrar Endoprothesen. *Arch Orthop Unfall-Chir*. 1976;86:101-113.
- Büscher R, Gleising B, Dudzinski W, et al. The effects of subsurface deformation on the sliding wear behaviour of a microtextured high-nitrogen steel surface. *Wear*. 2004;257:284-291.
- Wimmer MA, Nassutt R, Sprecher C, Loos J, Täger G, Fischer A. Investigation of stick phenomena in metal-on-metal hip joints after resting periods. *Proc Inst Mech Eng H*. 2006;220:219-227.
- Dowson D, Hardaker C, Flett M, et al. A hip joint simulator study of the performance of metal-on-metal joints: Part II: design. *J Arthroplasty*. 2004;19(suppl 3):124-130.
- Täger G, Euler E, Plitz W. Changes in shape of the McKee-Farrar hip endoprosthesis. *Orthopäde*. 1997;26:142-151.
- Plitz W, Huber J, Refior HJ. Experimentelle Untersuchungen an Metall-Metall-Gleitpaarungen und ihre Wertigkeit hinsichtlich eines zu erwartenden in-vivo-Verhaltens. *Orthopäde*. 1997;26:135-141.
- Chan FW, Bobynd JD, Medley JB, et al. Engineering issues and wear performance of metal on metal hip implants. *Clin Orthop Relat Res*. 1996;333:96-107.
- McKellop H, Park SH, Chiesa R, et al. In vivo wear of 3 types of metal-on-metal hip prostheses during 2 decades of use. *Clin Orthop Relat Res*. 1996;329:128-140.
- Semlitsch M, Streicher RM, Weber H. Verschleißverhalten von Pfannen und Kugeln aus CoCrMo-Gußblegierung beilangezeit implantierten Ganzmetall Hüftprothesen. *Orthopäde*. 1989;18:377-381.
- Lin JJ, Nadviv S, Grodzian DJM. Changes in the state of solids and mechanochemical reactions in prolonged comminution processes. *Miner Sci Eng*. 1975;7:313-336.
- Lauer JL, Fung SS. Microscopic contour changes of tribological surfaces by chemical and mechanical action. *Trans ASLE*. 1982;26:430-436.
- Quinn TFJ. *NASA Interdisciplinary Collaboration in Tribology: A Review of Oxidational Wear*. Washington, DC: NASA; 1983. NASA Contractor Report 3686.
- Sullivan JL. The role of oxides in the protection of tribological surfaces. In: *Tribology—Friction, Lubrication, and Wear. Fifty Years On*. Part 1. London: Inst Mech Eng Publ Ltd; 1987:283-301.
- Igual Muñoz A, Mischler S. Interactive effects of albumin and phosphate ions on the corrosion of CoCrMo implant alloy. *J Electrochemical Soc*. 2007;154:C562-C570.
- Yan Y, Neville A, Dowson D. Biotribocorrosion—an appraisal of the time dependence of wear and corrosion interactions: II. Surface analysis. *J Phys D Appl Phys*. 2006;39:3206-3212.
- The UniProt Consortium. Universal Protein Resource, UniProtKnowledgebase (UniProtKB). Section Swiss-Prot (UniProtKB/Swiss-Prot), P02768 (ALBU\_HUMAN), Isoform 1 [UniParc], <http://www.uniprot.org/uniprot/P02768>. Accessed February 2009.
- Odonuga S, Li Y, Kraschnotchev P, et al. Forced chemical mixing in alloys driven by plastic deformation. *Phys Rev Lett*. 2005;95:045901-1-045902-4.
- Rigney DA, Hammerberg JE. Unlubricated sliding behavior of metals. *MRS Bull*. 1998;23:32-36.
- Rigney DA, Hammerberg JE. Mechanical mixing and the development of nanocrystalline material during the sliding of metals. *Proc TMS Fall Meet*. 1999;465-474.
- Rigney DA. Transfer, mixing and associated chemical and mechanical processes during the sliding of ductile materials. *Wear*. 2000;245:1-9.
- Subramanian K, Wu JH, Rigney DA. The role of vorticity in the formation of tribomaterial during sliding. *Mater Res Soc Symp Proc*. 2004;821:97-102.
- Karthikeyan S, Kim HJ, Rigney DA. Velocity and strain-rate profiles in materials subjected to unlubricated sliding. *Phys Rev Lett*. 2005;95:1-4.
- Venkataraman B, Sundararajan G. Correlation between the characteristics of the mechanically mixed layer and wear behaviour of aluminium, Al-7075 alloy and Al-MMCs. *Wear*. 2000;245:22-38.
- Singh JB, Cai W, Bellon P. Dry sliding of Cu-15 wt%Ni-8 wt%Sn bronze: wear behaviour and microstructures. *Wear*. 2007;263:830-841.
- Hahn M, Gleising B, Dudzinski W, et al. Electron microscopical investigation of thermally sprayed coatings of cylinder walls after motor tests. *Metallography*. In press.
- Karthikeyan S, Wu JH, Rigney DA. The role of vorticity in the formation of tribomaterial during sliding. In: Anderson PM, Foecke T, Misra A, Rudd RE, eds. *Nanoscale Materials and Modeling—Relations Processing, Microstructure, and Mechanical Properties*. MRS Proceedings Vol. 821. Warrendale, PA: MRS; 2004:961-966.
- Pourzal R, Theissmann R, Morlock M, et al. Microstructural alterations within different areas of articulating surfaces of a metal-on-metal hip resurfacing system. *Wear*. 2009;267:689-694.
- Mosey NJ, Müser MH, Woo TK. Molecular mechanisms for the functionality of lubricant additives. *Science*. 2005;307:1612-1615.

## GIANT CELL TUMOR OF THE TIBIAL TUBEROSITY WITH INVOLVEMENT OF THE PATELLAR LIGAMENT A CASE REPORT

Cara Cipriano, MD;  
Alan Blank, MS; Ira J.  
Miller, MD, PhD;  
Steven Gitelis, MD

Author Affiliations: Department of Orthopedic Surgery (Dr Cipriano), Department of Pathology (Dr Miller), and Department of Orthopedic Surgery (Dr Gitelis), Rush University Medical Center, Chicago, Illinois; and Chicago Medical School at Rosalind Franklin University of Medicine and Science, North Chicago, Illinois (Mr Blank).

Corresponding Author: Steven Gitelis, MD, Rush University Medical Center, 1611 W Harrison St, Suite 300, Chicago, IL 60612 (sgitelis@rush.edu).

### Introduction

Giant cell tumor (GCT) of bone is a lesion that typically affects the metaphyseal region of long bones in skeletally mature individuals. While typically benign, it is locally aggressive with a high potential for recurrence and on rare occasions may metastasize to the lungs. Malignant transformation is even more unusual and occurs almost exclusively following radiation therapy. Approximately 50% of GCTs occur around the knee, most commonly in the distal femur. Several other locations have been described, but to our knowledge the literature contains no fully documented case of GCT involving the tibial tubercle. In our report, we present a patient with GCT in this unusual location and its impact on treatment.

### Case Report

The patient is a 20-year-old previously healthy, asymptomatic man who sensed a pop and the acute onset of pain in his right knee while running. He presented 1 week later complaining of persistent pain with weight bearing and knee flexion. Physical exam was notable for tenderness to palpation and a mass involving the proximal tibia. Range of motion was from 10 to 100 degrees of flexion and limited secondary to pain. Radiographs demonstrated incidental osteopoykilotosis, as well as a lytic lesion without peripheral sclerosis in the metaphysis of the proximal right tibia. Magnetic resonance imaging (MRI) revealed a solid mass involving the tibial tuberosity and patellar ligament (Figure 1). There were no fluid levels. Our differential diagnosis included brown tumor, telangiectatic osteosarcoma, aneurysmal bone cyst, giant cell tumor of tendon sheath, and other periosteal-based tumors. Giant cell tumor of bone was not included in our differential diagnosis because it has not been previously reported in that location.

The decision was made to biopsy the lesion and determine further management based on the frozen section results; if benign, the mass would be excised at the time, and if malignant, the wound would be closed and the patient referred for neoadjuvant treatment prior to definitive surgery. Results of the biopsy were consistent with benign giant cell tumor, and accordingly, extended curettage was performed (Figure 2). After excision and burring, the cavity was treated with phenol (15% glycerol solution) and absolute alcohol and was heat cauterized.

The defect was filled with autogenous iliac bone graft and crushed cancellous allograft. The patellar ligament was found to be effaced by tumor and partially avulsed. The patellar ligament was reinforced with two No. 2 nonabsorbable sutures weaved through the ligament and passed through drill holes in the tibia. There were no complications, and the patient tolerated the proce-

“The GCT was exclusively located eccentrically in the tibial tuberosity, thus weakening the patellar ligament attachment and leading to injury. This site has not been previously reported, and its unusual location affected treatment.”



ture well. A plain radiograph of the chest was obtained as part of the metastatic workup and found to be clear of pulmonary lesions.

At 2 weeks postoperatively, the patient began partial weight bearing and physical therapy directed at range of motion and strengthening, with no resisted quadriceps exercises. He quickly recovered full active flexion and extension. Follow-up radiographs demonstrated good incorporation of the graft, and the patient was allowed to progress to full weight bearing within 8 weeks (Figure 3). At 6 months after surgery, he is currently asymptomatic and free of recurrent disease with full function.

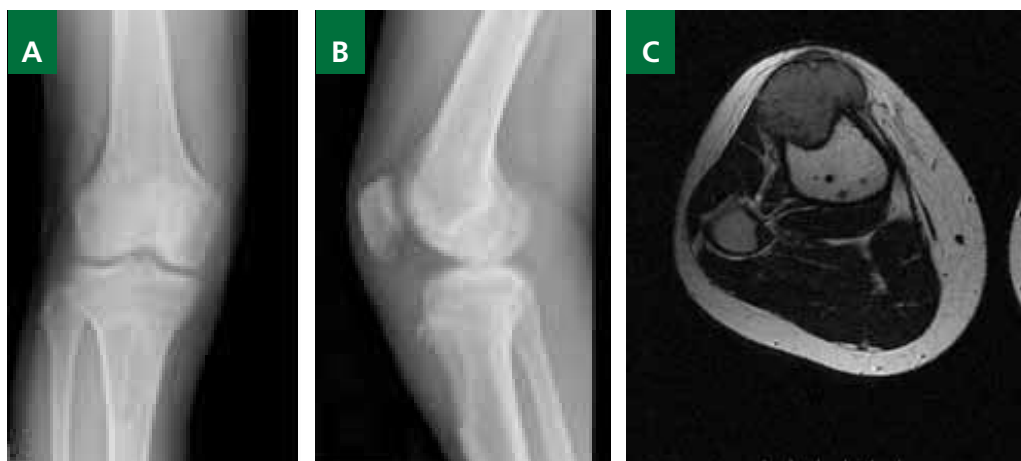
#### Discussion

GCT is relatively common, comprising approximately 5% of all bone tumors and 20% of benign bone tumors.<sup>1</sup> The incidence may be higher in Chinese populations<sup>2</sup> but seems to have no

significant gender predilection. It typically affects patients aged 20 to 40 years and is rarely seen prior to closure of the physis.<sup>1,3-6</sup> GCT is almost always located in the metaphyseal area, frequently involving the subchondral bone; however, while the lesion may abut the cartilage, it generally does not invade the joint itself. In the rare cases of GCT occurring before skeletal maturity, it has been confined to the metaphysis.<sup>3,7</sup> Fain et al in 1993 reported on 14 nonepiphyseal giant cell tumors; half of the reported cases were in children, where distinction from solid variant of aneurysmal bone cyst can be a diagnostic difficulty, and none exclusively involved the tibial tuberosity.<sup>8</sup>

The most common symptom of GCT is pain related to the destruction and mechanical insufficiency of the involved bone, and approximately 12% of cases present with pathologic fractures.<sup>9</sup> Range of motion is often limited due to proximity to the joint, which may also develop an effusion or synovitis. A palpable mass may be noted if the lesion involves the soft tis-

**Figure 1.** Preoperative imaging studies. **A**, Anterior posterior radiograph of the right knee and upper tibia. Note the lytic lesion of the metaphysis of the tibia with an incidental finding of osteopoikilosis. **B**, Lateral radiograph of the right knee joint. There is a lytic destruction of the tibial tuberosity with a partial avulsion of the patellar ligament. Also present is a soft tissue mass around the tibial tuberosity without matrix mineralization. **C**, Axial T1 weighted MRI of the right tibia. There is a solid homogeneous mass involving the tibial tuberosity without bone invasion. The effaced patellar ligament is seen anterior to the mass. Also note the osteopoikilosis in the tibia.



sues, and neurologic symptoms may be present in cases of the spine. Patellar ligament injury secondary to tibial tuberosity GCT has not been previously reported.

Plain radiographs are the most important imaging study in the diagnosis of GCT. Metaphyseal/epiphyseal lesions in the skeletally mature patient are most commonly GCT and much less frequently clear cell chondrosarcoma, telangiectatic osteosarcoma, and hyperparathyroidism (brown tumor). GCT produces a purely lytic, geographic, eccentric lesion with poorly defined borders reflective of its aggressive behavior. The cortex of the bone is often expanded or destroyed, but a permeative appearance is rare. The matrix of the tumor is similar in density to the soft tissues and does not contain calcification or ossification. Soft tissue involvement may be appreciated on computed tomography (CT) but is best characterized by MRI.<sup>10</sup>

Histologically, the diagnostic pattern of GCT is zones of evenly spaced, large multinucleated giant cells in a background of round and spindled mononuclear cells with minimal stromal matrix. The giant cells in GCT of bone are generally larger and contain more nuclei than the giant cells found in other tumors such as giant cell tumor of soft tissue and benign fibrous histiocytoma. Areas devoid of giant cells, in which the spindled cells form fascicles or a storiform pattern, can also be seen, and some cases have abundant admixed reparative

bone. Mitotic activity and necrosis can be seen, but significant pleomorphism is not acceptable. Malignant tumors such as osteosarcoma and pleomorphic sarcomas can have giant cells that appear similar, but in GCT of bone the nuclei of the giant cells are similar to the nuclei of the mononuclear cells. Secondary aneurysmal bone cyst (ABC) may also be seen in association with GCT. Vascular invasion outside the main tumor can be seen and is not a diagnostic criteria of malignancy. The spindled mononuclear cells, rather than the monocytes or the giant cells, are believed to be the neoplastic component of GCT.<sup>11</sup>

Extended curettage and stabilization is the treatment of choice for benign GCT. The lesion is accessed through a large cortical window and removed with curettes. The cavity is then treated with one of several adjuvant agents including phenol,<sup>3,5,12</sup> liquid nitrogen,<sup>13</sup> bone cement,<sup>14-16</sup> hydrogen peroxide,<sup>17</sup> and zinc chloride.<sup>18</sup> These extension techniques have improved reported recurrence rates from 25%-50% to 10%-20%.<sup>1-3,19-23</sup> The defect is then packed with either bone graft or cement; the latter may be advantageous as it further cauterizes the tumor cavity, allows for immediate weight bearing, and facilitates the detection of recurrence on plain film. En bloc resection may be considered in expendable bones, and reconstruction may be necessary in cases of pathologic fracture, multiple recurrence, or situations in which the joint anatomy cannot be otherwise

**Figure 2. A,** Hematoxylin and eosin section at the time of biopsy (142x). There are numerous benign giant cells with nuclei identical to the background mononuclear cells. Note that there is no aneurysmal component to this tumor. **B,** Hematoxylin and eosin high-power section (284x). The histological and cytological features are characteristic of a benign giant cell tumor.

**Figure 3.** Three-month postoperative lateral radiograph of the right knee and tibia. There has been significant healing of the tibial tuberosity with bone formation in the lytic defect.

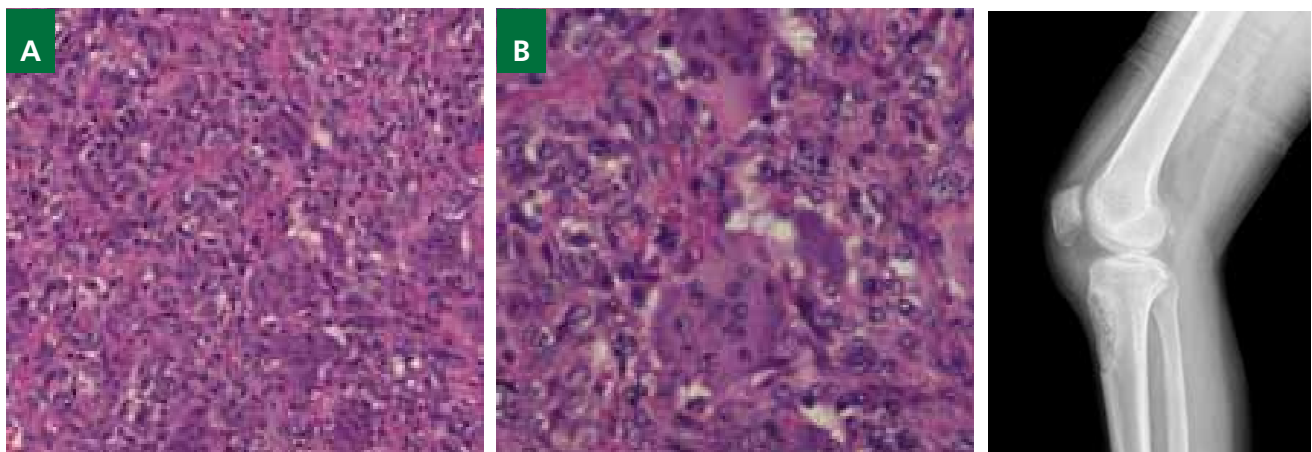


Figure 2

Figure 3

restored. Radiotherapy may be useful, especially in the sacrum and spine, although it carries a risk of malignant degeneration or postradiation sarcoma.<sup>3</sup> Recurrences usually occur between 12 and 18 months following resection and rarely occur more than 3 years from the time of surgery.<sup>3</sup> They are typically identified on follow-up radiographs, where they form progressive lucencies adjacent to the site of excision.

The current case is unusual in its clinical presentation as well as its imaging features. The GCT was exclusively located eccentrically in the tibial tuberosity, thus weakening the patellar ligament attachment and leading to injury. This site has not been previously reported, and its unusual location affected treatment. The tibial tuberosity is an apophysis, which might explain occurrence at this site. After aggressive intralesional excision, the GCT cavity is typically filled with methyl methacrylate.<sup>20</sup> In this patient we chose to fill the defect with bone graft because of the need to provide a biological substrate for patellar ligament healing.

In conclusion, this represents an extremely unusual GCT that required special management because of the anatomic location. In tumors of tibial tuberosity, GCT of bone should be considered as a possible diagnosis.

## References

1. Unni KK. *Dahlin's Bone Tumors: General Aspects and Data on 11,087 Cases*. 5th ed. Philadelphia, PA: Lippincott-Raven; 1996.
2. Campanacci M. Giant-cell tumor. In: Gaggi A, ed. *Bone and Soft Tissue Tumors*. Bologna, Italy: Springer-Verlag; 1990:117-153.
3. Huvos AG. *Bone Tumors: Diagnosis, Treatment, and Prognosis*. Philadelphia, PA: WB Saunders Co; 1991.
4. Picci P, Manfrini M, Zucchi V, et al. Giant-cell tumor of bone in skeletally immature patients. *J Bone Joint Surg Am*. 1983;65(4):486-490.
5. Sherman M, Fabricius R. Giant-cell tumor in the metaphysis in a child: report of an unusual case. *J Bone Joint Surg Am*. 1961;43-A:1225-1229.
6. Hoeffel JC, Galloy MA, Grignon Y, et al. Giant cell tumor of bone in children and adolescents. *Rev Rhum Engl Ed*. 1996;63(9):618-623.
7. Fain JS, Unni KK, Beabout JW, Rock MG. Non-epiphyseal giant cell tumor of the long bones: clinical, radiologic, and pathologic study. *Cancer*. 1993;71(11):3514-3519.
8. Dreinhöfer KE, Rydholm A, Bauer HC, Kreicbergs A. Giant-cell tumours with fracture at diagnosis: curettage and acrylic cementing in ten cases. *J Bone Joint Surg Br*. 1995;77(2):189-193.
9. Turcotte RE. Giant cell tumor of bone. *Orthop Clin North Am*. 2006;37(1):35-51.
10. Goldring SR, Schiller AL, Mankin HJ, Dayer JM, Krane SM. Characterization of cells from human giant cell tumors of bone. *Clin Orthop Relat Res*. 1986;(204):59-75.
11. Quint U, Müller RT, Müller G. Characteristics of phenol: instillation in intralesional tumor excision of chondroblastoma, osteoclastoma and enchondroma. *Arch Orthop Trauma Surg*. 1998;117(1-2):43-46.
12. Malawer MM, Bickels J, Meller I, Buch RG, Henshaw RM, Kollender Y. Cryosurgery in the treatment of giant cell tumor: a long-term follow-up study. *Clin Orthop Relat Res*. 1999;(359):176-188.
13. Bini SA, Gill K, Johnston JO. Giant cell tumor of bone: curettage and cement reconstruction. *Clin Orthop Relat Res*. 1995;(321):245-250.
14. Capanna R, Fabbri N, Bettelli G. Curettage of giant cell tumor of bone: the effect of surgical techniques and adjuvants on local recurrence rate. *Chir Organi Mov*. 1990;75(1)(suppl):206.
15. Rock M. Curettage of giant cell tumor of bone: factors influencing local recurrences and metastasis. *Chir Organi Mov*. 1990;75(1)(suppl):203-205.
16. Nicholson NC, Ramp WK, Kneisl JS, Kaysinger KK. Hydrogen peroxide inhibits giant cell tumor and osteoblast metabolism in vitro. *Clin Orthop Relat Res*. 1998;(347):250-260.
17. Zhen W, Yaotian H, Songjian L, Ge L, Qingliang W. Giant-cell tumour of bone: the long-term results of treatment by curettage and bone graft. *J Bone Joint Surg Br*. 2004;86(2):212-216.
18. Blackey HR, Wunder JS, Davis AM, White LM, Kandel R, Bell RS. Treatment of giant-cell tumors of long bones with curettage and bone-grafting. *J Bone Joint Surg Am*. 1999;81(6):811-820.
19. Gitelis S, Mallin BA, Piasecki P, Turner F. Intralesional excision compared with en bloc resection for giant-cell tumors of bone. *J Bone Joint Surg Am*. 1993;75(11):1648-1655.
20. Goldenberg RR, Campbell CJ, Bonfiglio M. Giant-cell tumor of bone: an analysis of two hundred and eighteen cases. *J Bone Joint Surg Am*. 1970;52(4):619-664.
21. O'Donnell RJ, Springfield DS, Motwani HK, Ready JE, Gebhardt MC, Mankin HJ. Recurrence of giant-cell tumors of the long bones after curettage and packing with cement. *J Bone Joint Surg Am*. 1994;76(12):1827-1833.
22. Saiz P, Virkus W, Piasecki P, Templeton A, Shott S, Gitelis S. Results of giant cell tumor of bone treated with intralesional excision. *Clin Orthop Relat Res*. 2004;(424):221-226.
23. Sung HW, Kuo DP, Shu WP, Chai YB, Liu CC, Li SM. Giant-cell tumor of bone: analysis of two hundred and eight cases in Chinese patients. *J Bone Joint Surg Am*. 1982;64(5):755-761.

## PEDIATRIC PATELLA REALIGNMENT SURGERY DO POSTOPERATIVE RADIOGRAPHIC MEASUREMENTS CORRELATE WITH CLINICAL OUTCOME?

Aimee Brasher, MD;  
Jeffrey Ackman, MD

Author Affiliations: Department of Orthopedic Surgery, Rush University Medical Center, Chicago, Illinois (Drs Brasher and Ackman); and Shriners' Hospital for Children, Chicago, Illinois (Dr Ackman).

Corresponding Author: Aimee Brasher, MD, 1117 W Vernon Park Pl #2, Chicago, IL 60607 (aembrasher@gmail.com).

### Background

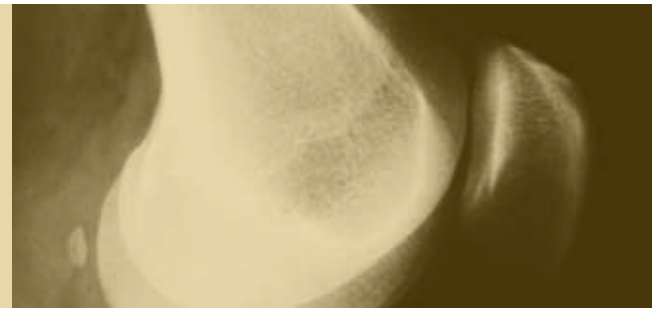
Recurrent patella instability usually occurs in children with anatomic variants that predispose them to dislocate. These anatomic factors include an increased Q angle, increased tibial valgus, excessive tibial torsion, femoral condylar dysplasia, patella alta, and generalized ligamentous laxity. If a trial of a brief period of immobilization followed by vigorous rehabilitation is not successful, surgery is recommended. Several different surgical techniques are available, and their use is guided by the patient's skeletal maturity, the patient's skeletal anatomy, and the surgeon's preference. No definitive perioperative guidelines exist to improve the likelihood of a successful surgical outcome. Therefore, this study evaluates preoperative and postoperative radiographs in order to determine if certain radiographic measurements, specifically the congruence angle, can help predict a successful outcome.

### Methods

Sixty-seven patients with the diagnosis of recurrent patella subluxation or dislocation underwent patella realignment procedures from August 1995 to May 2009 at our institution. Diagnoses included Down, nail-patella, Pierre Robin, and Ehlers-Danlos syndromes; Leri-Weill dyschondrosteosis; and congenitally short femur. Of those, 18 patients had both preoperative and postoperative radiographs that included the entire set of anteroposterior, lateral, and Merchant views. Five of the 18 patients had surgery on both knees and 2 patients had another realignment surgery on the same knee due to recurrence for a total of 24 knees. Eighteen of those knees belonged to female patients, and 6 belonged to males. The radiographs were analyzed for the position of the patella as seen on the preoperative and postoperative lateral and Merchant views. The patella height was measured from the lateral view, and both the sulcus and the congruence angles were measured from the Merchant view. Preoperative patellar heights were unable to be measured accurately in 6 knees, and preoperative congruence angles were unable to be measured in 7 knees. This was because 1 knee belonged to a patient with nail-patella syndrome, 4 knees had fixed patella dislocation, and 3 knees were radiographed with poor technique. Postoperatively, 3 knees had unmeasurable radiographs, and postoperative radiographs were not yet available for 1 knee due to recent surgery.



“Although the congruence angle was corrected to a more normal value in all successful cases, no definite relationship was found between the postoperative congruence angle and clinical outcome.”



### Results

The mean follow-up time was 36 months. Three knees, all belonging to female patients, had recurrence of patella dislocation: 1 patient sustained an impact injury at 12 months causing the redislocation, 1 patient was noncompliant with follow-up and physical therapy and had a recurrence at 24 months, and 1 recurrence happened spontaneously at 13 months. Three patients had persistent pain, and 2 of the 3 required a knee arthroscopy and debridement. Four knees (3 patients) had persistent flexion contractures; 2 were corrected with serial casting, and the other 2 received a distal femoral anterior epiphysiodesis. The average preoperative sulcus and congruence angles of

this patient series were 145 and 5.5 degrees, respectively. The average patella height was 1.23. The average postoperative congruence angle was  $-2.8$  degrees. The average change in congruence angle was  $-11.4$  degrees.

### Conclusion

Although the congruence angle was corrected to a more normal value in all successful cases, no definite relationship was found between the postoperative congruence angle and clinical outcome. More studies need to be done on this patient population with better radiographic follow-up in order to determine if certain radiographic parameters can predict clinical outcome.

## RUNX2 REGULATION OF COL10A1 EXPRESSION DURING CHONDROCYTE MATURATION IMPACTS BONE FORMATION AND JOINT MAINTENANCE

Ming Ding, PhD, DDS; Sam Abbassi, BS; Jun Li, MD; Yaojuan Lu, MD, MS; Valérie Geoffroy, PhD; Feifei Li, MD; Anna Plaas, PhD; Qiping Zheng, PhD

Author Affiliations: Department of Anatomy and Cell Biology (Drs Ding, Lu, Li, and Zheng and Mr Abbassi) and Department of Biochemistry and Internal Medicine (Drs Li and Plaas), Rush University Medical Center, Chicago, Illinois; University Paris 7, Paris, France (Dr Geoffroy); and Department of Pathophysiology, Anhui Medical University, Hefei, China (Dr Li).

Corresponding Author: Qiping Zheng, PhD, Rush University Medical Center, 1735 W Harrison St, room 716, Chicago, IL 60612 (qiping\_zheng@rush.edu).

### Background

Runx2, a member of the Runt domain protein family, has been demonstrated to be an essential transcription factor for osteoblast differentiation as well as a critical regulator for chondrocyte maturation. The type X collagen gene (*Col10a1*) is a specific molecular marker of hypertrophic chondrocytes during endochondral bone formation. It has been shown that type X collagen plays a critical role during skeletal development and maintenance by impacting the supporting properties of the growth plate and the mineralization process. Recently, a growing body of evidence suggests that Runx2 regulates type X collagen gene expression during chondrocyte maturation in different species. We surmise that Runx2 may regulate cell-specific murine type X collagen gene expression and therefore impact chondrocyte maturation during embryonic skeletal development and postnatal articular chondrocyte differentiation.

### Methods

A transgenic construct in which Flag-tagged *Runx2* complementary DNA (cDNA) is placed under the control of the 300-bp cell-specific *Col10a1* regulatory element was previously generated for microinjection. Transgenic founder mice were confirmed by PCR genotyping using Flag-specific primers. Real-time reverse transcription–polymerase chain reaction (RT-PCR) was performed using total RNAs prepared from mouse limbs at the P1 stage. Mouse skeletal phenotypes were analyzed by histology using hematoxylin and eosin staining as well as whole skeletal preparation using alcian blue and alizarin red staining. We also induced osteoarthritis in sex-matured mice through treadmill running and injection of transforming growth factor  $\beta_1$ .

### Results

PCR genotyping confirmed that we successfully generated 4 transgenic mouse lines that overexpress *Runx2* using a hypertrophic chondrocyte-specific *Col10a1* regulatory element. Real-time RT-PCR using total RNAs prepared from mouse limbs at the P1 stage shows that the *Runx2* messenger RNA (mRNA) is 30% to 40% upregulated, whereas *Col10a1* shows 3-fold to 5-fold activation in transgenic mice compared to wild-type littermate controls. Histological analysis of long-bone sections of all transgenic mice at the P1 stage showed a longer hypertrophic zone (Figure 1). Skeletal preparations of these mice at late embryonic stages suggest that the transgenic mice are generally smaller and show delayed ossification in the craniofacial region, the long-bone

“We surmise that Runx2 may regulate cell-specific murine type X collagen gene expression and therefore impact chondrocyte maturation during embryonic skeletal development and postnatal articular chondrocyte differentiation.”



digits, and the tail (Figure 2). Moreover, these mice were subjected to treadmill mechanic overuse, and the results suggest that the transgenic mice had less joint degeneration compared to the littermate controls.

### Conclusion

Our data suggest that Runx2 regulates cell-specific *Col10a1* expression and chondrocyte maturation in vivo. The *Runx2* transgenic mice that have enhanced *Runx2* and *Col10a1* expression may change the matrix environment and impact chondrocyte maturation during skeletal development and maintenance. Our preliminary studies suggest that Runx2 upregulation of *Col10a1*

expression affects the apoptotic process of hypertrophic chondrocytes in the growth plate and impacts bony replacement and bone formation. This reminds us of the human disease of cleidocranial dysplasia, a skeletal dysplasia that is due to RUNX2 haploinsufficiency producing defects in both intramembranous and endochondral bone formation. Together with the observation of less degeneration, the *Runx2* transgenic mice may serve as a useful model to study the biological significance of chondrocyte maturation during endochondral bone formation and the pathogenesis of osteoarthritis.

**Figure 1.** Histological analysis of *Runx2* transgenic mice. Hematoxylin and eosin staining was performed, and sagittal sections of proximal ulna of a transgenic mouse from one line at the P1 stage showed a much longer hypertrophic zone compared to the wild-type littermate controls. Similar results were also observed in all other long-bone sections (not shown). Tg indicates transgenic; WT, wild type.

**Figure 2.** Skeletal preparations of *Runx2* transgenic mice. Transgenic mice are generally smaller and show delayed ossification in the craniofacial region (white arrows), long-bone joints, and tails as compared to wild-type controls. The wild-type mouse has a clear background within the digits, whereas the transgenic mouse shows deeper blue staining of cartilage, suggesting possible disturbed ossification (black arrows). Tg indicates transgenic; WT, wild type.

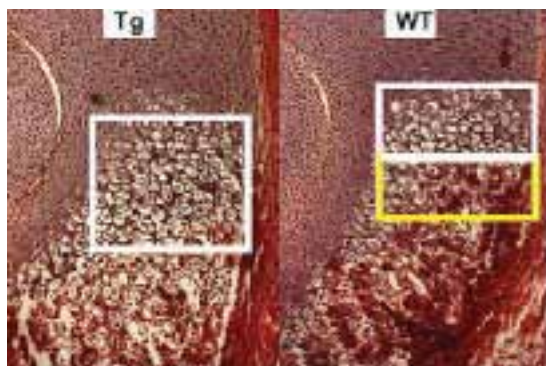


Figure 1

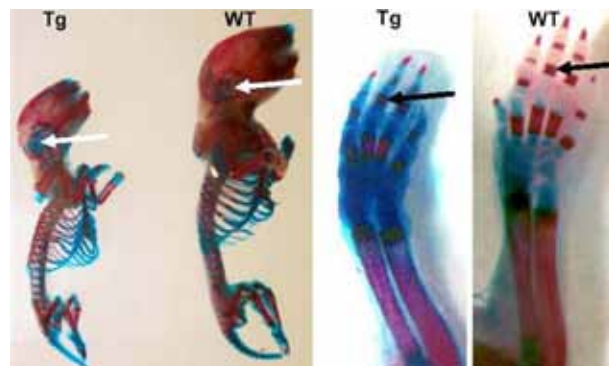


Figure 2

## NORMALIZATION OF GLENOHUMERAL ARTICULAR CONTACT PRESSURES AFTER EITHER LATARJET OR ILIAC CREST BONE GRAFTING PROCEDURE

### IMPACT OF GRAFT TYPE, POSITION, AND CORACOID ORIENTATION

Neil Ghodadra, MD;  
Jordan Goldstein, MD;  
Aman Gupta, BS;  
Elizabeth Shewman, PhD;  
Nikhil N. Verma, MD;  
Bernard R. Bach Jr, MD;  
Anthony A. Romeo, MD;  
Matthew T. Provencher, MD

Author Affiliations: Department of Orthopedic Surgery, Rush University Medical Center, Chicago, Illinois (Drs Ghodadra, Goldstein, Shewman, Verma, Bach, and Romeo and Mr Gupta); and Department of Orthopedic Surgery, Naval Medical Center San Diego, San Diego, California (Dr Provencher).

Corresponding Author: Neil Ghodadra, MD, Rush University Medical Center, 1611 W Harrison St, 2nd floor, Chicago, IL 60612 (neil\_ghodadra@rush.edu).

#### Background

The articular conformity after bone augmentation procedures for glenoid deficiency remains poorly defined. We sought to investigate the alterations in glenohumeral articular contact pressures in a glenoid bone loss model to determine changes in pressure with proud, flush, and recessed Latarjet or iliac crest bone grafting (ICBG) procedures, and to determine the optimal orientation of the Latarjet graft.

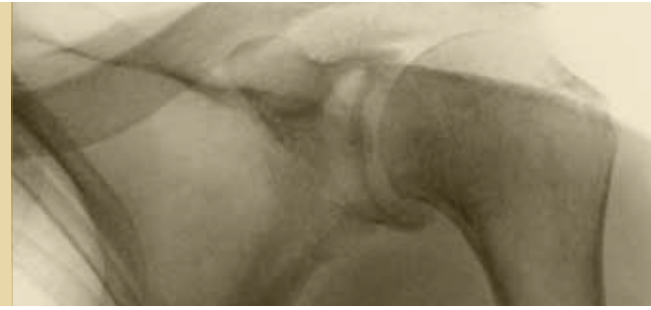#### Methods

Twelve fresh-frozen cadaveric shoulders were stripped of all tissues except the labrum. In static positions of scapular abduction (30 degree, 60 degree, and 60 degree with 90 degree external rotation) with a compressive load of 440 N, the glenohumeral contact area, contact pressure, and peak pressure were determined with a Tekscan sensor (Tekscan, South Boston, Massachusetts) for several conditions: (1) intact glenoid, (2) glenoid with clinical 15% and 30% defect from the 2 o'clock position to the 6 o'clock position, (3) 30% glenoid defect treated with Latarjet bone block placed 2 mm proud, flush, and 2 mm recessed to the glenoid, (4) 30% glenoid defect with ICBG placed 2 mm proud, flush, and 2 mm recessed to the glenoid, and (5) Latarjet bone block oriented with either the lateral (Latarjet-LAT) or inferior (Latarjet-INF) surface of the coracoid as the glenoid face.

#### Results

With a glenoid bone defect of 30% and 60-degree glenohumeral abduction with 90-degree external rotation, contact area decreased  $37 \pm 5\%$  ( $P < .04$ ), and mean contact pressure increased  $72 \pm 8\%$  ( $P < .01$ ), with mean contact pressure in the anteroinferior quadrant increasing  $294 \pm 35\%$  ( $P < .001$ ) compared to the intact state. Bone grafts in the flush position restored mean contact pressure to  $84 \pm 4\%$  (ICBG,  $P < .02$ ),  $79 \pm 5\%$  (Latarjet-INF,  $P < .02$ ), and  $62 \pm 4\%$  (Latarjet-LAT,  $P < .03$ ) of normal. Latarjet-LAT demonstrated statistically higher peak pressure than ICBG and Latarjet-INF at nearly all positions ( $P < .02$ ). With bone grafts placed in the proud position, mean contact pressure increased an additional  $44 \pm 6\%$  ( $P < .01$ ) in the anteroinferior quadrant, with a  $100 \pm 13\%$  ( $P < .01$ ) increase in the posterosuperior glenoid indicating a shift posteriorly.

“Due to the inherent congruity of the ICBG and the bony anatomy of the coracoid, contact pressures and edge loading were lower in glenoid defects reconstructed with ICBG and Latarjet-INF than in those reconstructed with the Latarjet-LAT method.”



Mean contact pressures and forces of bone grafts placed in the recessed position were not significantly different from those of 30% glenoid defect, with high edge loading.

### Conclusion

Due to the inherent congruity of the ICBG and the bony anatomy of the coracoid, contact pressures and edge loading were lower in glenoid defects reconstructed with ICBG and Latarjet-INF than in those reconstructed with the Latarjet-LAT method.

Grafts placed in the proud position not only increased the peak pressure in the anteroinferior quadrant but also shifted the articular contact forces to the posterosuperior quadrant. These findings may point toward the potential clinical advantages of an optimally placed ICBG and the Latarjet-INF graft orientation versus Latarjet-LAT for glenoid bone reconstruction.

## EARLY RESULTS OF A BIPOLAR RADIAL HEAD IMPLANT A MULTICENTER STUDY

Robert R. L. Gray, MD;  
Mark Zunkiewicz, MD;  
Robert W. Wysocki, MD;  
Mark S. Cohen, MD;  
Mark E. Baratz, MD

Author Affiliations: Department of Orthopedic Surgery, Rush University Medical Center, Chicago, Illinois (Drs Gray, Wysocki, and Cohen); and Department of Orthopaedic Surgery, Allegheny General Hospital, Pittsburgh, Pennsylvania (Drs Zunkiewicz and Baratz).

Corresponding Author: Robert R. L. Gray, MD, Rush University Medical Center, 1611 W Harrison St, Suite 400, Chicago, IL 60612 (rgreezy@gmail.com).

### Background

Radial head fractures are the most common type of elbow fracture in adult patients. Radial head arthroplasty is a mainstay of treatment for comminuted radial head fractures that are not amenable to open reduction and internal fixation. While there has been significant progress and success with newer implants, appropriate positioning and maintenance of a balanced elbow have proved to be a challenge. Bipolar radial head arthroplasty was developed to improve radiocapitellar congruency throughout the range of motion without overstuffing the joint. Contact areas are decreased even despite the bipolar design, measuring 33% of the capitellum versus 44% with a native radial head. Though there are conflicting data, bipolar radial head implants have enjoyed success. The purpose of this study is to evaluate the early to midterm results for one specific bipolar radial head implant both clinically and radiographically.

### Methods

Thirty-two nonconsecutive patients sustaining a comminuted radial head fracture deemed to be unreconstructable underwent surgery for resection of the radial head followed by replacement arthroplasty with a bipolar implant (Katalyst; Integra, Plainsboro, New Jersey; Figure). The surgery was done through a lateral approach through the extensor mass. In addition to the radial head replacement, 15 patients had a lateral ulnar collateral ligament repaired, 2 had an ulnar collateral ligament repaired, 5 had open-reduced internal fixation (ORIF) of the olecranon, 3 had ORIF of the coronoid, and 5 had a coronoid fragment excised.

A retrospective analysis was conducted to evaluate the outcomes of all patients who had undergone surgery at least 2 years prior to the initiation of the study in January 2009. All patients were evaluated with a Mayo Elbow Score (MES), a visual analog scale (VAS), and the Disabilities of the Arm, Shoulder and Hand (DASH) questionnaire. At final follow-up, radiographs of both wrists and both elbows were analyzed to measure medial and lateral ulnohumeral joint space and stem angulation. Lucency about the stem, changes at the radiocapitellar joint, and ulnar variance were noted, as were the presence of bone spurs and heterotopic ossification. A goniometer was used to measure the full range of motion of both elbows of each participant.

### Results

The average follow-up time for the 32 patients (33 implants) was 33.93 months (range, 24.2 to 47.4 months). At the final follow-up, the MES averaged 92.37 (range, 65 to 100), the VAS measurement averaged 1.4 (range, 0 to 5), and the DASH score averaged 24.1 (range, 0 to 48.33).

“Bipolar radial head arthroplasty was developed to improve radiocapitellar congruency throughout the range of motion. . . . [It] provides excellent pain relief, range of motion, and stability at a follow-up of at least 2 years.”



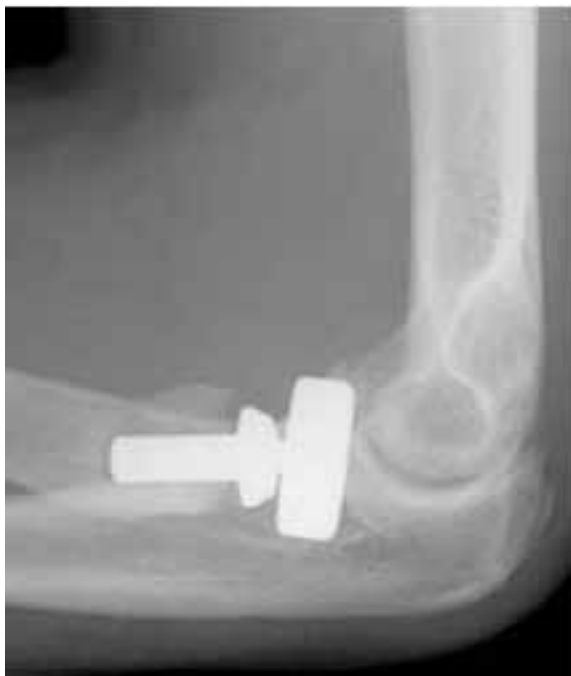Range of motion for the affected elbows averaged 133 degrees of flexion, 11.3 degrees of extension, 72 degrees of pronation, and 82.2 degrees of supination. The unaffected elbows averaged 141.9 degrees of flexion, 3.75 degrees of extension, 76.8 degrees of pronation, and 88.5 degrees of supination ( $P = .02$ ). Radiographic analysis showed an average lateral ulnohumeral space of 2.69 mm versus 2.74 mm on the unaffected side. The medial ulnohumeral space was 2.05 mm versus 2.36 mm on the unaffected side ( $P = .2$ ).

Other radiographic findings included bone spurs in 22 patients, 13 patients with heterotopic ossification that was not motion limiting, and stem lucency in 24 patients.

### Conclusion

Bipolar radial head arthroplasty provides excellent pain relief, range of motion, and stability at a follow-up of at least 2 years. Though radiographs may be difficult to interpret, ulnohumeral gapping may be used as a surrogate for determining overstuffing of the prosthesis. Lucency about the stem, change in implant/radius angle, and mild heterotopic ossification were common and do not appear to affect outcomes at a follow-up of 2 years or more after the surgery. More long-term data on this and similar implants are needed.

**Figure.** Katalyst bipolar radial head implant (lateral radiograph).



## EARLY RESULTS OF A POROUS TANTALUM PRIMARY FEMORAL HIP PROSTHESIS

Brett Levine, MD

Author Affiliation: Department of Orthopedic Surgery, Rush University Medical Center, Chicago, Illinois.

Corresponding Author: Brett Levine, MD, Rush University Medical Center, 1611 W Harrison St, Suite 300, Chicago, IL 60612 (Blevine@rushortho.com).

### Background

The successful use of proximally coated tapered hip prostheses has been well documented in the orthopedic literature. Similarly, a variety of implants utilizing a porous tantalum coating (Figure 1) have been shown to have good results in primary and revision total hip arthroplasty (THA). Currently, the porous tantalum primary hip prosthesis shown in Figures 2 and 3, which is modeled after a previous proximal taper design using cancellous-structured titanium as a coating, is the only femoral stem utilizing this metallic foam coating. A transition metal with atomic number 73, tantalum has a long history of biomedical applications but was not used much in orthopedics until its introduction as Trabecular Metal (Zimmer/Implex, Warsaw, Indiana) in 1997. Porous tantalum is a highly porous metal constructed via the deposition of commercially pure tantalum onto a reticulated vitreous carbon skeleton. The result is a metallic foam with a modulus of elasticity of approximately 3 GPa (similar to cancellous bone), 70%-80% porosity, and an enhanced surface coefficient of friction. The goal of this study is to report on the early results of a new, proximally coated porous tantalum femoral hip prosthesis.

### Methods

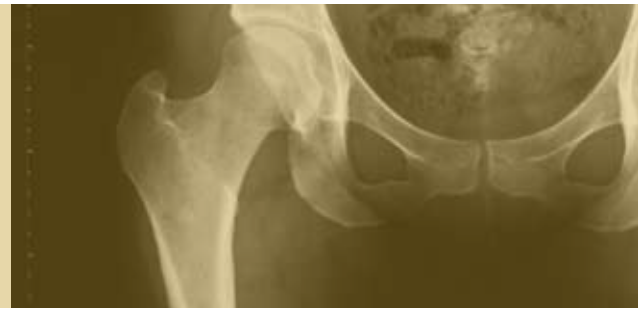A retrospective, single-surgeon case review of 74 patients (including 48 THAs and 26 hemiarthroplasties) treated from 2006 to 2008 using the porous tantalum femoral hip prosthesis was performed. Institutional review board approval was obtained for this study. A standard posterior approach was utilized for all cases, and appropriate perioperative antibiotics and deep vein thrombosis (DVT) prophylaxis were given. All patients followed the same postoperative protocols and were allowed to bear weight as tolerated. Patient demographics were compiled, as were preoperative and postoperative clinical results including Harris hip scores, modified Postel scores, and overall results at latest follow-up. Revisions for any reason and complications were recorded. Radiographic evaluation was conducted for all patients and assessed for osseointegration, component migration, and osteolysis.

### Results

Of the 74 patients, 2 died of causes unrelated to the hip surgery and were unavailable for follow-up. The remaining patients had an average age of 64.6 years (range, 36-95 years) at the time of surgery. The average length of follow-up was 24 months (range, 12-36 months). Harris hip scores improved from an average of 43 (range, 15-65) before the operation to 88 (range, 61-96) after the operation. There were 5 (6.8%) complications, including 2 (2.7%) intraoperative fractures, 1 (1.4%) acetabular loosening, and 2 (2.7%) dislocations. The 2 fractures were treated with



“At early follow-up the porous tantalum femoral component provides appropriate improvements in outcome scores with an acceptable rate of complications. . . . [F]urther follow-up is necessary to validate the early success of this implant and coating.”



intraoperative cable fixation with prosthesis retention without postoperative complication. No cases of persistent thigh pain have been reported to date. Radiographic evaluation revealed no cases of implant migration, subsidence, or osteolysis. No revision surgeries were required for the femoral components in this cohort.


#### Conclusion

At early follow-up the porous tantalum femoral component provides appropriate improvements in outcome scores with an acceptable rate of complications. Despite the enthusiasm for porous tantalum in hip and knee reconstructions, further follow-up is necessary to validate the early success of this implant and coating.

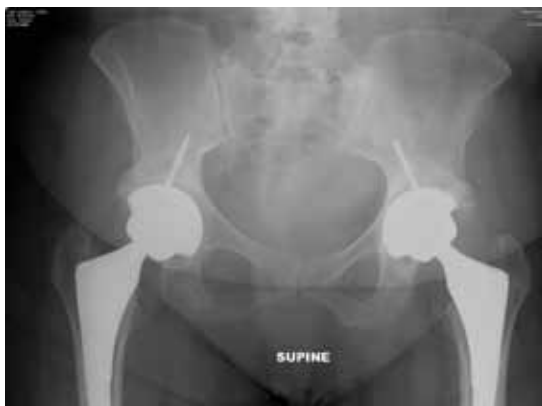**Figure 1.** High-power photomicrograph of porous tantalum (courtesy of Zimmer, Warsaw, Indiana).

**Figure 2.** Radiograph of porous tantalum hip prosthesis showing osseointegration at 1-year follow-up.

**Figure 3.** Porous tantalum primary hip prosthesis (courtesy of Zimmer, Warsaw, Indiana).



**Figure 1**



**Figure 2**



**Figure 3**

## CHARACTERIZATION OF THE HYPERTROPHIC CHONDROCYTE-SPECIFIC *COL10A1* CIS-ENHANCER BOTH IN VITRO AND IN VIVO

Feifei Li, MD; Yaojuan Lu, MD, MS; Sam Abbassi, BS; Ming Ding, PhD, DDS; Yuqing Chen, MS; Siying Wang, PhD, MD; Brendan Lee, PhD, MD; Qiping Zheng, PhD

Author Affiliations: Department of Anatomy and Cell Biology, Rush University Medical Center, Chicago, Illinois (Drs Li, Lu, Ding, and Zheng and Mr Abbassi); Department of Molecular and Human Genetics (Dr Lee and Ms Chen) and Howard Hughes Medical Institute (Dr Lee and Ms Chen), Baylor College of Medicine, Houston, Texas; and Department of Pathophysiology, Anhui Medical University, Hefei, China (Drs Li and Wang).

Corresponding Author: Qiping Zheng, PhD, Rush University Medical Center, 1735 W Harrison St, room 716, Chicago, IL 60612 (qiping\_zheng@rush.edu).

### Background

Chondrocyte hypertrophy or maturation, a process characterized by expression of the cell-specific type X collagen gene (*Col10a1*), is a critical stage of chondrocyte terminal differentiation during endochondral bone formation. Therefore, understanding the molecular regulation of *Col10a1* expression will help to understand the molecular processes of chondrocyte maturation. This is essential not only for skeletal development but also for diseased skeletal conditions that show abnormal chondrocyte maturation. We have recently shown that a 150-bp (-4296 to -4147) *Col10a1* distal promoter is sufficient to mediate its hypertrophic chondrocyte-specific expression in transgenic studies. Here we further localize the cis-enhancer element of this 150-bp promoter region and its putative binding factors that are responsible for *Col10a1*/reporter expression.


### Methods

Reporter constructs that use different lengths of 5'-sequences of this 150-bp fragment upstream of the same *Col10a1* basal promoter driving the *LacZ* gene have been generated using cloning strategies described elsewhere. Polymerase chain reaction (PCR) genotyping was performed using *LacZ*-specific primers. Reporter expression was determined by X-gal blue staining of mouse embryos to assay the beta-galactosidase activity. To identify its putative binding factors, we also performed electrophoretic mobility shift assay (EMSA) and in vitro reporter assay using DNA oligos derived from this 150-bp region and the hypertrophic MCT (mouse chondrocyte T) cell model, a mouse chondrocyte cell line that has been immortalized with SV40 large T antigen and expresses type X collagen abundantly upon growth arrest.

### Results

To further localize the cis-enhancer in this 150-bp *Col10a1* distal promoter, we generated 2 additional transgenic mouse lines that use the 5'-sequences -4296 to -4255 bp and -4296 to -4214 bp respectively to drive *LacZ* as a reporter. No reporter expression (blue staining) was observed in the hypertrophic chondrocytes of either of these 2 transgenic mouse lines. This result, together with our previous transgenic studies using a 90-bp (-4296 to -4280 and -4238 to -4171) deletion mutant reporter construct, suggests the importance of a 43-bp (-4213 to -4171) *Col10a1* distal promoter in mediating its cell-specific expression in vivo. Interestingly, detailed sequence analysis of this region identified 2 tandem repeat putative Runx2 core binding sites (TGTGGG-

“[U]nderstanding the molecular regulation of *Col10a1* expression will help to understand the molecular processes of chondrocyte maturation.”



TGTGGC, -4187 to -4176). EMSA and in vitro reporter assay using DNA oligos derived from this region (-4201 to -4163 bp and -4197 to -4171 bp) demonstrated that these core binding sites are required to form the specific DNA/protein complexes with hypertrophic MCT cell nuclear extracts and to contribute to *Col10a1*/reporter expression (Figures 1 and 2).

### Conclusion

Our results further localize the cis-enhancer to 30-40 base pairs of the *Col10a1* distal promoter and indicate that Runx2 is a major regulator for *Col10a1* expression via these Runx2

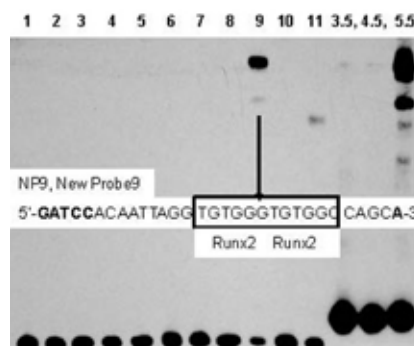
binding sites. Candidate molecules that regulate hypertrophic chondrocyte-specific *Col10a1* expression are also expected to regulate chondrocyte maturation, a process that has been associated with diseased skeletal conditions such as skeletal dysplasias, growth retardation, fracture healing, and osteoarthritis. This short cis-enhancer allows us to identify Runx2 as well as novel molecules that promote chondrocyte maturation and therefore provides novel targets for curing multiple skeletal disorders.

**Figure 1.** Dissecting the 150-bp *Col10a1* distal promoter. Three consecutive pairs of DNA oligos (approximately 45 bases) and 11 shorter ones (approximately 30 bases with 10 bases of overlapping sequence between junctions) derived from the 150-bp *Col10a1* enhancer were commercially synthesized by Integrated DNA Technologies (Coralville, Iowa). These oligos were designed with BamHI and BglII adapters for cloning purposes. P3.5 indicates a probe covering the junction sequence between the previous third and fourth elements; NP1, new probe 1, as distinguished from the original P1 probe.

**Figure 2.** Electrophoretic mobility shift assay (EMSA) using additional cis-elements derived from the 150-bp *Col10a1* promoter. EMSAs were performed with hypertrophic MCT (mouse chondrocyte T) cell nuclear extracts and the consecutive pairs of DNA oligos using the LightShift Chemiluminescent EMSA Kit (Thermo Fisher Scientific, Rockford, Illinois). Specific DNA/protein complexes formed with the new probe 9 (lane 9) and element 5.5. The sequence of the new probe 9 is shown. The BamHI and BglII adaptors are highlighted. Putative Runx2 binding sites (TGTGGG-TGTGGC, -4187 to -4176 bp) are boxed. Bottom signals were from free probe.

**150-bp *Col10a1* Promoter Element**

-4296, NPI	NP2	NP3
---GCCTCCTGTTTCACGTAGGAATAAGCTCCTTCATAAAGT		
P3.5		5'-AP1 (-4276 to -4243)
NP4	NP5	NP6
CACAGACCAGTCAGGCTGAACAGCTCCGAGGAAACACC		
P4.5		
NP7	NP8	NP9
CAGAATAAAAATAGTTAATACACACAATTAGGTGTGG		
	P5.5	
NP10	NP11	
GTGTGGCCAGCAAATACTCTGATTCTACAATCTGTT		
	3'-AP1 (-4166 TO -4152) -4147	



**Figure 1**

**Figure 2**

## DOES MULTILEVEL LUMBAR STENOSIS LEAD TO POORER OUTCOMES?

### A SUBANALYSIS OF THE SPINE PATIENT OUTCOMES RESEARCH TRIAL (SPORT) LUMBAR STENOSIS STUDY

Daniel K. Park, MD;  
Howard S. An, MD; Jon D.  
Lurie, MD, MS; Wenyan  
Zhao, MS; Anna Tosteson,  
ScD; Tor D. Tosteson, ScD;  
Harry Herkowitz, MD;  
Thomas Errico, MD; James  
N. Weinstein, DO, MS

Author Affiliations: Department of Orthopedic Surgery, Rush University Medical Center, Chicago, Illinois (Drs Park and An); Departments of Medicine (Drs Lurie, A. Tosteson, and Weinstein), Orthopedics (Mr Zhao), and Community and Family Medicine (Drs A. Tosteson and T. Tosteson), Dartmouth Medical School, Lebanon, New Hampshire; William Beaumont Hospital, Royal Oak, Michigan (Dr Herkowitz); and New York University Hospital for Joint Diseases, New York, New York (Dr Errico).

Corresponding Author: Howard S. An, MD, Rush University Medical Center, 1611 W Harrison St, Suite 400, Chicago, IL 60612 (han@rushortho.com).

#### Background

The purpose of this study was to determine the effect on patients' baseline symptoms and clinical outcomes across time of multilevel lumbar stenosis with or without degenerative spondylolisthesis as compared to single-level stenosis. In previous studies, patients with spinal stenosis with or without degenerative spondylolisthesis or scoliosis have demonstrated better clinical outcomes with surgery than with nonsurgical treatment. However, the impact of multilevel stenosis has not been studied in these patients.

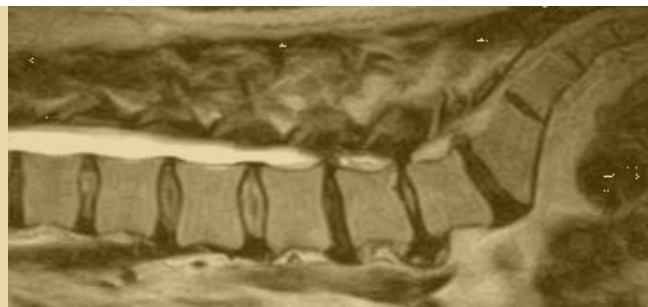
#### Methods

The authors analyzed results from a multicenter randomized and observational study, the Spine Patient Outcomes Research Trial (SPORT), comparing surgical versus nonsurgical treatments for spinal stenosis with or without spondylolisthesis or scoliosis. The authors used the Bodily Pain and Physical Function scales of the Medical Outcomes Study 36-item Short-Form General Health Survey (SF-36) and the modified Oswestry Disability Index to measure primary outcomes at 6 weeks, 3 months, 6 months, 1 year, and 2 years. Secondary outcome measures included the Stenosis Bothersomeness Index, Leg Pain Bothersomeness Scale, Low Back Pain Bothersomeness Scale, and patient satisfaction.

#### Results

In this subanalysis of SPORT data, patients with multilevel spinal stenosis did not demonstrate worse baseline symptoms or worse treatment outcomes in isolated spinal stenosis as compared with those with single-level stenosis; however, if concomitant degenerative spondylolisthesis existed, patients with only single-level stenosis tended to improve more than did those with multilevel stenosis, particularly after surgery.

"Patients with spinal stenosis who do not have associated degenerative spondylolisthesis or scoliosis can be treated without surgery, irrespective of the number of levels involved."



### Conclusion

Patients with spinal stenosis who do not have associated degenerative spondylolisthesis or scoliosis can be treated without surgery, irrespective of the number of levels involved. If surgery is performed, the number of levels treated does not predict outcome. In contrast, patients with concomitant degenerative

spondylolisthesis and single-level stenosis do better with surgery than do those with additional levels of stenosis. This study emphasizes the importance of shared decision making between the physician and patient when considering treatment for spinal stenosis.

## THUMB CARPOMETACARPAL SUSPENSION ARTHROPLASTY USING INTERFERENCE SCREW FIXATION SURGICAL TECHNIQUE AND CLINICAL RESULTS

Robert W. Wysocki, MD;  
Mark S. Cohen, MD;  
John J. Fernandez, MD

Author Affiliations: Department of Orthopedic Surgery, Rush University Medical Center, Chicago, Illinois.

Corresponding Author: Robert W. Wysocki, MD, Rush University Medical Center, 1611 W Harrison St, Suite 400, Chicago, IL 60612 (rwysocki@rushortho.com).

### Background

Carpometacarpal osteoarthritis of the thumb is a common condition for which surgical reconstruction is commonly used. The standard ligament reconstruction with tendon interposition using the flexor carpi radialis (FCR) requires not only the arthroplasty incision but also additional incisions in the forearm for tendon harvest. The technique utilized in this series avoids these additional incisions and uses an interference screw as opposed to tendon-to-tendon suturing for fixation.

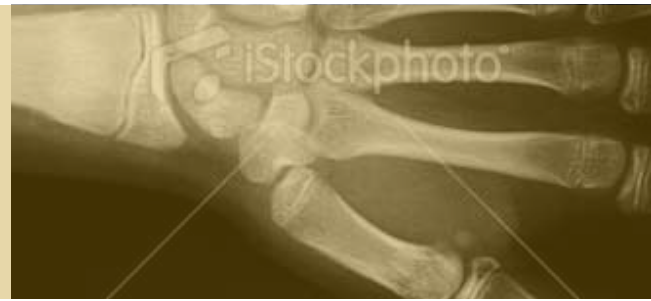### Methods

Between February 2006 and March 2007, 29 consecutive carpometacarpal arthroplasties using FCR transfer tenotomized at the level of the scaphoid with interference screw fixation were performed by a single surgeon for a primary diagnosis of osteoarthritis. The procedure is performed through a single incision, eliminating the need for additional incisions for tendon harvest, and utilizes a bioabsorbable interference screw (Arthrex, Naples, Florida) rather than direct tendon-to-tendon suturing for fixation (Figures 1 to 3). No tendon interposition was used. The study population comprised 24 women and 5 men, with a mean age of 58 years. All study patients had radiographs performed at 2 weeks, at 3 months, and at a special research follow-up visit at a minimum of 1 year. Preoperative radiographs were graded according to the Eaton classification, and the distance from scaphoid to first metacarpal was measured on all postoperative films to assess settling. All patients were evaluated at a minimum of 1 year with the Disabilities of the Arm, Shoulder and Hand (DASH) questionnaire, a visual analog scale (VAS), and a functional survey, and range of motion, grip strength, and pinch strength in lateral key pinch, tip pinch, and tripod pinch were measured using standard dynamometry.

### Results

Twenty-eight patients were available for follow-up at a mean of 19 months (range, 13-26 months). One patient who moved out of the country was lost to follow-up. None of the arthroplasties required revision procedures. Average length of procedure was 33 minutes (range, 26-42 minutes). X-ray analysis revealed a mean postoperative distance from scaphoid to first metacarpal of 5.9 mm, which decreased by a mean of 0.9 mm over the first 3 months and by an additional 0.5 mm by the time of final follow-up (Figure 4). Mean radial and palmar abductions in the affected thumb were 55 degrees and 55 degrees respectively; these were not statistically different from the contralateral side ( $P > .05$ ). Strength in the affected arm was 62 lb grip, 13 lb lateral key pinch, 13 lb tripod, and 10 lb tip pinch, with only lateral key pinch being statistically weaker

“Thumb carpometacarpal arthroplasty using interference screw fixation demonstrated excellent clinical outcomes with no revisions in this series.”



than the opposite side ( $P < .05$ ). The mean DASH score was 15 (range, 0-56), and the mean VAS pain score was 1 (range, 0-5). All patients were able to return to their preoperative level of employment, 50% were able to participate in vigorous recreational activity, 21% found that their thumb limited their ability to perform their work, and 17% found that their thumb limited their recreational activities. There were no significant relationships between DASH score, VAS score, radiographic settling, side-to-side strength, or range of motion versus gender, Eaton stage, or workers' compensation status.

### Conclusion

Thumb carpometacarpal arthroplasty using interference screw fixation demonstrated excellent clinical outcomes with no revisions in this series. Operative times, pinch strength, range of motion, and radiographic settling rates compare favorably to other techniques described in the existing literature. Except for lateral key pinch, there was no statistically significant difference in strength compared to the contralateral side.

**Figure 1.** The trapezium has been excised, and the guide wire for the interference screw is driven obliquely retrograde through the dorsal metacarpal base out the volar side exiting just distal to the articular surface. The wire is then overdrilled.

**Figure 2.** After traction is pulled on the flexor carpi radialis and it is tenotomized at the proximal margin of the wound, the tendon is pulled through the metacarpal drill hole from volar to dorsal.

**Figure 3.** The interference screw is inserted over the wire with traction on the flexor carpi radialis and manual pressure directing the thumb metacarpal base toward the adjacent index.

**Figure 4.** Anteroposterior radiograph at 18 months demonstrates good maintenance of the arthroplasty space, with the distance from scaphoid to first metacarpal settling from 7 mm to 6 mm.

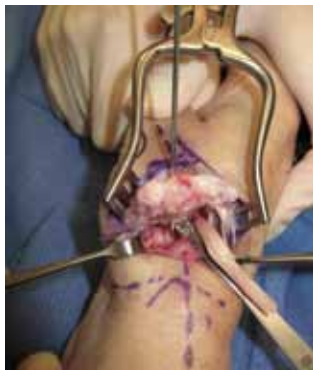

Figure 1

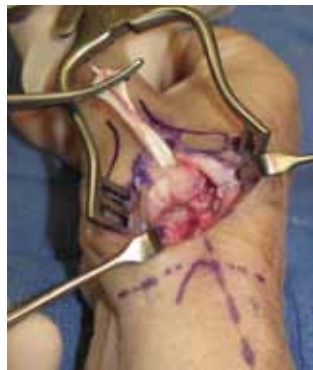

Figure 2

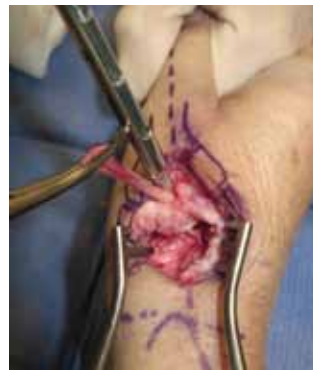

Figure 3

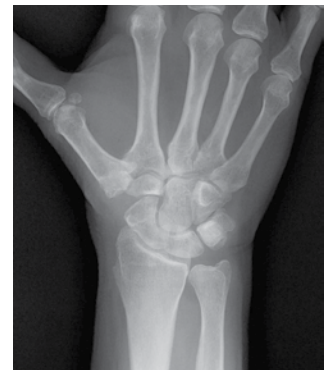

Figure 4

## PUBLICATIONS

2010 RUSH ORTHOPEDICS JOURNAL

## SELECT PUBLICATIONS

2009

### An, Howard S.

An HS. Making ethical decisions in current orthopedic practice. *Am J Orthop*. 2009;38(8):382-383.

Deng Y, Lu G, An HS. En bloc spondylectomy for the treatment of spinal tuberculosis with fixed and sharply angulated kyphotic deformity. *Spine*. 2009;34(20):2140-2146.

Kim KW, Ha KY, Lee JS, Nam SW, Woo YK, Lim TH, An HS. Notochordal cells stimulate migration of cartilage end plate chondrocytes of the intervertebral disc in in vitro cell migration assays. *Spine J*. 2009;9(4):323-329.

Park DK, An HS. Problems related to cervical fusion: malalignment and nonunion. *Instr Course Lect*. 2009;58:737-745.

Sugisaki K, An HS, Espinoza Orías AA, Rhim R, Andersson GB, Inoue N. In vivo three-dimensional morphometric analysis of the lumbar pedicle isthmus. *Spine*. 2009;34(24):2599-2604.

### Andersson, Gunnar B. J.

Andersson GB. Surgery: vertebroplasty: one solution does not fit all. *Nat Rev Rheumatol*. 2009;5(12):662-663.

Fisher CG, Andersson GB, Weinstein JN. Spine focus issue. Summary of management recommendations in spine oncology. *Spine*. 2009;34(suppl 22):S2-6.

### Bach, Bernard R., Jr

Bach BR Jr. ACL treatment current trends and future directions. *J Knee Surg*. 2009;22(1):5.

Bach BR Jr, DaSilva J. Arthroscopic-assisted removal of a migrated intra-articular distal femoral epiphysiodesis staple. *J Knee Surg*. 2009;22(3):272-275.

DeFranco MJ, Bach BR Jr. A comprehensive review of partial anterior cruciate ligament tears. *J Bone Joint Surg Am*. 2009;91(1):198-208.

Detterline AJ, Provencher MT, Ghodadra N, Bach BR Jr, Romeo AA, Verma NN. A new arthroscopic technique to determine anterior-inferior glenoid bone loss: validation of the secant chord theory in a cadaveric model. *Arthroscopy*. 2009;25(11):1249-1256.

Gomoll AH, Yanke AB, Kang RW, Chubinskaya S, Williams JM, Bach BR, Cole BJ. Long-term effects of bupivacaine on cartilage in a rabbit shoulder model. *Am J Sports Med*. 2009;37(1):72-77.

Gupta A, Lattermann C, Busam M, Riff A, Bach BR Jr, Wang VM. Biomechanical evaluation of bioabsorbable versus metallic screws for posterior cruciate ligament inlay graft fixation: a comparative study. *Am J Sports Med*. 2009;37(4):748-753.

Park DK, Fogel HA, Bhatia S, Bach BR Jr, Gupta A, Shewman EF, Wang V, Verma N, Provencher MT. Tibial fixation of anterior cruciate ligament allograft tendons: comparison of 1-, 2-, and 4-stranded constructs. *Am J Sports Med*. 2009;37(8):1531-1538.

Pascual-Garrido C, Friel NA, Kirk SS, McNickle AG, Bach BR Jr, Bush-Joseph CA, Verma NN, Cole BJ. Midterm results of surgical treatment for adult osteochondritis dissecans of the knee. *Am J Sports Med*. 2009; 37(suppl 1):125S-130S.

### Berger, Richard A.

Berger RA, Kusuma SK, Sanders SA, Thill ES, Sporer SM. The feasibility and perioperative complications of outpatient knee arthroplasty. *Clin Orthop Relat Res*. 2009;467(6):1443-1449.



Berger RA, Sanders SA, Thill ES, Sporer SM, Della Valle C. Newer anesthesia and rehabilitation protocols enable outpatient hip replacement in selected patients. *Clin Orthop Relat Res.* 2009;467(6):1424-1430.

Vail TP, Mariani EM, Bourne MH, Berger RA, Meneghini RM. Approaches in primary total hip arthroplasty. *J Bone Joint Surg Am.* 2009;91(suppl 5):10-12.

Yuan BJ, Moran SL, Tay SC, Berger RA. Trapeziectomy and carpal collapse. *J Hand Surg Am.* 2009;34(2):219-227.

#### Cohen, Mark S.

Cohen MS, Romeo AA. Open and arthroscopic management of lateral epicondylitis in the athlete. *Hand Clin.* 2009;25(3):331-338.

Kalainov DM, Cohen MS. Treatment of traumatic scapholunate dissociation. *J Hand Surg Am.* 2009;34(7):1317-1319.

Katolik LI, Cohen MS. Anterior interosseous nerve palsy after open capsular release for elbow stiffness: report of 2 cases. *J Hand Surg Am.* 2009;34(2):288-291.

#### Cole, Brian J.

Cole BJ, Pascual-Garrido C, Grumet RC. Surgical management of articular cartilage defects in the knee. *J Bone Joint Surg Am.* 2009;91(7):1778-1790.

DeFranco MJ, Cole BJ. Current perspectives on rotator cuff anatomy. *Arthroscopy.* 2009;25(3):305-320.

Gomoll AH, Kang RW, Chen AL, Cole BJ. Triad of cartilage restoration for unicompartmental arthritis treatment in young patients: meniscus allograft transplantation, cartilage repair and osteotomy. *J Knee Surg.* 2009;22(2):137-141.

Gomoll AH, Probst C, Farr J, Cole BJ, Minas T. Use of a type VIII bilayer collagen membrane decreases reoperation rates for symptomatic hypertrophy after autologous chondrocyte implantation. *Am J Sports Med.* 2009;37(suppl 1):205-235.

Koyonos L, Yanke AB, McNickle AG, Kirk SS, Kang RW, Lewis PB, Cole BJ. A randomized, prospective, double-blind study to investigate the effectiveness of adding DepoMedrol to a local anesthetic injection in postmeniscectomy patients with osteoarthritis of the knee. *Am J Sports Med.* 2009;37(6):1077-1082.

Lewis PB, McCarty LP III, Yao JQ, Williams JM, Kang R, Cole BJ. Fixation of tissue-engineered human neocartilage constructs with human fibrin in a caprine model. *J Knee Surg.* 2009;22(3):196-204.

McNickle AG, L'Heureux DR, Yanke AB, Cole BJ. Outcomes of autologous chondrocyte implantation in a diverse patient population. *Am J Sports Med.* 2009;37(7):1344-1350.

Pascual-Garrido C, Slabaugh MA, L'Heureux DR, Friel NA, Cole BJ. Recommendations and treatment outcomes for patellofemoral articular cartilage defects with autologous chondrocyte implantation: prospective evaluation at average 4-year follow-up. *Am J Sports Med.* 2009;37(suppl 1):335-415.

#### Della Valle, Craig J.

Azzam K, Parvizi J, Jungkind D, Hanssen A, Fehring T, Springer B, Bozic K, Della Valle C, Pulido L, Barrack R. Microbiological, clinical, and surgical features of fungal prosthetic joint infections: a multi-institutional experience. *J Bone Joint Surg Am.* 2009;91(suppl 6):142-149.

Della Valle CJ, Mesko NW, Quigley L, Rosenberg AG, Jacobs JJ, Galante JO. Primary total hip arthroplasty with a porous-coated acetabular component: a concise follow-up, at a minimum of twenty years, of previous reports. *J Bone Joint Surg Am.* 2009;91(5):1130-1135.

Della Valle CJ, Nunley RM, Raterman SJ, Barrack RL. Initial American experience with hip resurfacing following FDA approval [published correction appears in *Clin Orthop Relat Res.* 2009;467(2):587]. *Clin Orthop Relat Res.* 2009;467(1):72-78.

Freeman TA, Parvizi J, Della Valle CJ, Steinbeck MJ. Reactive oxygen and nitrogen species induce protein and DNA modifications driving arthrofibrosis following total knee arthroplasty. *Fibrogenesis Tissue Repair.* 2009;2(1):5.

Levine BR, Della Valle CJ, Hamming M, Sporer SM, Berger RA, Paprosky WG. Use of the extended trochanteric osteotomy in treating prosthetic hip infection. *J Arthroplasty.* 2009;24(1):49-55.

Nunley RM, Della Valle CJ, Barrack RL. Is patient selection important for hip resurfacing? *Clin Orthop Relat Res.* 2009;467(1):56-65.

Park DK, Della Valle CJ, Quigley L, Moric M, Rosenberg AG, Galante JO. Revision of the acetabular component without cement: a concise follow-up, at twenty to twenty-four years, of a previous report [published correction appears in *J Bone Joint Surg Am*. 2009;91(12):2931]. *J Bone Joint Surg Am*. 2009;91(2):350-355.

#### Fischer, Alfons

Pourzal R, Theissmann R, Williams S, Gleising B, Fisher J, Fischer A. Subsurface changes of a MoM hip implant below different contact zones. *J Mech Behav Biomed Mater*. 2009;2(2):186-191.

#### Foucher, Kharma C.

Foucher KC, Hurwitz DE, Wimmer MA. Relative importance of gait vs. joint positioning on hip contact forces after total hip replacement. *J Orthop Res*. 2009;27(12):1576-1582.

Rojas IL, Provencher MT, Bhatia S, Foucher KC, Bach BR Jr, Romeo AA, Wimmer MA, Verma NN. Biceps activity during wind-mill softball pitching: injury implications and comparison with overhand throwing. *Am J Sports Med*. 2009;37(3):558-565.

#### Glant, Tibor T.

Végyvári A, Szabó Z, Szántó S, Glant TT, Mikecz K, Szekaneck Z. The genetic background of ankylosing spondylitis. *Joint Bone Spine*. 2009;76(6):623-628.

Wieten L, Berlo SE, Ten Brink CB, van Kooten PJ, Singh M, van der Zee R, Glant TT, Broere F, van Eden W. IL-10 is critically involved in mycobacterial HSP70 induced suppression of proteoglycan-induced arthritis. *PLoS One*. 2009;4(1):e4186.

#### Hallab, Nadim J.

Hallab NJ, Jacobs JJ. Biologic effects of implant debris. *Bull NYU Hosp Jt Dis*. 2009;67(2):182-188.

Kanaji A, Caicedo MS, Viridi AS, Sumner DR, Hallab NJ, Sena K. Co-Cr-Mo alloy particles induce tumor necrosis factor alpha production in MLO-Y4 osteocytes: a role for osteocytes in particle-induced inflammation. *Bone*. 2009;45(3):528-533.

#### Hammerberg, Kim W.

Nassr A, Larson AN, Crane B, Hammerberg KW, Sturm PF, Mardjetko SM. Iatrogenic thoracic outlet syndrome secondary to vertical expandable prosthetic titanium rib expansion thoracoplasty: pathogenesis and strategies for prevention/treatment. *J Pediatr Orthop*. 2009;29(1):31-34.

#### Inoue, Nozomu

Imai K, Tokunaga D, Takatori R, Ikoma K, Maki M, Ohkawa H, Ogura A, Tsuji Y, Inoue N, Kubo T. In vivo

three-dimensional analysis of hindfoot kinematics. *Foot Ankle Int*. 2009;30(11):1094-1100.

#### Jacobs, Joshua J.

Caicedo MS, Desai R, McAllister K, Reddy A, Jacobs JJ, Hallab NJ. Soluble and particulate Co-Cr-Mo alloy implant metals activate the inflammasome danger signaling pathway in human macrophages: a novel mechanism for implant debris reactivity. *J Orthop Res*. 2009;27(7):847-854.

Jacobs JJ, King T. US bone and joint decade prepares for the future. *Arthritis Rheum*. 2009;61(11):1470-1471.

Jacobs JJ, Urban RM, Hallab NJ, Skipor AK, Fischer A, Wimmer MA. Metal-on-metal bearing surfaces. *J Am Acad Orthop Surg*. 2009;17(2):69-76.

Turkelson C, Jacobs JJ. Role of technology assessment in orthopaedics. *Clin Orthop Relat Res*. 2009;467(10):2570-2576.

#### Levine, Brett

Levine B, Kaplanek B, Jaffe WL. Pilates training for use in rehabilitation after total hip and knee arthroplasty: a preliminary report. *Clin Orthop Relat Res*. 2009;467(6):1468-1475.

Troyer J, Levine BR. Proximal tibia reconstruction with a porous tantalum cone in a patient with Charcot arthropathy. *Orthopedics*. 2009;32(5):358.

#### Lin, Johnny L.

Lin J, Murphy GA. Treatment of hallux rigidus with cheilectomy using a dorsolateral approach. *Foot Ankle Int*. 2009;30(2):115-119.

Lin JL. Tendon transfers for Achilles reconstruction. *Foot Ankle Clin*. 2009;14(4):729-744.

#### Lundberg, Hannah J.

Brown TD, Lundberg HJ, Pedersen DR, Callaghan JJ. 2009 Nicolas Andry Award: clinical biomechanics of third body acceleration of total hip wear. *Clin Orthop Relat Res*. 2009;467(7):1885-1897.

Lundberg HJ, Foucher KC, Wimmer MA. A parametric approach to numerical modeling of TKR contact forces. *J Biomech*. 2009;42(4):541-545.

#### Mikecz, Katalin

Boldizsar F, Tarjanyi O, Nemeth P, Mikecz K, Glant TT. Th1/Th17 polarization and acquisition of an arthritogenic phenotype in arthritis-susceptible BALB/c, but not in MHC-matched, arthritis-resistant DBA/2 mice. *Int Immunol*. 2009;21(5):511-522.

Farkas B, Boldizsar F, Tarjanyi O, Laszlo A, Lin SM, Hutás G, Tryniszewska B, Mangold A, Nagyri G, Rosenzweig HL, Finnegan A, Mikecz K, Glant TT. BALB/c mice genetically susceptible to proteoglycan-induced arthritis and spondylitis show colony-dependent differences in disease penetrance. *Arthritis Res Ther*. 2009;11(1):R21.

Tarjanyi O, Boldizsar F, Nemeth P, Mikecz K, Glant TT. Age-related changes in arthritis susceptibility and severity in a murine model of rheumatoid arthritis. *Immun Ageing*. 2009;6:8.

#### Natarajan, Raghu N.

Bresnahan L, Ogden AT, Natarajan RN, Fessler RG. A biomechanical evaluation of graded posterior element removal for treatment of lumbar stenosis: comparison of a minimally invasive approach with two standard laminectomy techniques. *Spine*. 2009;34(1):17-23.

Hussain M, Natarajan RN, Fayyazi AH, Braaksma BR, Andersson GB, An HS. Screw angulation affects bone-screw stresses and bone graft load sharing in anterior cervical corpectomy fusion with a rigid screw-plate construct: a finite element model study. *Spine J*. 2009;9(12):1016-1023.

Ogden AT, Bresnahan L, Smith JS, Natarajan R, Fessler RG. Biomechanical comparison of traditional and minimally invasive intradural tumor exposures using finite element analysis. *Clin Biomech*. 2009;24(2):143-147.

Ruberté LM, Natarajan RN, Andersson GB. Influence of single-level lumbar degenerative disc disease on the behavior of the adjacent segments—a finite element model study. *J Biomech*. 2009;42(3):341-348.

#### Nho, Shane J.

Ghodadra N, Nho SJ, Verma NN, Reiff S, Piasecki DP, Provencher MT, Romeo AA. Arthroscopic decompression of the suprascapular nerve at the spinoglenoid notch and suprascapular notch through the subacromial space. *Arthroscopy*. 2009;25(4):439-445.

Kang RW, Frank RM, Nho SJ, Ghodadra NS, Verma NN, Romeo AA, Provencher MT. Complications associated with anterior shoulder instability repair. *Arthroscopy*. 2009;25(8):909-920.

Kepler CK, Nho SJ, Ala OL, Craig EV, Wright TM, Warren RF. Comparison of early and delayed failed total shoulder arthroplasty. *Acta Orthop Belg*. 2009;75(3):297-305.

Kepler CK, Nho SJ, Miller AN, Barie PS, Lyden JP. Orthopaedic injuries associated with fall from floor forty-seven. *J Orthop Trauma*. 2009;23(2):154-158.

Leunig M, Nho SJ, Turchetto L, Ganz R. Protrusio acetabuli: new insights and experience with joint preservation. *Clin Orthop Relat Res*. 2009;467(9):2241-2250.

Nho SJ, Brown BS, Lyman S, Adler RS, Altchek DW, MacGillivray JD. Prospective analysis of arthroscopic rotator cuff repair: prognostic factors affecting clinical and ultrasound outcome. *J Shoulder Elbow Surg*. 2009;18(1):13-20.

Nho SJ, Ghodadra N, Provencher MT, Reiff S, Romeo AA. Anatomic reduction and next-generation fixation constructs for arthroscopic repair of crescent, L-shaped, and U-shaped rotator cuff tears. *Arthroscopy*. 2009;25(5):553-559.

Nho SJ, Nam D, Ala OL, Craig EV, Warren RF, Wright TM. Observations on retrieved glenoid components from total shoulder arthroplasty. *J Shoulder Elbow Surg*. 2009;18(3):371-378.

Nho SJ, Provencher MT, Seroyer ST, Romeo AA. Bioabsorbable anchors in glenohumeral shoulder surgery. *Arthroscopy*. 2009;25(7):788-793.

Nho SJ, Reiff SN, Van Thiel GS, Romeo AA. Arthroscopic repair of L-shaped tear of the anterior band of the inferior glenohumeral ligament complex in a pediatric patient: a technical note. *Knee Surg Sports Traumatol Arthrosc*. 2009;17(12):1454-1457.

Nho SJ, Shindle MK, Adler RS, Warren RF, Altchek DW, MacGillivray JD. Prospective analysis of arthroscopic rotator cuff repair: subgroup analysis. *J Shoulder Elbow Surg*. 2009;18(5):697-704.

Nho SJ, Slabaugh MA, Seroyer ST, Grumet RC, Wilson JB, Verma NN, Romeo AA, Bach BR Jr. Does the literature support double-row suture anchor fixation for arthroscopic rotator cuff repair? A systematic review comparing double-row and single-row suture anchor configuration. *Arthroscopy*. 2009;25(11):1319-1328.

Yadav H, Nho S, Romeo A, MacGillivray JD. Rotator cuff tears: pathology and repair. *Knee Surg Sports Traumatol Arthrosc*. 2009;17(4):409-421.

#### Phillips, Frank M.

Allen RT, Rihn JA, Glassman SD, Currier B, Albert TJ, Phillips FM. An evidence-based approach to spine surgery. *Am J Med Qual*. 2009;24(suppl 6):15S-24S.

Phillips FM. Point of view. *Spine*. 2009;34(4):399.

Phillips FM, Allen TR, Regan JJ, Albert TJ, Cappuccino A, Devine JG, Ahrens JE, Hipp JA, McAfee PC. Cervical disc replacement in patients with and without previous adjacent level fusion surgery: a prospective study. *Spine*. 2009;34(6):556-565.

Phillips FM, Tzermiadianos MN, Voronov LI, Havey RM, Carandang G, Dooris A, Patwardhan AG. Effect of two-level total disc replacement on cervical spine kinematics. *Spine*. 2009;34(22):E794-799.

Phillips FM, Tzermiadianos MN, Voronov LI, Havey RM, Carandang G, Renner SM, Rosler DM, Ochoa JA, Patwardhan AG. Effect of the Total Facet Arthroplasty System after complete laminectomy-facetectomy on the biomechanics of implanted and adjacent segments. *Spine J*. 2009;9(1):96-102.

Rihn JA, Berven S, Allen T, Phillips FM, Currier BL, Glassman SD, Nash DB, Mick C, Crockard A, Albert TJ. Defining value in spine care. *Am J Med Qual*. 2009;24(suppl 6):4S-14S.

Rihn JA, Gates C, Glassman SD, Phillips FM, Schwender JD, Albert TJ. The use of bone morphogenetic protein in lumbar spine surgery. *Instr Course Lect*. 2009;58:677-688.

Smith HE, Rihn JA, Brodke DS, Guyer R, Coric D, Lonner B, Shelokov AP, Currier BL, Riley L, Phillips FM, Albert TJ. Spine care: evaluation of the efficacy and cost of emerging technology. *Am J Med Qual*. 2009;24(suppl 6):25S-31S.

#### Rauch, Tibor A.

Kuroda A, Rauch TA, Todorov I, Ku HT, Al-Abdullah IH, Kandeel F, Mullen Y, Pfeifer GP, Ferreri K. Insulin gene expression is regulated by DNA methylation [published correction appears in *PLoS One*. 2009;4(10). doi:10.1371/annotation/947a8d4a-3585-4b23-ac84-b47a255a70d9]. *PLoS One*. 2009;4(9):e6953.

Pfeifer GP, Rauch TA. DNA methylation patterns in lung carcinomas. *Semin Cancer Biol*. 2009;19(3):181-187.

Rauch TA, Pfeifer GP. The MIRA method for DNA methylation analysis. *Methods Mol Biol*. 2009;507:65-75.

Rauch TA, Wu X, Zhong X, Riggs AD, Pfeifer GP. A human B cell methylome at 100-base pair resolution. *Proc Natl Acad Sci U S A*. 2009;106(3):671-678.

Tubak V, Határvölgyi E, Krenács L, Korpos E, Kúsz E, Duda E, Monostori E, Rauch T. Expression of immunoregulatory tumor necrosis factor-like molecule TL1A in chicken chondrocyte differentiation. *Can J Vet Res*. 2009;73(1):34-38.

#### Romeo, Anthony A.

Baker CL III, Romeo AA. Combined arthroscopic repair of a type IV SLAP tear and Bankart lesion. *Arthroscopy*. 2009;25(9):1045-1050.

Ferry AT, Lee GH, Murphy R, Romeo AA, Verma NN. A long-head of biceps tendon rupture in a fast pitch softball player: a case report. *J Shoulder Elbow Surg*. 2009;18(1):e14-17.

Kuhne M, Boniquit N, Ghodadra N, Romeo AA, Provencher MT. The snapping scapula: diagnosis and treatment. *Arthroscopy*. 2009;25(11):1298-1311.

McNickle AG, L'Heureux DR, Provencher MT, Romeo AA, Cole BJ. Postsurgical glenohumeral arthritis in young adults. *Am J Sports Med*. 2009;37(9):1784-1791.

Piasecki DP, Romeo AA, Bach BR Jr, Nicholson GP. Suprascapular neuropathy. *J Am Acad Orthop Surg*. 2009;17(11):665-676.

Provencher MT, Ghodadra N, LeClere L, Solomon DJ, Romeo AA. Anatomic osteochondral glenoid reconstruction for recurrent glenohumeral instability with glenoid deficiency using a distal tibia allograft. *Arthroscopy*. 2009;25(4):446-452.

Provencher MT, Mologne TS, Romeo AA, Bradley JP. The use of rotator interval closure in the arthroscopic treatment of posterior shoulder instability. *Arthroscopy*. 2009;25(1):109-110.

#### Singh, Kern

Lee MJ, Dumonski M, Cahill P, Stanley T, Park D, Singh K. Percutaneous treatment of vertebral compression fractures: a meta-analysis of complications. *Spine*. 2009;34(11):1228-1232.

Singh K, Masuda K, Thonar EJ, An HS, Cs-Szabo G. Age-related changes in the extracellular matrix of nucleus pulposus and annulus fibrosus of human intervertebral disc. *Spine*. 2009;34(1):10-16.

#### Turner, Thomas M.

Turner, TM. Looking forward at veterinary total joint arthroplasty. *Vet Surg*. 2009;38(5):553-554.

#### Urban, Robert M.

Rodrigues DC, Urban RM, Jacobs JJ, Gilbert JL. In vivo severe corrosion and hydrogen embrittlement of retrieved modular body titanium alloy hip-implants. *J Biomed Mater Res B Appl Biomater*. 2009;88(1):206-219.

#### Verma, Nikhil N.

Ghodadra NS, Provencher MT, Verma NN, Wilk KE, Romeo AA. Open, mini-open, and all-arthroscopic rotator cuff repair surgery: indications and implications for rehabilitation. *J Orthop Sports Phys Ther*. 2009;39(2):81-99.

Lee GH, Kumar A, Berkson E, Verma N, Bach BR Jr, Hallab N. A biomechanical analysis of bone-patellar tendon-bone grafts after repeat freeze-thaw cycles in a cyclic loading model. *J Knee Surg*. 2009;22(2):111-113.

Piasecki DP, Verma NN, Romeo AA, Levine WN, Bach BR Jr, Provencher MT. Glenoid bone deficiency in recurrent anterior shoulder instability: diagnosis and management. *J Am Acad Orthop Surg*. 2009;17(8):482-493.

Provencher M, Ghodadra NS, Verma NN, Cole BJ, Zaire S, Shewman E, Bach BR Jr. Patellofemoral kinematics after limited resurfacing of the trochlea. *J Knee Surg*. 2009;22(4):310-316.

Van Thiel GS, Verma N, Yanke A, Basu S, Farr J, Cole B. Meniscal allograft size can be predicted by height, weight, and gender. *Arthroscopy*. 2009;25(7):722-727.

#### **Virkus, Walter W.**

Anglen J, Kyle RF, Marsh JL, Virkus WW, Watters WC III, Keith MW, Turkelson CM, Wies JL, Boyer KM. Locking plates for extremity fractures. *J Am Acad Orthop Surg*. 2009;17(7):465-472.

#### **Wang, Vincent M.**

Chou D, Wang V. Two-level en bloc spondylectomy for osteosarcoma at the cervicothoracic junction. *J Clin Neurosci*. 2009;16(5):698-700.

Fung DT, Wang VM, Andarawis-Puri N, Basta-Pljakic J, Li Y, Laudier DM, Sun HB, Jepsen KJ, Schaffler MB, Flatow EL. Early response to tendon fatigue damage accumulation in a novel in vivo model. *J Biomech*. 2010;43(2):274-279.

Fung DT, Wang VM, Laudier DM, Shine JH, Basta-Pljakic J, Jepsen KJ, Schaffler MB, Flatow EL. Subrupture tendon fatigue damage. *J Orthop Res*. 2009;27(2):264-273.

Huang CY, Wang VM, Flatow EL, Mow VC. Temperature-dependent viscoelastic properties of the human supraspinatus tendon. *J Biomech*. 2009;42(4):546-549.

McNickle AG, Wang VM, Shewman EF, Cole BJ, Williams JM. Performance of a sterile meniscal allograft in an ovine model. *Clin Orthop Relat Res*. 2009;467(7):1868-1876.

#### **Wimmer, Markus A.**

Braunstein V, Sprecher CM, Wimmer MA, Milz S, Taeger G. Influence of head size on the development of metallic wear and on the characteristics of carbon layers in metal-on-metal hip joints. *Acta Orthop*. 2009;80(3):283-290.

Ngai V, Wimmer MA. Kinematic evaluation of cruciate-retaining total knee replacement patients during level walking: a comparison with the displacement-controlled ISO standard. *J Biomech*. 2009;42(14):2363-2368.

Wimmer MA, Alini M, Grad S. The effect of sliding velocity on chondrocytes activity in 3D scaffolds. *J Biomech*. 2009;42(4):424-429.

#### **Wysocki, Robert W.**

Jupiter JB, Fernandez DL, Levin LS, Wysocki RW. Reconstruction of posttraumatic disorders of the forearm. *J Bone Joint Surg Am*. 2009;91(11):2730-2739.

Wysocki RW, Della Valle CJ, Shott S, Rosenberg AG, Berger RA, Galante JO. Revision of the acetabulum with a contemporary cementless component. *J Arthroplasty*. 2009;24(suppl 6):58-63.

Wysocki RW, Kapotas JS, Virkus WW. Intramedullary nailing of proximal and distal one-third tibial shaft fractures with intraoperative two-pin external fixation. *J Trauma*. 2009;66(4):1135-1139.

#### **Zhang, Yejia**

Zhang Y, Markova D, Im HJ, Hu W, Thonar EJ, He TC, An HS, Phillips FM, Anderson DG. Primary bovine intervertebral disc cells transduced with adenovirus overexpressing 12 BMPs and Sox9 maintain appropriate phenotype. *Am J Phys Med Rehabil*. 2009;88(6):455-463.

**SELECT RESEARCH GRANTS**

2008-2009

**Howard S. An, MD**

Comparison of C7 Fixation Techniques:  
Lateral, Transpedicular and Intralaminar  
OP-1 Injection Into Lumbar Disc for  
Degenerative Disc Disease  
Data Collection for Uninstrumented  
Posterolateral Fusions

**Gunnar B. J. Andersson, MD, PhD**

Interventional Disc Degeneration  
and Regeneration

**Mark S. Cohen, MD**

Retrospective Analysis of Radial Head  
Replacement With Bipolar Head

**Brian J. Cole, MD, MBA**

Post-Operative Outcomes of Double-Row  
Rotator Cuff Repair  
Treatment of Focal Articular Cartilage  
Lesions in the Femoral Condyle  
Cartilage Autograft Implantation for  
Lesions of the Knee  
Medial vs Lateral Supraspinatus  
Biomechanical and Histological Evaluation  
Gait Study Assessing New Unloading  
Knee Brace  
Performance of Cartilage Autograft  
Implantation for Articular Cartilage  
Migration of Chondrocytes in a Mouse Model  
Biosynthetic Matrix for Cartilage  
Regeneration in Microfracture Repair

**Craig J. Della Valle, MD**

Mini Incision and 2-Incision Total  
Hip Arthroplasty

**Tibor T. Glant, MD**

Study of Autoimmune Progressive Polyarthriti  
Autoimmune Arthritis: Genetics and Cellular  
Regulation  
Aggrecan-hG1 and LP Transgenic Mice as  
Models of Osteoarthritis  
Autoimmune Progressive Polyarthriti

**Nadim J. Hallab, PhD**

Fretting Corrosion Testing of Modular  
Acetabular Components

**Joshua J. Jacobs, MD**

Biotribological Layers in Metal-on-Metal  
Total Hip Replacements  
Systemic Implications of Total Joint  
Replacement  
Metal Ion Levels in Metal-on-Metal Disc  
Replacement

**Carl Maki, PhD**

Cellular Responses to p53 Activation  
by Nutlin-3a

**Koichi Masuda, MD**

Repair Intervertebral Disc in a Mature  
Rabbit Annular Puncture Model

**Katalin Mikecz, MD, PhD**

Mechanisms of Arthritis Suppression by TSG-6

**Frank M. Phillips, MD**

Stabilize Lumbar Spine With Stabilimax NZ vs  
Instrumented Fusions

**Kern Singh, MD**

Cervical Arthroplasty vs Anterior Cervical  
Discectomy and Fusion

**Thomas Turner, DVM**

Canine Osteoporotic Model for Synthetic Bone Graft Substitutes  
Development of an Ovine Cementless Knee Replacement Model  
Augmentation of Achilles Tendon Repair Using Porcine Dermis

**Robert M. Urban**

New Bone Formation in a Canine Critical Size Defect Model  
Faster-Setting Formulation of Injectable Bone Graft Substitute  
Bone Ingrowth Into Metallic Foam Materials With and Without Coating

Implant and Tissue Retrieval Studies

**Vincent M. Wang, PhD**

Effect of Drugs on Tendon Biomechanics and Glenohumeral Cartilage

**Markus A. Wimmer, PhD**

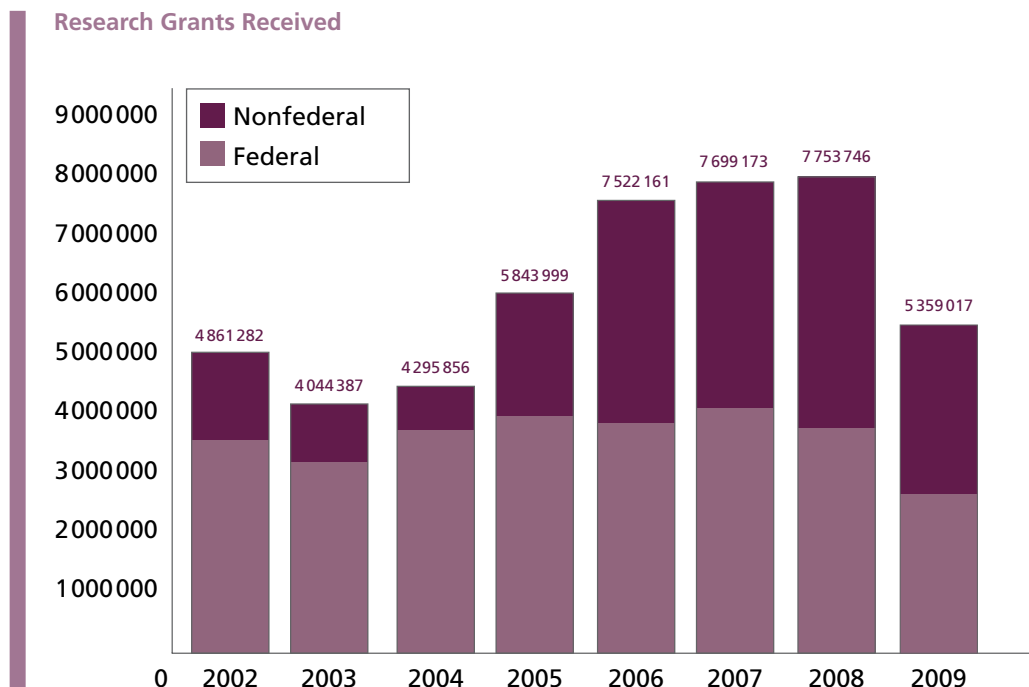
Daily Activity of TKR Patients as Input for Wear Testing  
In Vitro Wear Testing of Bovine Cartilage Against PEEK  
In Vitro Wear Testing of Living Cartilage Against Pyrolytic Carbon  
Monitoring of Daily Activities and Characterizing Related Contact Mechanics at the Knee in TKR Patients  
Wear Testing of Cartilage Friendly Materials  
Wear Determination of Orthopedic Polyethylene Materials Using a Tracer

**YeJia Zhang, MD, PhD**

Cell Therapy for the Degenerating Intervertebral Discs

**Qiping Zheng, PhD**

RO3 Grant  
Arthritis Investigator Award



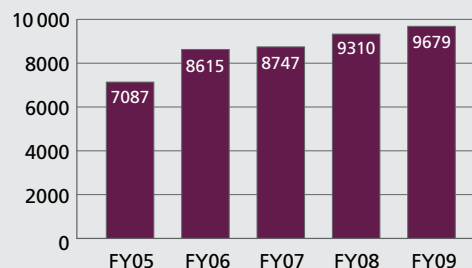
### ABOUT RUSH UNIVERSITY MEDICAL CENTER

Rush is a not-for-profit health care, education, and research enterprise located on the West Side of Chicago. Rush encompasses the academic medical center Rush University Medical Center, with a 676-bed hospital; the 128-bed Rush Oak Park Hospital; Rush University and Rush Health.

### QUALITY RECOGNITION

- For each of the last 5 years, Rush has been named in the top tier of “top performing hospitals” by the University HealthSystem Consortium (UHC) in its annual quality and safety benchmarking study of its member institutions. UHC is an alliance of approximately 90% of the nation’s academic medical centers.
- UHC has also awarded Rush the highest possible score for “equity of care” in each of the 5 years of its study. This ranking measures whether patients receive the same quality of treatment and have the same outcomes regardless of their gender, race, or socioeconomic status.
- Rush is consistently ranked by *U.S. News & World Report* as one of the top medical centers in the country.
- Rush’s nurses have twice been awarded Magnet status, the highest honor a hospital can receive for outstanding achievement in nursing services. Rush was the first medical center in Illinois caring for adults and children to receive this prestigious designation, and the first in Illinois to earn a second 4-year designation.
- Rush was selected as one of the 100 Top Hospitals in the United States by Thomson Reuters. The annual Thomson Reuters 100 Top Hospitals National Benchmarks study identifies the 100 best US hospitals based on their overall organizational performance. Rush was one of only 15 major teaching hospitals in the country to be named.
- Rush was named among the top hospitals in the country for quality, safety, and efficiency by the Leapfrog Group, a national organization that promotes health care safety and quality improvement. Rush is one of only 45 hospitals that made the top hospitals’ list for 2009 from among 1206 hospitals surveyed.

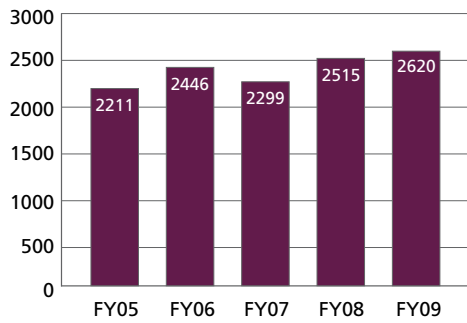
Total Orthopedic Surgical Cases



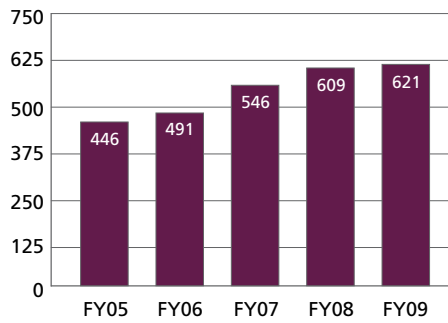


## Orthopedic Subspecialty Surgical Cases

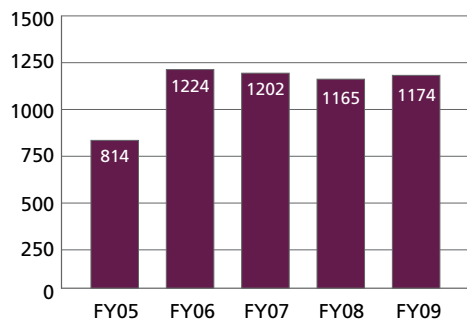
### Adult Reconstruction



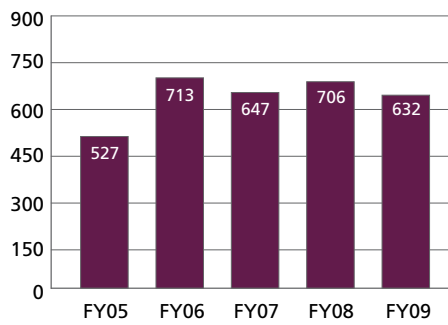
### Foot Surgery



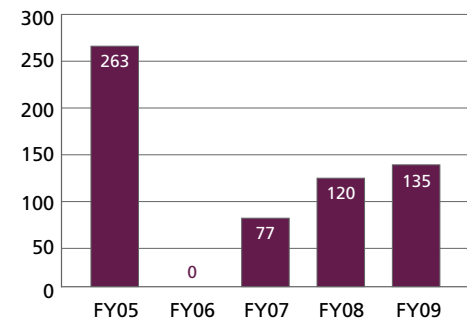
### Hand Surgery



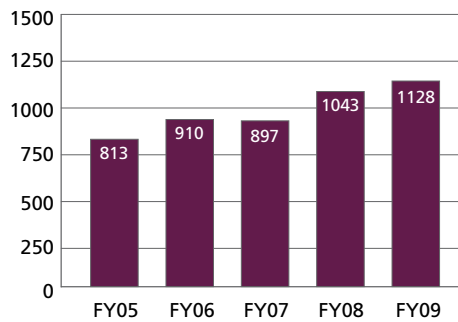
### Joint/Orthopedic Oncology & Trauma



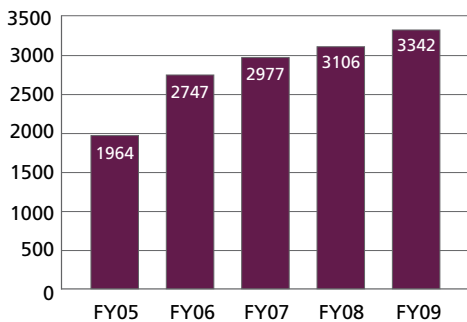
### Pediatrics



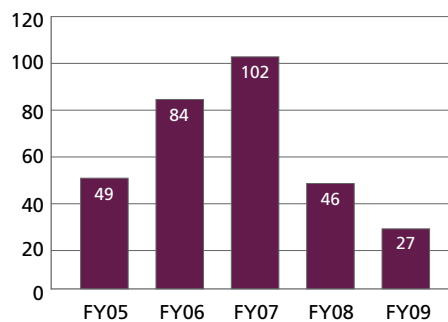
### Spine Surgery



### Sports Medicine



### Other



## LIFETIME ACHIEVEMENT: AN INTERVIEW WITH JOINT REPLACEMENT PIONEER JORGE O. GALANTE, MD, DMSc, BY CRAIG J. DELLA VALLE, MD

In March, former Department of Orthopedic Surgery Chairman Jorge O. Galante, MD, DMSc, was honored with the Lifetime Achievement Award from the Hip Society—a fitting tribute to an orthopedic surgeon who has earned worldwide recognition for his research and clinical contributions in the field of total hip and knee replacement.

It was Galante's vision of biologic fixation and his research into the feasibility of cementless components that led to the advent of cementless hip and knee implants, which are now used globally and have proven extremely durable over time. A 20-year follow-up study of one of the first cementless hips, the Harris-Galante-1 (HG-1) acetabular metal shell, was published in the February 2009 *Journal of Bone and Joint Surgery*. That study, led by Craig J. Della Valle, MD, an associate professor in the Department of Orthopedic Surgery, found that 95% of the implants remained fixed in place at a minimum follow-up of 20 years.

Della Valle recently sat down with Galante to talk about the past, present, and future of cementless hip and knee implants.

### **Della Valle: What were the specific problems with cement that led you to seek alternative methods of fixation?**

**Galante:** In the early days we did not have an understanding of all the technical issues involved with the use of cement. As time went on, two things became obvious: There were instances of loosening, and there was something which, at the time, people called "cement disease." It was actually osteolysis, which isn't related to cement at all, but to polyethylene wear. These difficulties we were encountering with cement prompted us to start looking at alternative methods of fixation.

### **Della Valle: And how did you conceive the concept of cementless implants?**

**Galante:** In 1968, after I returned from a visit with Sir John Charnley in England, I established a relationship with William Rostoker, PhD, who at that time was a professor in the Department of Materials Engineering at the University of Illinois. The premise I brought to Rostoker was this: Can we have an implant made of a porous material so bone can grow into the implant and fix it? Rostoker, who was an experienced metallurgist, came up with the idea of fiber metal technology, which was a way of making a porous material from metal fibers.

We focused on titanium because it was easier to use, and we had some idea of its biocompatibility, but we were not sure, as that information didn't exist yet in the '60s. The initial cemented implants were made of stainless steel and cobalt chrome alloy; titanium was not used extensively.

We did our first animal experiments in late 1968 to early 1969, and we found we could get bone to grow into these porous-coated implants. We presented the results at the American Academy of Orthopaedic Surgeons meeting in 1970 and published the study in 1971. We won a Kappa Delta Award for that work. That was really the beginning.



Jorge O. Galante, MD, DMSc (right), and Craig J. Della Valle, MD.

“It was Galante’s vision of biologic fixation and his research into the feasibility of cementless components that led to the advent of cementless hip and knee implants, which are now used globally and have proven extremely durable over time.”

**Della Valle: How did the research evolve from that point, leading up to the advent of Harris-Galante-1?**

**Galante:** By the end of the 1970s we felt pretty confident that we had an implant that was workable for a total hip replacement. We had established a collaboration with Zimmer, and they helped us develop more sophisticated models for dogs that really resembled the human hip, so we could see that what we were doing was going to be relevant to humans.

Interestingly, this all took place during the Vietnam War. There were a lot of wounded soldiers with large bone defects as a result of traumatic injuries, and we learned that the Army was looking for bone substitutes. So we started investigating that, and we developed a model of segmental replacement where we replaced missing bone with a segment that was titanium

and had titanium fiber metal fixation on the end. We implanted these in dogs and monkeys, and they proved to have very good biocompatibility. From there we did our first human implantations, which were custom-made prostheses for patients who had major bone loss due to malignancies. We probably implanted a dozen human patients, and we salvaged the limbs using these prosthetic devices.

Buttressed by this extensive research background, we started developing, with Zimmer, the concept of a totally cementless hip replacement that had a cementless acetabular component and a cementless femur. Zimmer teamed us up with William Harris, MD, and Dr Rostoker and I collaborated with him on the design of the Harris-Galante-1.

**Della Valle: Did you have high expectations when you implanted the first cementless hip?**

**Galante:** Absolutely. I knew at the time that this was pioneering work, but that first procedure was the culmination of more than a decade of research. We had tested the implant extensively in animal models. And before Harris-Galante-1, we had designed other investigational devices that we implanted in 100 to 150 patients with very good results. So even though we couldn't predict the long-term results, there was good evidence that the HG-1 could be successful.

**Della Valle: What were some of the issues with the first-generation implant that you addressed in subsequent versions?**

**Galante:** When the implant was introduced in 1982-1983, one thing we saw was that the porous coating technology worked. As the 20-year follow-up study showed, the fixation to bone of the HG-1 was extremely durable. The issues were related to the design of the prosthesis.

As time went on it became obvious that the main cause of failure was not fixation; it was that the polyethylene produces particles, and those particles destroy bone and cause loosening and failure. This has been an ongoing concern.

One significant issue with HG-1 was that the locking mechanism for the polyethylene insert in the cup wasn't very good. It didn't fix the insert well to the cup, and you ended up with some micromotion resulting in backside wear. We found out more recently that osteolysis, which we know is one of the main causes of implant failure, is correlated to wear on the back side of the cup. One of the major differences with the third-generation cup, which came out in the early 1990s, was that the locking mechanism was far superior, and the inner surface of the cup was much smoother, so if there was any motion, there would be less tendency for the generation of particles.

Another problem was with the design of the stem. Due to technical limitations at that time, the porous coating was not applied in a circumferential manner; it was applied only on the sides of the stem. This allowed polyethylene particles to migrate distally in the femoral canal and induce osteolysis and loosening. The failure rate at 10 years was not acceptable, so that aspect of the design was modified. We developed a prosthesis that followed the anatomy of the upper end of the femur and had porous coating applied in a circumferential manner. The long-term failure rate for this newer stem is extremely low.

**Della Valle: Did the cementless knee follow a similar developmental path?**

**Galante:** Our first cementless knees were implanted in humans around the same time as the HG-1, 1982-1983. By the early 1980s, based on our research, we had some novel ideas on

how to do total knees. Zimmer became interested in helping us develop this concept, and they put us in contact with Joe Miller, MD, who was the chairman at McGill University in Montreal and who had previously been on the staff here at Rush. Dr Miller had some original ideas as well about instrumentation and the design of the prosthesis. We combined our thoughts, and the result was one of the first cementless total knees, the Miller-Galante-1 (MG-1), which incorporated fiber metal technology. That knee was also available as a cemented implant.

**Della Valle: How did the cementless MG-1 perform compared to the cemented version?**

**Galante:** We found out that cementless and cemented fixation were equally successful on the femur. On the tibia, however, while there was no loosening with a cemented component, we were getting 2%-3% loosening with the cementless tibia. So after some experience, we chose to use cement on the tibia as our preferred method of fixation.

The main issue with MG-1 was that there were problems with the design of the patellofemoral joint that led to failure. So in the second generation, the MG-2, which was introduced in the late 1980s, we improved the design of the patellofemoral joint. And by 1993, we went on to a more modern implant for total knee that was similar in principle to the original versions, but with an improved patellofemoral joint, the possibility of increased flexion motion, and more size variations to fit patients more accurately than we were able to do initially. So we've made improvements, but the basic design principle of that first knee was sound, and they still function very well.

**Della Valle: What will be the challenges over the next decade for hip and knee replacement surgery?**

**Galante:** If you accept that fixation is not an issue for either hip or knee implants, then the real issues moving forward are wear and, with regard to knees, function.

We will continue to make improvements in the quality of bearings and their resistance to wear over the next decade. With knees, a big issue is that to have a knee implant that allows a higher level of function, you need to replicate normal kinematics, and that requires preserving both cruciate ligaments. There were some implant designs in the early '90s that preserved both cruciate ligaments, but they never became popular due to design and related surgical technique issues. There is also a lot of ongoing work on wear-resistant-materials development for knees. The materials that are good for hips are not necessarily good for knees because the mechanical environment is very different. The ideal material will probably be some variation of polyethylene, but there is still a fair amount of development to be done in that area.

