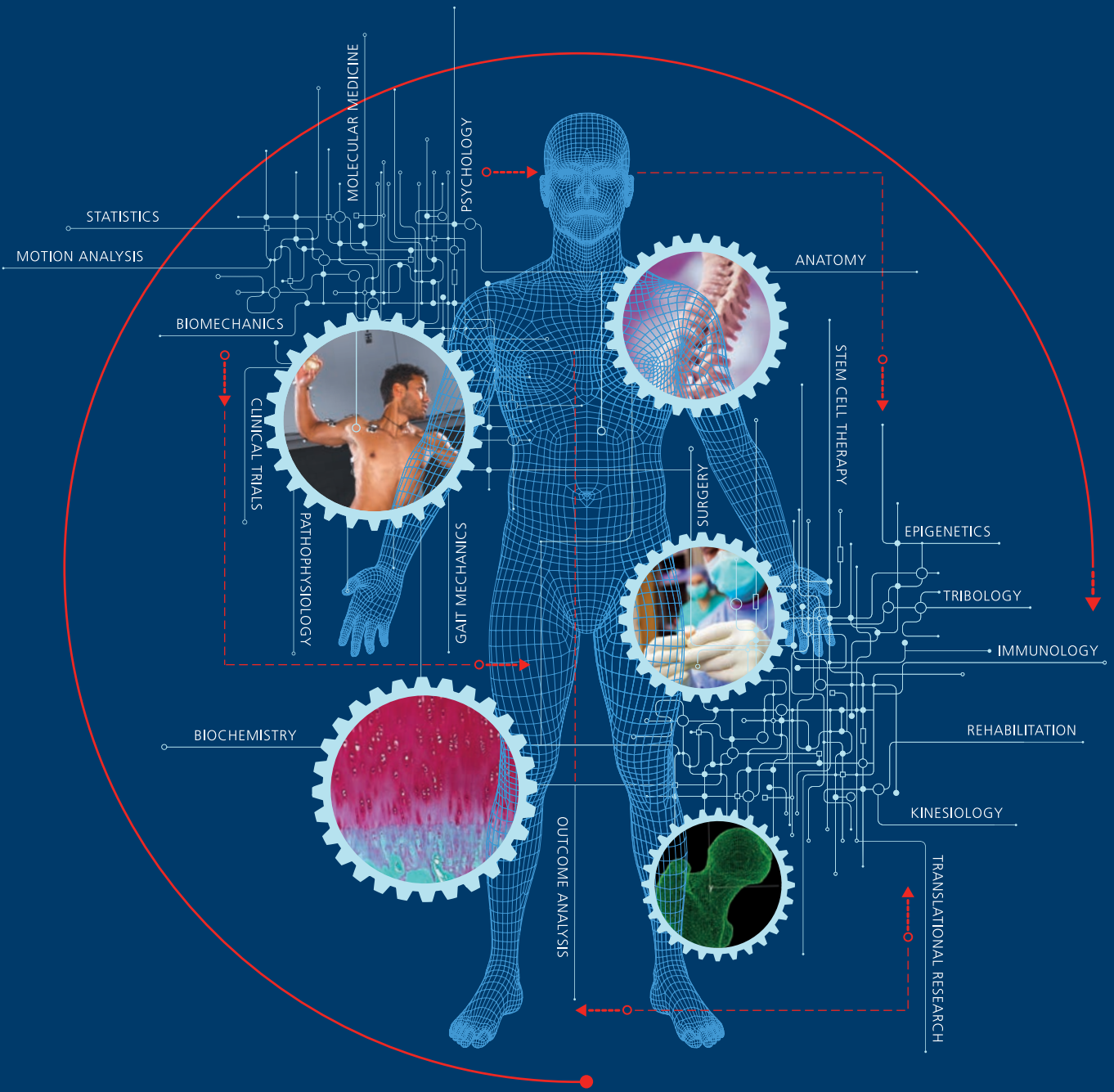

2015

Rush Orthopedics Journal

 RUSH UNIVERSITY
MEDICAL CENTER



MEETING OF THE MINDS. At Rush, it's not unusual to see orthopedic surgeons and basic scientists deep in conversation, given the Department of Orthopedic Surgery's emphasis on bench-to-bedside research. In this issue of the *Rush Orthopedics Journal*, a group of surgeons and scientists invites you into the discussion as they open up about the rewards and challenges of translational research—including the remarkable ability to transform lives. Join their roundtable discussion starting on page 57.

FACULTY EDITORS

David Fardon, MD | EDITOR IN CHIEF

Brett Levine, MD, MS | DEPUTY EDITOR

Shane J. Nho, MD, MS | DEPUTY EDITOR

Robert W. Wysocki, MD | ASSOCIATE EDITOR

Adam Yanke, MD | ASSOCIATE EDITOR

Peter N. Chalmers, MD | RESIDENT EDITOR

Steven Gitelis, MD | EDITOR EMERITUS

02 | CHAIRMAN'S LETTER

03 | ORTHOPEDIC FACULTY AND FELLOWS

07 | RESEARCH FACULTY

10 | DEPARTMENT OF ORTHOPEDIC SURGERY RESIDENTS

11 | GUNNAR B. J. ANDERSSON RETIRES

12 | Collaborative Clinical and Basic Research in Arthritis Treatment: A Young Woman Benefits from 10 Years of Bench-to-Bedside Research at Rush

Brian J. Cole, MD, MBA; Annemarie K. Tilton, BS; Rachel M. Frank, MD; Susan Chubinskaya, PhD; Markus A. Wimmer, PhD; Nikhil N. Verma, MD; Adam Yanke, MD

17 | Aneurysmal Bone Cyst of the Thoracic Spine: A Case Report and Review of Literature

Andrew Sexton, BS; Philip K. Louie, MD; Ehsan Tabaraee, MD; David Fardon, MD; Matthew W. Colman, MD

21 | Management of Isolated Greater Tuberosity Fractures: A Systematic Review

David M. Levy, MD; Brandon J. Erickson, MD; Joshua D. Harris, MD; Bernard R. Bach Jr, MD; Nikhil N. Verma, MD; Anthony A. Romeo, MD

26 | The Effect of Simulator Training on Safety and Clinical Performance of Common Upper Extremity Procedures

Rachel M. Frank MD; Laith Al-Shihabi, MD; Brandon Erickson, MD; Robert W. Wysocki, MD; Brett Levine, MD, MS

30 | Correcting Sagittal Imbalance: A Retrospective Radiographic Study of Decompression and Local Fusion in Cases of Degenerative Scoliosis

Philip K. Louie, MD; Steven Presciutti, MD; Sarah Johnson, BS; Ehsan Tabaraee, MD; Thomas Cha, MD; Howard S. An, MD

35 | Pigmented Villonodular Synovitis of the Hip: A Systematic Review

David M. Levy, MD; Bryan D. Haughom, MD; Shane J. Nho, MD, MS; Steven Gitelis, MD

40 | Anterior Cage Reconstruction Improves Stiffness and Decreases Cancellous Subsidence in a Spondylectomy Model

Matthew W. Colman, MD; Andrew Guss, MS; Kent Bachus, PhD; W. Ryan Spiker, MD; Brandon D. Lawrence, MD; Ehsan Tabaraee, MD; Darrel S. Brodke, MD

43 | Detection of Traumatic Arthrotomy Using the Saline Load Test

Rachel M. Frank, MD; William Slikker III, MD; Simon X. Lee, MPH; Johnny Lin, MD; John J. Fernandez, MD; Robert W. Wysocki, MD; Mark S. Cohen, MD; David Garras, MD; Simon Lee, MD

48 | Computed Tomography for the Diagnosis of Periprosthetic Sepsis

Peter N. Chalmers, MD; Herman G. Botero, DO; John Meyer, DO; Jonathan M. Frank, MD; Scott M. Sporer, MD, MS; Brett Levine, MD, MS

53 | Development of the Modern Total Hip Arthroplasty: Part II

Nicholas Brown, MD; David Fardon, MD; Gunnar B. J. Andersson, MD, PhD

57 | SELECT PUBLICATIONS 2014

63 | Six Degrees of Collaboration

A roundtable discussion about the role of translational research in medicine, and the collaboration between physician-researchers and basic scientists at Rush
Howard S. An, MD; Susan Chubinskaya, PhD; Brian J. Cole, MD, MBA; Craig J. Della Valle, MD; Nozomu Inoue, MD, PhD; and Markus A. Wimmer, PhD

To view the 2015 *Rush Orthopedics Journal* online or to view past issues of the journal, please visit www.rush.edu/orthopedicsjournal.

Chairman's Letter



Given recent advances in biotechnology—particularly in bioinformatics, or “big data”—the biomedical research enterprise is on the brink of making major advances in the way we understand and treat disease.

One example is the concept of “precision medicine,” a personalized approach to disease treatment and prevention that takes into account individual variability in genes, environment, and lifestyle for each individual.

After President Obama mentioned his new precision medicine initiative during his State of the Union address, National Institutes of Health Director Francis Collins, MD, PhD, and National Cancer Institute Director Harold Varmus, MD, published an editorial in the *New England Journal of Medicine* in which they addressed the potential role precision medicine can play in the future.

Add to that the rapid progress in other areas, such as regenerative medicine and nanotechnology, and it becomes evident that a technological renaissance in orthopedics is at hand. This means the outlook for creating new strategies to address musculoskeletal diseases is extremely bright.

While the transformation of orthopedic health care to a paradigm of individualized or personalized treatment is currently an aspirational goal, it is within our reach.

Our researchers envision a time in the not-too-distant future when specific treatments will be able to be tailored to the patient’s particular characteristics based on an array of biomarkers—including the genome, proteome, microbiome, and individual biomechanical profiles. These tools will be valuable adjuncts to the orthopedic surgeon’s arsenal, enabling us to more accurately predict which treatments will yield optimal results.

In the meantime, our faculty continue to leverage new research findings to provide pathways for people afflicted with musculoskeletal diseases or injury to once again lead full, active lives. You can read one compelling example of the transformative power of translational research at Rush starting on page 12. And in our “roundtable” discussion on page 57, you will hear from a group of physicians and scientists about their research partnerships, their passion for discovery, and the challenges—including funding—that they face in their ongoing efforts to move orthopedic care forward. [O](#)

A handwritten signature in black ink, appearing to read 'Joshua J. Jacobs'.

Joshua J. Jacobs, MD
The William A. Hark, MD/Susanne G. Swift Professor of
Orthopedic Surgery
Chairman, Department of Orthopedic Surgery
Rush University Medical Center

Orthopedic Faculty and Fellows

ADULT RECONSTRUCTIVE SURGERY



Aaron Rosenberg, MD
Director, Division of Adult Reconstructive Surgery
Professor, Department of Orthopedic Surgery
Director, Adult Reconstructive Orthopedic Surgery Fellowship Program



Joshua J. Jacobs, MD
The William A. Hark, MD/Susanne G. Swift
Professor of Orthopedic Surgery
Chairman, Department of Orthopedic Surgery



Richard A. Berger, MD
Director, Section of Minimally Invasive Surgery
Assistant professor, Department of Orthopedic Surgery



Brett Levine, MD, MS
Assistant professor, Department of Orthopedic Surgery




Craig J. Della Valle, MD
Director, Section of Research
Professor, Department of Orthopedic Surgery
Associate director, Orthopedic Surgery Residency Program



Wayne G. Paprosky, MD
Professor, Department of Orthopedic Surgery



Jorge O. Galante, MD, DMSc
The Grainger Director of the Rush Arthritis and Orthopedics Institute
Professor, Department of Orthopedic Surgery



Scott M. Sporer, MD, MS
Director, Section of Quality and Outcomes
Associate professor, Department of Orthopedic Surgery



Tad L. Gerlinger, MD
Associate professor, Department of Orthopedic Surgery

FELLOWS

Brian Culp, MD

Medical school – The Ohio State University
Residency – Rutgers Robert Wood Johnson University Hospital

Michael Flierl, MD

Medical school – Technical University Munich, Germany
Residency – University of Colorado Hospital

Dane Hansen, DO

Medical school – Des Moines University College of Osteopathic Medicine
Residency – Doctors Hospital/Ohio University

Uel Hansen, MD

Medical school – Chicago Medical School
Residency – William Beaumont Army Medical Center

David Kaufman, MD

Medical school – University of California, San Francisco, School of Medicine
Residency – Stanford University Medical Center

Andrew Park, MD

Medical school – University of Virginia School of Medicine
Residency – Washington University in St. Louis

Brian Park, MD

Medical school – Albert Einstein College of Medicine
Residency – NYU Langone Medical Center/Hospital for Joint Diseases


ELBOW, WRIST, AND HAND SURGERY



Mark S. Cohen, MD
Director, Section of Hand and Elbow Surgery
Professor, Department of Orthopedic Surgery



Robert W. Wysocki, MD
Assistant professor, Department of
Orthopedic Surgery



John J. Fernandez, MD
Assistant professor, Department of
Orthopedic Surgery

HAND, UPPER EXTREMITY, AND MICROVASCULAR FELLOWSHIP

Joseph Morgan, MD
Medical school – Indiana University School of Medicine
Residency – University of Missouri


FOOT AND ANKLE SURGERY



George Holmes Jr, MD
Director, Section of Foot and Ankle Surgery
Associate Professor, Department of
Orthopedic Surgery



Johnny L. Lin, MD
Assistant professor, Department of
Orthopedic Surgery



Simon Lee, MD
Assistant professor, Department of
Orthopedic Surgery

FELLOW

Adam Bitterman, DO
Medical school – New York College of Osteopathic Medicine
Residency – University of Pittsburgh Medical Center

ONCOLOGY




Steven Gitelis, MD
Director, Section of Orthopedic Oncology
Rush University Professor of
Orthopedic Oncology
Professor, Department of Orthopedic Surgery



Matthew W. Colman, MD
Assistant professor, Department of
Orthopedic Surgery

ONCOLOGY AND SPINE SURGERY

PEDIATRIC ORTHOPEDIC SURGERY



Monica Kogan, MD

Director, Section of Pediatric Orthopedic Surgery
Assistant professor, Department of
Orthopedic Surgery
Director, Orthopedic Surgery Residency Program

SPINE SURGERY




Howard S. An, MD

Director, Division of Spine Surgery
The Morton International Chair of
Orthopedic Surgery
Professor, Department of Orthopedic Surgery
Director, Spine Surgery Fellowship Program



Edward J. Goldberg, MD

Assistant professor, Department of
Orthopedic Surgery



Gunnar B. J. Andersson, MD, PhD

The Ronald L. DeWald, MD, Endowed Chair in
Spinal Deformities
Professor and chairman emeritus, Department of
Orthopedic Surgery



Kim W. Hammerberg, MD

Assistant professor, Department of
Orthopedic Surgery



Christopher DeWald, MD

Assistant professor, Department of
Orthopedic Surgery



Frank M. Phillips, MD

Director, Section of Minimally Invasive
Spine Surgery
Professor, Department of Orthopedic Surgery



David Fardon, MD

Assistant professor, Department of
Orthopedic Surgery



Kern Singh, MD

Associate professor, Department of
Orthopedic Surgery

FELLOWS

Gregory Lopez, MD

Medical school – University of Texas-San Antonio School of Medicine
Residency – University of California, Irvine, Medical Center

Grant Shiflett, MD

Medical school – Keck School of Medicine of USC
Residency – Hospital for Special Surgery

Alem Yacob, MD

Medical school – University of Michigan Medical School
Residency – Yale-New Haven Hospital

SPORTS MEDICINE, SURGERY



Bernard R. Bach Jr, MD

Director, Division of Sports Medicine
The Claude N. Lambert, MD/Helen S. Thomson
Professor of Orthopedic Surgery
Professor, Department of Orthopedic Surgery
Director, Sports Medicine Fellowship Program



Charles A. Bush-Joseph, MD

Professor, Department of Orthopedic Surgery




Brian J. Cole, MD, MBA

Director, Rush Cartilage Restoration Center
Associate chairman for academic affairs and
professor, Department of Orthopedic Surgery



Brian Forsythe, MD

Assistant professor, Department of
Orthopedic Surgery



Shane J. Nho, MD, MS

Director, Section of Young Adult Hip Surgery
Assistant professor, Department of
Orthopedic Surgery




Gregory Nicholson, MD

Associate professor, Department of
Orthopedic Surgery



Anthony A. Romeo, MD

Director, Section of Shoulder and
Elbow Surgery
Professor, Department of Orthopedic Surgery



Nikhil N. Verma, MD

Director, Section of Clinical Research
Associate professor, Department of
Orthopedic Surgery



Adam Yanke, MD

Assistant professor, Department
of Orthopedic Surgery

FELLOWS

Justin Griffin, MD

Medical school – Loyola University Stritch School of Medicine
Residency – University of Virginia

Timothy Leroux, MEd, MD

Medical school – University of Toronto Faculty of Medicine
Residency – University of Toronto

Eric Makhni, MD, MBA

Medical school – Harvard Medical School
Residency – Columbia University Medical Center

Mark McCarthy, MD

Medical school – University of Minnesota Medical School
Residency – University of Iowa

Alexander Weber, MD

Medical school – University of Buffalo School of Medicine and
Biomedical Sciences
Residency – University of Michigan

SHOULDER SURGERY FELLOW

Robert Thorsness, MD

Medical school – Washington University School of Medicine
in St. Louis
Residency – University of Rochester Medical Center

SPORTS MEDICINE, PRIMARY CARE



Kathleen M. Weber, MD

Director, Primary Care/Sports Medicine Program
Assistant professor, Department of
Orthopedic Surgery



Julia Bruene, MD

Assistant professor, Department of Orthopedic
Surgery and Department of Family Medicine



Joshua Blomgren, DO

Assistant professor, Department of
Family Medicine and Department of
Orthopedic Surgery



Jeffrey M. Mjaanes, MD

Assistant professor, Department of Orthopedic
Surgery and Department of Pediatrics

FELLOW

Jeremy Alland, MD

Medical school – Rush Medical College

Residency – University of Pittsburgh Medical Center

ORTHOPEDIC PHYSICAL MEDICINE AND REHABILITATION



April M. Fetzer, DO

Assistant professor, Department of
Orthopedic Surgery and Department of
Physical Medicine and Rehabilitation



David S. Cheng, MD

Assistant professor, Department of Orthopedic
Surgery and Department of Physical Medicine
and Rehabilitation

Research Faculty

THE ROBBINS AND JACOBS FAMILY BIOCOMPATIBILITY AND IMPLANT PATHOLOGY LABORATORY



Robert M. Urban

Director, the Robbins and Jacobs Family
Biocompatibility and Implant Pathology
Laboratory

Associate professor, Department of
Orthopedic Surgery



Robin Pourzal, PhD

Instructor, Department of Orthopedic Surgery



Deborah J. Hall

Instructor, Department of Orthopedic Surgery



Thomas M. Turner, DVM

Associate professor, Department of
Orthopedic Surgery

BIOMATERIALS LABORATORY



Nadim J. Hallab, PhD
Director, Section of Biomaterials and
Biomaterials Laboratory
Professor, Department of Orthopedic Surgery



Anastasia Skipor, MS
Instructor, Department of Orthopedic Surgery

SECTION OF MOLECULAR MEDICINE



Tibor T. Glant, MD, PhD
Director, Section of Molecular Medicine
The Jorge O. Galante, MD, DMSc, Chair in
Orthopaedic Surgery
Professor, Department of Orthopedic Surgery



Katalin Mikecz, MD, PhD
Professor, Department of Orthopedic Surgery

Not pictured:

Tibor A. Rauch, PhD, associate professor, Department of Orthopedic Surgery

THE JOAN AND PAUL RUBSCHLAGER MOTION ANALYSIS LABORATORY



Markus A. Wimmer, PhD
Director, the Joan and Paul Rubschlagger Motion
Analysis Laboratory
Director, the Joan and Paul Rubschlagger
Tribology Laboratory
Associate chairman for research and professor,
Department of Orthopedic Surgery

SECTION OF ORTHOPEDIC ONCOLOGY



Carl Maki, PhD
Associate professor, Department of Anatomy and
Cell Biology



Qiping Zheng, PhD
Assistant professor, Department of Anatomy and
Cell Biology

SPINE RESEARCH LABORATORY

SPINE BIOMECHANICS




Nozomu Inoue, MD, PhD
Professor, Department of Orthopedic Surgery



Alejandro A. Espinoza Orías, PhD
Instructor, Department of Orthopedic Surgery

SPINE BIOMECHANICS; CAD/COMPUTER ANALYSIS



Raghu N. Natarajan, PhD
Professor, Department of Orthopedic Surgery

THE JOAN AND PAUL RUBSCHLAGER TRIBOLOGY LABORATORY



Markus A. Wimmer, PhD
Director, the Joan and Paul Rubschlager
Tribology Laboratory
Director, the Joan and Paul Rubschlager Motion
Analysis Laboratory
Associate chairman for research and professor,
Department of Orthopedic Surgery



Hannah J. Lundberg, PhD
Assistant professor, Department of
Orthopedic Surgery



Alfons Fischer, PhD
Visiting professor, Department of
Orthopedic Surgery



Mathew T. Mathew, PhD
Assistant professor, Department of
Orthopedic Surgery

Not pictured:

Joachim Kunze, PhD, visiting instructor, Department of Orthopedic Surgery

Michel Laurent, PhD, scientist, Department of Orthopedic Surgery

Department of Orthopedic Surgery Residents

CLASS OF 2015

Laith M. Al-Shihabi, MD

Medical school – Medical College of Wisconsin

Peter N. Chalmers, MD

Medical school – Columbia University College of Physicians and Surgeons

Jonathan M. Frank, MD

Medical school – David Geffen School of Medicine at UCLA

William Slikker III, MD

Medical school – Stanford University School of Medicine

David M. Walton, MD

Medical school – Case Western Reserve University School of Medicine

CLASS OF 2016

Nicholas M. Brown, MD

Medical school – Columbia University College of Physicians and Surgeons

Rachel M. Frank, MD

Medical school – Northwestern University Feinberg School of Medicine

Bryan D. Haughom, MD

Medical school – University of California, San Francisco, School of Medicine

Michael D. Hellman, MD

Medical school – Jefferson Medical College of Thomas Jefferson University

Andrew J. Riff, MD

Medical school – Georgetown University School of Medicine

CLASS OF 2017

Gregory L. Cvetanovich, MD

Medical school – Harvard Medical School

Brandon J. Erickson, MD

Medical school – Tufts University School of Medicine

Yale A. Fillingham, MD

Medical school – Rush Medical College

David M. Levy, MD

Medical school – Columbia University College of Physicians and Surgeons

Nathan G. Wetters, MD

Medical school – University of Illinois College of Medicine at Rockford

CLASS OF 2018

Bonnie P. Gregory, MD

Medical school – University of Louisville School of Medicine

Molly C. Meadows, MD

Medical school – Columbia University College of Physicians and Surgeons

Bryan M. Saltzman, MD

Medical school – Rush Medical College

Robert A. Sershon, MD

Medical school – Rush Medical College

Matthew W. Tetreault, MD

Medical school – University of Pittsburgh School of Medicine

CLASS OF 2019

Joshua Bell, MD

Medical school – Medical College of Georgia at Georgia Regents University

Kevin Campbell, MD

Medical school – University of Wisconsin School of Medicine and Public Health

Philip Louie, MD

Medical school – University of Washington School of Medicine

Timothy Luchetti, MD

Medical school – Columbia University College of Physicians and Surgeons

Allison Rao, MD

Medical school – Stanford University School of Medicine

CLASS OF 2020

Brian A. Basques, MD

Medical school – Yale University School of Medicine

Daniel D. Bohl, MD, MPH

Medical school – Yale University School of Medicine

Islam Elboghhdady, MD

Medical school – Rush Medical College

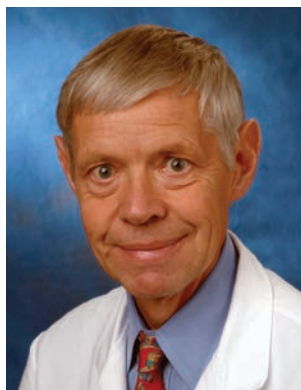Charles Hannon, MD

Medical school – Georgetown University School of Medicine

Mick Kelly, MD

Medical school – University of Wisconsin School of Medicine and Public Health

Gunnar B. J. Andersson Retires



We welcome Gunnar Andersson's visits. We miss his regular contributions to the clinics and conferences, and the pleasure of passing him daily in the halls. Gunnar retired in 2015 after 30 years on the faculty at Rush. Rush is—forever—the beneficiary of his tenure.

Gunnar Andersson, MD, PhD, truly embodies the spirit of discovery, collaboration, and excellence that is the theme of this year's *Rush Orthopedics Journal*.

Before moving to the US from his native Sweden, Gunnar was a visiting distinguished professor at Rush. He collaborated with Jorge O. Galante, MD, DMSc, whose contributions to Rush and to translational research are cited in this journal (Brown, 2015, pages 53-56; and Della Valle, 2010, pages 68-70). Dr Galante, chairman of the Department of Orthopedic Surgery from its founding in 1972, brought Gunnar to Rush in 1985. In 1994, Dr Galante became Grainger Director of the Rush Arthritis and Orthopedics Institute and Gunnar became the William A. Hark, MD/Suzanne G. Swift Professor of Orthopedic Surgery and department chairman.

While Gunnar's initial efforts were spread across the orthopedic subspecialties, his work evolved to subspecialization in spine. He coordinated his interests and education in mechanics and engineering with his training in surgery. He perceived the need for better understanding of the human spine as it applied to the needs of workers and industry. Famously, he designed the seats for Volvo. However, his administrative talents and ability to collaborate and translate his work into multiple applications made his influence far-reaching and enduring.

While maintaining an active clinical practice and leading his group and his department, he built a curriculum vitae far thicker than this volume, including—at last count—330 original papers, 530 abstracts, and 160 books and book chapters. He has been a member of 17 editorial boards, on many of which he still serves. He has been president of 4 major, international organizations of spine care physicians. At Rush, he has been president of the medical staff, a trustee, senior vice-president of medical affairs, and vice-dean for surgical services. Gunnar conceived of and was instrumental in the planning of the Orthopedic Building on the Rush campus. And this year, Rush University awarded him the Trustee Medal, Rush's highest honor.

Through caring for patients, teaching, writing, editing, collaborative clinical and laboratory research, leadership, and being a friend and inspiration to his colleagues, Gunnar has made so many important contributions to Rush over the last 3 decades. Thanks to his efforts, orthopedic specialists at Rush now—and for generations to come—have the facilities, environment, and opportunities to treat, to teach, to learn, to discover, to collaborate, and to thrive.

Thank you, Gunnar.

Skol!



David Fardon
Editor in Chief

“Too young for arthroplasty but often too symptomatic and high-demand to simply manage, young patients with articular cartilage deficiencies are very much in need of joint preservation strategies...”

Collaborative Clinical and Basic Research in Arthritis Treatment

A Young Woman Benefits from 10 Years of Bench-to-Bedside Research at Rush

BRIAN J. COLE, MD, MBA / ANNEMARIE K. TILTON, BS / RACHEL M. FRANK, MD / SUSAN CHUBINSKAYA, PHD
MARKUS A. WIMMER, PHD / NIKHIL N. VERMA, MD / ADAM YANKE, MD

AUTHOR AFFILIATIONS

Department of Orthopedic Surgery (Drs Cole, Frank, Wimmer, Verma, and Yanke; and Ms Tilton) and Department of Biochemistry (Dr Chubinskaya), Rush University Medical Center and Midwest Orthopaedics at Rush (Drs Cole, Verma, and Yanke), Chicago, Illinois.

CORRESPONDING AUTHOR

Brian J. Cole, MD, MBA, Department of Orthopedic Surgery, Rush University Medical Center and Midwest Orthopaedics at Rush, 1611 W Harrison St., Suite 300, Chicago, IL 60612 (brian.cole@rushortho.com).

INTRODUCTION

Having orthopedic clinical subspecialists and basic science researchers in the same facility, with easy access to one another, fosters a multidisciplinary approach that can provide solutions to patients whose situations otherwise seem hopeless. In turn, these patients stimulate clinicians and scientists to seek new ways to address unsolved orthopedic problems. As an example, we present the case of a young lady whose function and outlook on life were restored by such collaboration at our institution.

CASE REPORT

An 8-year-old girl injured her left knee while doing a cartwheel. Her first operation consisted of a left knee arthroscopy with articular cartilage debridement. Unfortunately, her recovery was complicated by a deep intra-articular staph infection. Over the subsequent 10 years, she underwent 8 additional operations to eradicate the infection and remove damaged cartilage.

Despite repeated surgical interventions, she continued to have debilitating pain and loss of function. At the age of 18, she was referred by her treating orthopedic surgeon to Midwest Orthopaedics at Rush for an alternative to joint replacement surgery. During initial clinical evaluation by our team, she stated that her condition was deteriorating and that she had been unable to engage in athletics, navigate stairs, or ride a bicycle. Her father and grandfather had been volunteer firefighters, and it was her desire to someday join them in that pursuit.

Magnetic resonance imaging (MRI) (Figure 2) demonstrated mild bone marrow edema in the proximal medial tibial plateau, a full-thickness chondral defect of the posterior medial femoral condyle with

associated mild bone marrow edema, and evidence of a prior partial meniscectomy.

Standard radiographs, including long-leg alignment films (Figure 3), revealed neutral alignment, an irregular appearance to the medial femoral condyle with small osteophyte formation, and a corresponding irregular appearance to the medial tibial plateau with mild subchondral sclerosis.

Because she had relatively localized medial symptoms, we performed fresh medial femoral condyle osteochondral allograft transplantation and a microfracture of the medial tibial plateau (Figure 1).

One year postoperatively, the patient noted a significant reduction in pain and profound improvements in overall function (Figure 4). She had clinically meaningful improvements in Lysholm (22 to 61), International Knee Documentation Committee (IKDC, 15 to 71), Knee Injury Osteoarthritis Outcome Score (KOOS) pain (20 to 94), KOOS Sports (0 to 65), and KOOS Function in daily living (ADL) (34 to 99). She was able to cycle, climb stairs, and ultimately, engaged in a vigorous exercise program intended to prepare her to be a volunteer firefighter.

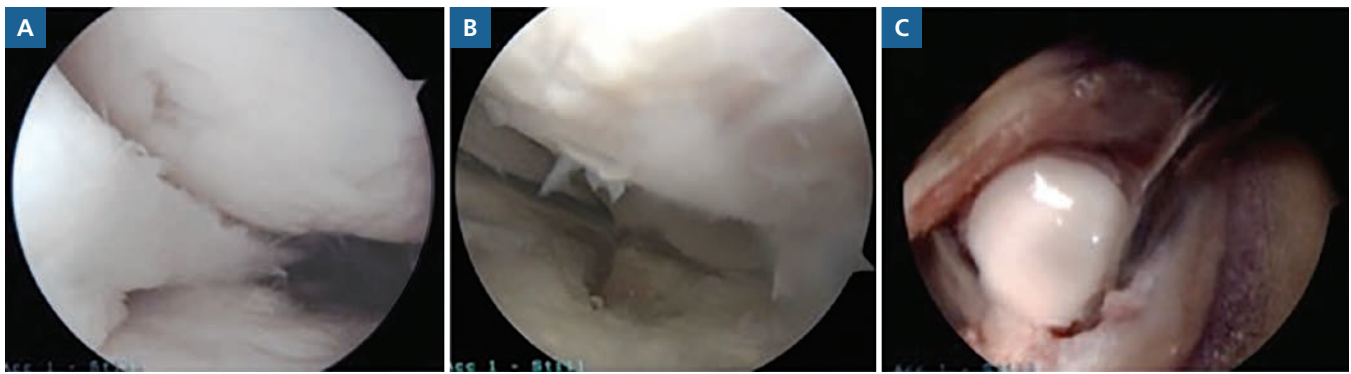


Figure 1. Arthroscopic images of the left knee demonstrating the **A**, medial femoral condyle defect with associated tibia chondromalacia; **B**, microfracture of the medial tibial plateau; and **C**, insertion of the medial femoral condyle osteochondral allograft via a medial parapatellar arthrotomy.

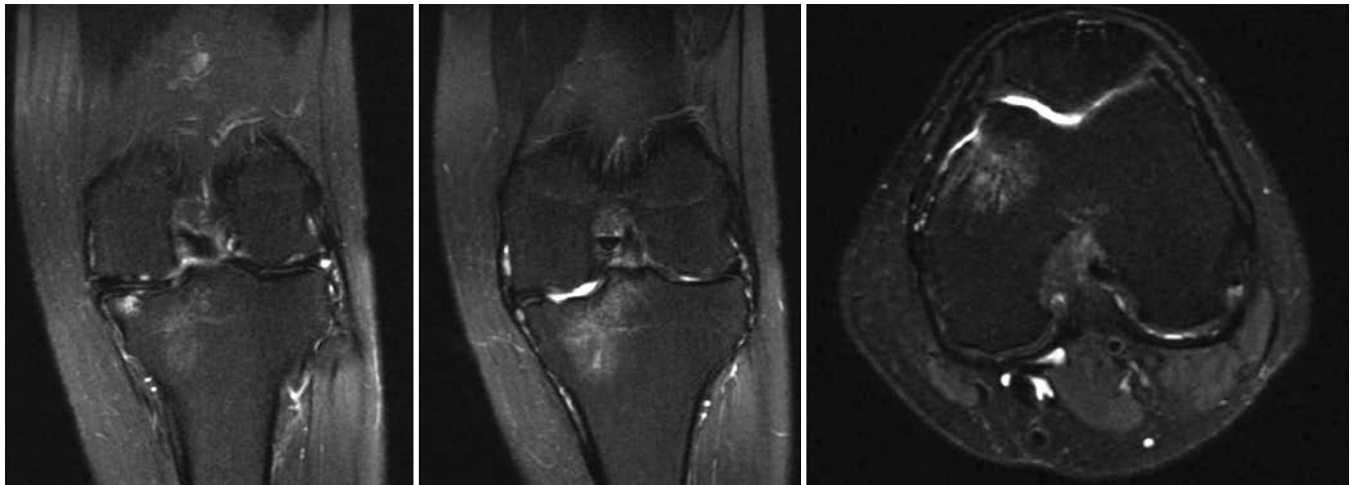


Figure 2. Noncontrast MRI of the left knee taken prior to cartilage restoration, following a series of 9 prior surgeries, demonstrating flattening of the medial femoral condyle associated with medial compartment joint space narrowing and mild medial tibial plateau osteophyte formation; also appreciated is a full-thickness posterior medial femoral condyle defect and associated bone marrow edema in the proximal medial tibial plateau and medial femoral condyle.

THE NEED FOR TRANSLATIONAL RESEARCH

This young woman represents the challenge of treating patients with cartilage deficiencies. The patients are often young, otherwise healthy, and present to the clinic with high expectations of returning to preinjury levels of activity. Additionally, they often have undergone prior treatment, including both nonoperative and operative strategies. The comprehensive management of these patients revolves around not only addressing the cartilage lesion, but also, and more importantly, addressing other concomitant factors, including meniscal pathology, malalignment, and/or ligamentous instability. This is especially important because cartilage lesions may be simply incidental, and the decision to treat is based upon confirmed contribution to the patients' symptoms. Consideration of both patient-specific (eg, age, activity level, expectations) and disease-specific factors is a prerequisite for treatment planning and

optimization of short- and long-term clinical outcomes.¹⁻⁸

For the treatment provided to this patient, several methods, materials, and results produced from our collaborative research efforts were integral to the decision making, and ultimately, the technique utilized for osteochondral allograft transplantation (Figure 4).

Biologics

Nonsurgical options for the treatment of articular cartilage defects play an important role in the overall management of these patients. Often, nonoperative alternatives, such as platelet-rich plasma (PRP) and/or hyaluronic acid (HA) supplementation are utilized as a "last resort" prior to embarking upon a more invasive surgical solution.

A recent double-blind, prospective, randomized, controlled trial conducted at our institution compared intra-articular injections of HA and PRP as noninvasive

alternatives for treating symptomatic osteoarthritis. The results suggest PRP provides superior pain relief and biochemical factors in the synovial fluid as compared to HA.⁹ A 2014 in vitro study also from our institution analyzed the effects of PRP and HA on the synovium and cartilage harvested from patients undergoing total knee arthroplasty. The authors found that while both PRP and HA resulted in decreased catabolism, PRP was biochemically superior with respect to its antinociceptive and anti-inflammatory properties.¹⁰ Recent research efforts on the nonsurgical treatment for osteoarthritis by our team focus on the use of autologous, adipose-derived regenerative cells and bone marrow concentrate as possible additional alternatives to the use of PRP and HA.

Biomechanics, Tribology, and Gait Analysis

As part of a thorough evaluation of a patient contemplated for cartilage

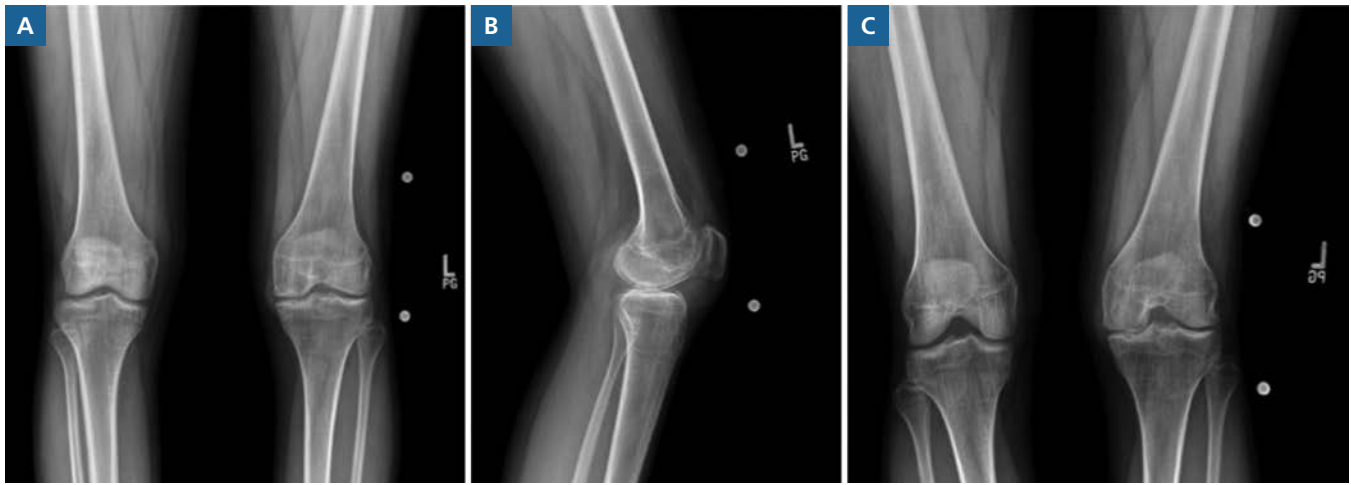
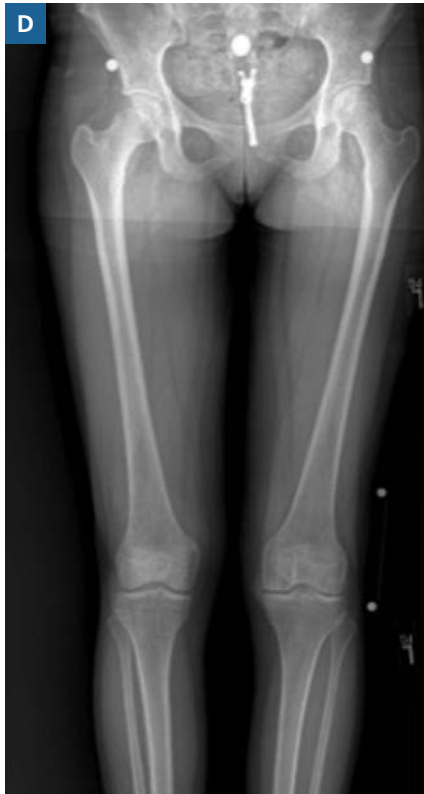

Figure 3. Pre- and post-cartilage restoration conventional radiographs of the patient's left knee. **A,** Anteroposterior view; **B,** lateral view; **C,** 45-degree oblique posteroanterior view, prerestoration; **D,** Alignment view, prerestoration, showing neutral alignment; **E, F,** One-year postoperative radiographs demonstrating excellent incorporation of the medial femoral condyle osteochondral allograft plug (**A,** anteroposterior view; **B,** lateral view).

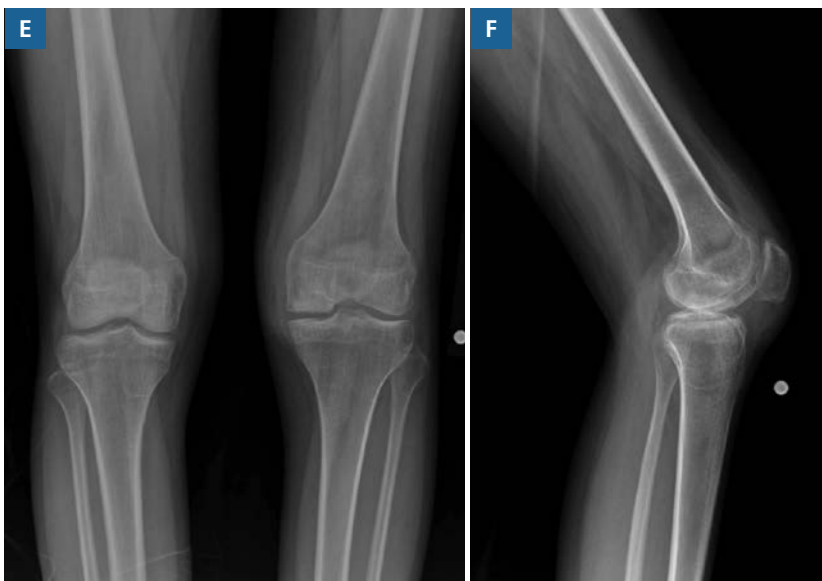


restoration, alignment is critical because it relates directly to how patients load their tibiofemoral joint and speaks to why patients complain of pain with loading activities. Specifically, biomechanical work in our laboratory suggests that, while recommendations for overcorrecting the varus knee have been espoused historically, alignment corrections to valgus beyond 3 degrees offer very little in the way of additional biomechanical unloading of the tibiofemoral joint.¹¹ This knowledge is critical: recent data suggest that overcorrection of the mechanical axis into the lateral compartment can otherwise preclude a patient from being properly indicated for a unicompartmental knee replacement, should that be required if

symptoms return. Similarly, complications related to osteotomy are not uncommon, including intra-articular fractures, which can occur at the time of surgery. Biomechanical studies in our laboratory have determined that the management of lateral tibial plateau fractures occurring intraoperatively are best managed with osteosynthesis to prevent postoperative displacement (A. Espinoza, PhD; J. Riboh, MD; K. Campbell, MD; A. Yanke, MD; B. Cole, MD, MBA; unpublished data; February 2015).

Similar work has been completed for the patellofemoral joint, substantiating the need to perform a tibial tubercle osteotomy at the time of patellofemoral articular cartilage management in order to optimize the mechanical environment and assure the most predictable outcome.¹²

Adding to the body of work on osteotomy is a sophisticated gait analysis laboratory that generates research and clinically relevant data. For example, preoperative assessment in our gait laboratory of the varus knee with a lateral-offset walking cast validated a useful tool to properly indicate a patient for tibial osteotomy.¹³ Should a patient fail to respond to nonarthroplasty treatment for cartilage damage, advances gained from the tribology laboratory, such as insight into friction, lubrication, and wear, provide important contributions to the clinical understanding of joint replacement surgery.



Allograft Preservation

Collaborating with the department of biochemistry,¹⁴ we investigated the effects of fresh osteochondral allograft preservation time on cell viability to determine optimal graft preservation methods. A prospective study¹⁵ demonstrated that “prolonged fresh” osteochondral allografts, which were historically stored for up to 42 days were histologically and biochemically inferior compared to those stored for shorter time frames of no more than 28 days. This finding affected how tissue banks across the country preserve donor cartilage and helped to optimize graft availability for patients.

Recently, collaborative work in the biochemistry lab assessed the viability of chondrocytes when exposed to chlorhexidine.¹⁶ The results from this study demonstrated that chlorhexidine concentrations of 0.002% prevented bacteria formation while remaining nonchondrotoxic, whereas higher concentrations of chlorhexidine caused chondrocyte death at unacceptable levels. Overall, this study is clinically applicable, because it offers new insight into the decontamination of osteochondral allografts without affecting chondrocyte viability.

Advances in Surgical Technique

Recent research^{17,18} has shown that the physical techniques of allograft implantation are important determinants of a successful osteochondral allograft transplantation. Research in the Rush biomechanics and tribology labs has helped to develop an impaction profile that guides the amount of force used to implant osteochondral grafts. We determined that the relevant mechanical variables for maximal cell viability include load level and impulse during insertion, and further, that radial strains should be minimized. These findings resulted in industry-wide changes of cartilage transplant methods and instrumentation. Overall, these studies help to define optimal insertion strategies of allografts at the time of surgery and have helped to define the tolerances between the graft and host bed at the time of surgery to minimize the amount of impaction forces

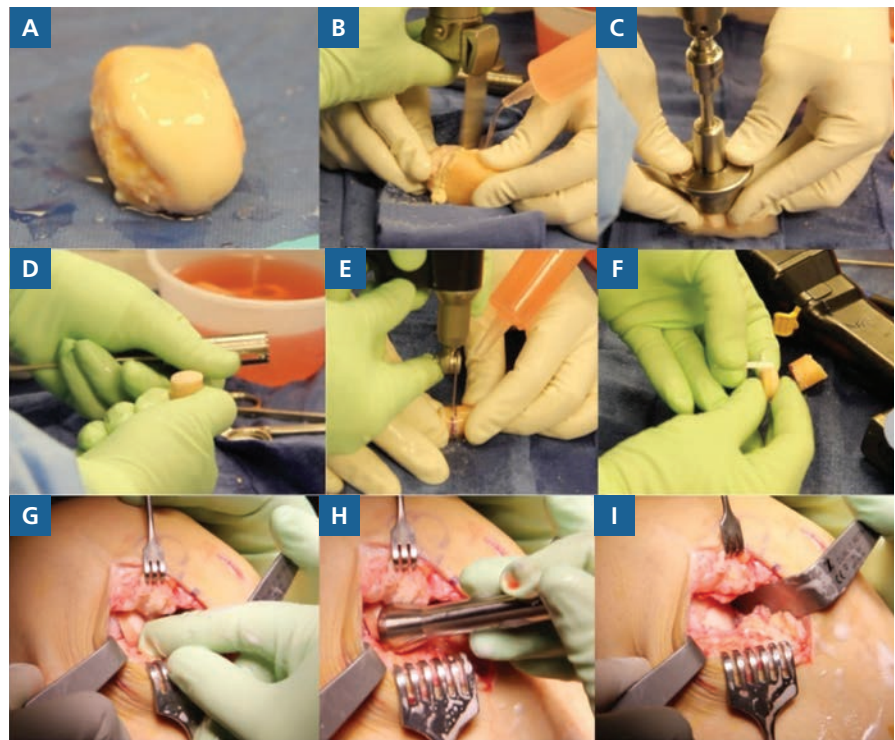


Figure 4. Intraoperative photographs demonstrating **A**, fresh osteochondral allograft femoral condyle; **B**, preparation of allograft on back table; **C**, sizing of allograft to match host defect size; **D**, osteochondral “plug” created using customized instrumentation; **E**, adjusting depth of allograft to match depth of already-measured defect; **F**, confirming measurements of allograft depth; **G**, placement of “plug” into defect on femoral condyle; **H**, impaction of allograft into defect bed; **I**, final appearance of osteochondral allograft placed flush into defect bed.

at surgery. Current efforts at Rush include studies that topographically define alternative graft sources in an effort to reduce the existing donor supply constraints.

Microfracture Adjuncts

Over the past decade, an increased number of publications have discussed reparative strategies to restore cartilage, including augmented microfracture¹⁹ and matrix-associated autologous chondrocyte implantation techniques. Recent *in vivo* work, including an investigation of micronized allograft collagen as a scaffold hydrated with PRP (BioCartilage; Arthrex, Inc., Naples, Florida) in an equine model for cartilage defects²⁰ and an *in vivo* study of the effects of a collagen membrane to enhance marrow stimulation procedures in the glenohumeral joint,²¹ suggest that the outcomes of traditional microfracture surgery can be improved.

Research and Statistical Analysis of Clinical Outcomes

On the clinical side, utilizing the power of the Rush Cartilage Restoration Center Registry, we reported on the outcomes of

patients undergoing osteochondral allograft transplantation.¹⁵ In this 2007 prospective study, researchers followed 25 consecutive patients undergoing osteochondral transplantation for an average of 35 months after surgery. On average, patients had significantly increased Lysholm, IKDC, KOOS, and Short-Form 12 (SF-12) outcomes scores compared to preoperative levels; further, these patients reported an 84% satisfaction rate and a 79% knee function rate, compared to the contralateral knee. Overall, these early results provide support for osteochondral allograft transplantation, especially in young patients who otherwise may have no other realistic surgical option, such as the girl described earlier.

A 2012 systematic review of the literature,²² in which Chahal and colleagues from Rush analyzed 19 studies with 644 knees at an average 58 months of follow-up, provided support for this clinical work. The authors reported an overall satisfaction rate of 86%, with a short-term complication rate of 2.4% and an overall failure rate of 18%. Importantly,



Figure 5. Rush Cartilage Restoration Center team. Back row, left to right: Markus A. Wimmer, PhD; Adam Yanke, MD. Front row, left to right: Kavita Ahuja, MBBS; Vincent M. Wang, PhD; Brian J. Cole, MD, MBA, director, Rush Cartilage Restoration Center; Elizabeth Shewman, PhD; Susan Chubinskaya, PhD. Not shown: Nikhil N. Verma, MD. Photo courtesy of John Booz.

the authors reported that 46% of patients underwent concomitant procedures, which is consistent with the patient population in our clinical practice.

Concomitant Management of Comorbidities

Preoperative considerations in the patient discussed previously included the evaluation of her articular cartilage, meniscus, ligaments, and overall alignment. If any such comorbidities had been present, the cartilage restoration procedure performed in isolation would have been predisposed to early failure. Several clinical outcome studies have demonstrated favorable clinical outcomes following combined procedures: a study on patients undergoing meniscal allograft transplantation (MAT) with fresh osteochondral allograft transplantation;²³ and a second study on patients undergoing MAT with cartilage restoration (with osteochondral allograft transplantation, microfracture, or autologous chondrocyte implantation [ACI]), and realignment (distal femoral osteotomy or high tibial osteotomy).²⁴ Together, these patients provide us with data for counseling patients on their expected outcomes in these difficult clinical situations.


Preoperatively, the status of the medial meniscus in our patient was in question. In spite of her clinical presentation, MRI findings, and multiple previous surgeries, we were uncertain of the integrity of the meniscus prior to our diagnostic arthroscopy. Given the role the meniscus plays within each compartment, its status is crucial when considering cartilage restoration. As shown via studies conducted in collaboration with the department of biomechanics,^{25,26} segmental meniscectomy is biomechanically akin to a total meniscectomy with respect to tibiofemoral load bearing.

Thus, prior to surgery, we discussed with the patient the possibility of performing MAT. In perhaps the largest series to date, investigators at Rush found that of 172 patients undergoing MAT (with or without concomitant procedures), overall allograft survival was 95% at an average of 5 years following transplantation.²⁷ In this cohort, which included some high-level athletes, the reoperation rate was relatively high, with 64 patients (32%) returning to the operating room, the majority for arthroscopic debridement. Of those patients requiring subsequent surgery, the overall allograft survival rate at 5 years was still relatively high, at 88%. In a separate

MAT outcomes study analyzing 22 patients at an average of 8.5 years following MAT, our team found reduced pain, increased range of motion, and improved function/satisfaction, with an overall success rate of 88%.²⁸ Most compelling is a recent publication on high-level athletes undergoing MAT with a predictable and sustained ability to return to sport, challenging the historical argument that these procedures can only be performed successfully in lower-demand patients.²⁹

CONCLUSIONS

Patients who require cartilage restoration procedures are perhaps among the most challenging to treat. Too young for arthroplasty but often too symptomatic and high demand to simply manage, young patients with articular cartilage deficiencies are very much in need of joint preservation strategies to successfully address their condition.

A comprehensive approach to caring for the patient with cartilage deficiency is critical because adequate treatment relies not only on appropriate surgical technique but also on basic, translational, and clinical research studies occurring behind the scenes. These research strategies have guided our clinical decision making for almost 2 decades, and the multidisciplinary, collaborative approach used by the Cartilage Restoration Center at Rush team (Figure 5) enables us to contribute to the body of cartilage deficiency literature while learning from the contributions of others around the world. 

References and financial disclosures are available online at www.rush.edu/orthopedicsjournal.

“A rare and potentially complicated cause of back pain is aneurysmal bone cyst (ABC), a benign neoplasm characterized by blood-filled cavities with varying degrees of tissue destruction.”

Aneurysmal Bone Cyst of the Thoracic Spine

A Case Report and Review of Literature

ANDREW SEXTON, BS / PHILIP K. LOUIE, MD / EHSAN TABARAEI, MD / DAVID FARDON, MD / MATTHEW W. COLMAN, MD

AUTHOR AFFILIATIONS

Department of Orthopedic Surgery, Rush University Medical Center (Mr Sexton and Drs Louie, Tabaraee, Fardon, and Colman) and Midwest Orthopaedics at Rush (Drs Fardon and Colman), Chicago, Illinois.

CORRESPONDING AUTHOR

Ehsan Tabaraee, MD, Department of Orthopedic Surgery, Rush University Medical Center, 1611 W Harrison St, Suite 300, Chicago, IL 60612 (ehsan_tabaraee@rush.edu).

INTRODUCTION

Back pain is ubiquitous, debilitating, and costly to society. Though the source of back pain is often due to common mechanical and degenerative disorders, there are numerous less-common sources. A rare and potentially complicated cause of back pain is aneurysmal bone cyst (ABC), a benign neoplasm characterized by blood-filled cavities with varying degrees of tissue destruction.^{1,2} Although ABCs are benign, they can be difficult to distinguish from malignant disease. Even with early and proper identification, an ABC can weaken the structural integrity of the spine and/or compress the spinal cord and nerve roots. Treatment options vary in their level of invasiveness but share the ultimate goals of decreasing pain, reducing recurrence, and maintaining spinal stability.

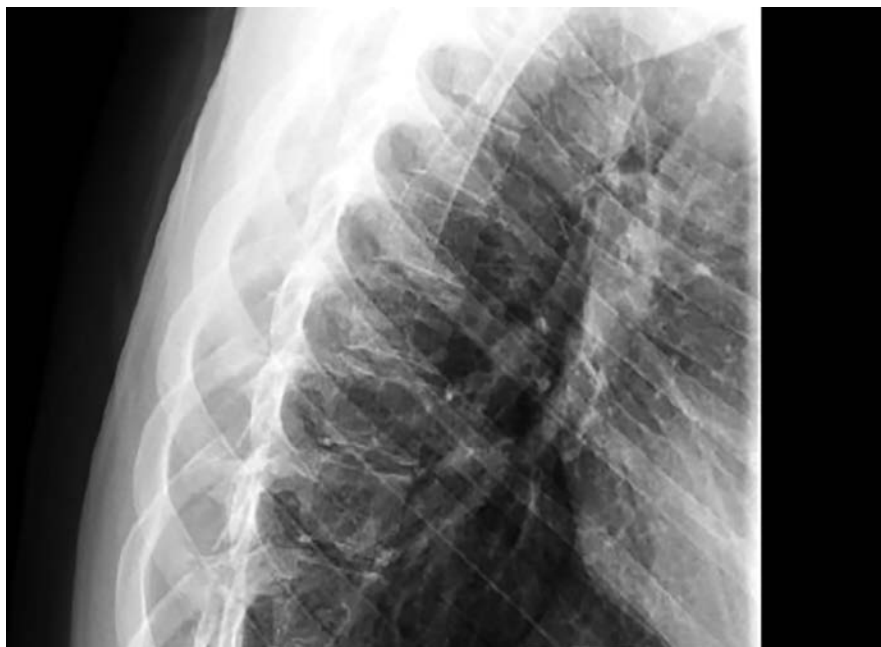

Figure 1. Preoperative lateral thoracic radiograph. The overlying bony anatomy and viscera obscure the lesion.

PATIENT PRESENTATION

A 19-year-old female presented to the emergency department at Rush University Medical Center with severe back pain. She had experienced progressive back pain for 2 months with no history of antecedent trauma. The pain had been intolerable for 3 weeks. Her physical exam was notable due to her paraspinal tenderness as well as inability to ambulate due to pain. We observed no sensory or motor deficits. Radiographs (anteroposterior [AP] and

lateral of the thoracic and lumbar spine) did not demonstrate obvious pathology such as a fracture, deformity, or bony destruction (Figure 1). Because of the severity and duration of her pain, we obtained magnetic resonance imaging (MRI) and computer tomography (CT) scans (Figures 2 and 3). The most profound findings were bone and soft tissue abnormalities involving the bilateral pedicles, pars, lamina, and spinous process of the T11 vertebra. This appearance

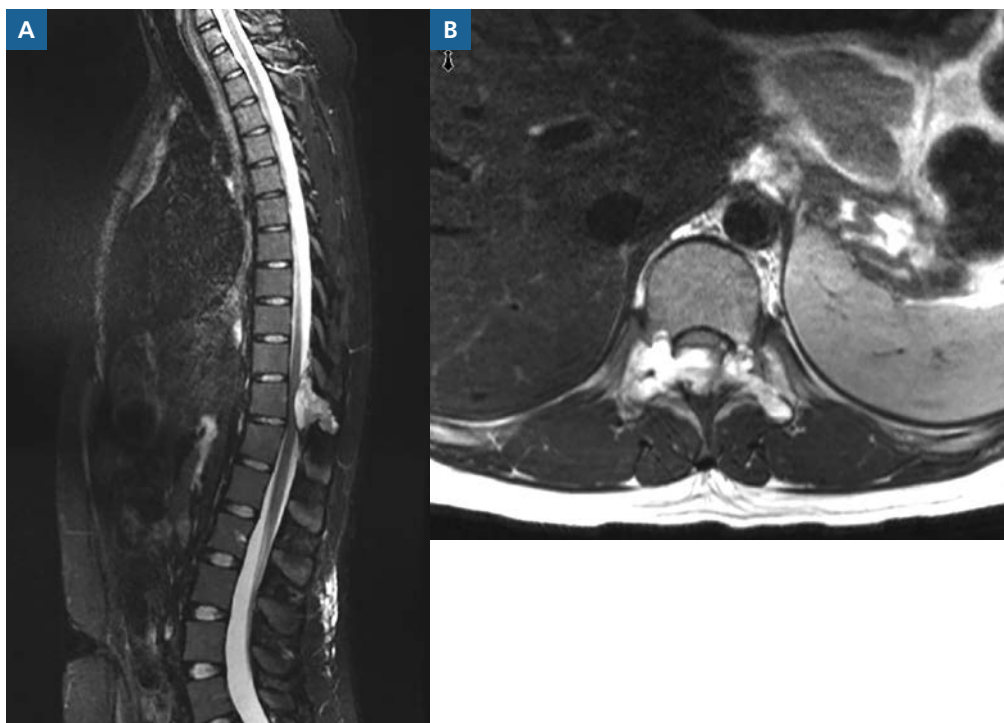


Figure 2. Preoperative **A**, sagittal and **B**, axial MRI. A multilobulated cyst enhances the lesion that involves spinous process, lamina, pedicles and posterior aspect of the vertebral body of T11. There is a narrow zone of transition without marrow edema. Multiple fluid-fluid levels are present within this multicystic lesion. There is compression of the cord by high grade stenosis but no abnormal signals within the cord. The remainder of the thoracic spine and surrounding soft tissues are normal and show no infiltration.

can also be seen with telangiectatic osteosarcoma, a more malignant neoplasm; therefore, we performed a CT-guided needle biopsy. We found blood-filled cavities with thin-walled fibrotic trabeculae layered with giant cells without atypical cellular hypertrophy, a pattern consistent with ABC.

After informed consent, we performed T10-T12 posterior thoracic laminectomies, transpedicular en bloc resection of the T11 tumor and posterior instrumented spinal fusion from T9-L1 with an anterior fibular allograft. There was minimal infiltration of the paraspinal soft tissue. The cortex of the T11 lamina was intact. During the drilling of the lateral part of both pedicles at T11, we encountered a tumor, which we sent for frozen section. Preliminary observations by the pathologist confirmed the suspected diagnosis of ABC. Once the transection of the pedicle was complete, the tumor mass was free.

The lesion was friable and separated into 2 pieces upon removal (Figure 4). Analysis of the pathologic specimen revealed mononuclear cells and multinucleated osteoclast-like giant cells with admixed hemorrhage that formed cystic spaces, many filled with blood (Figure 5). These morphologic features are consistent with an ABC.

During the 4-hour operation, the patient received 4,000 ml of crystalloid intravenous (IV) fluid and had an estimated blood loss of 600 mL. Sensory and motor function throughout her trunk and lower extremities remained intact postoperatively. She stayed in the surgical intensive care unit (ICU) for one night and received 1 unit of packed red blood cells. She was able to ambulate without pain in 1 week and was discharged from the hospital on postoperative day 8, after achieving physical therapy goals.

At 6 weeks from the index procedure, she was pain free without any limitations. New AP and lateral standing thoracolumbar scoliosis radiographs revealed that the instrumentation was intact (Figure 6). Her spinal balance was within normal limits in all planes.

DISCUSSION

ABCs of the spine are rare, accounting for 1.4 patients per 3 million.^{1,3} The etiology of this benign condition is unknown. ABCs are most commonly located in the metaphysis of long bones; however, 10% to 30% of all cases are located in the spine.^{1,2,4,5} Females are typically affected more than males by the condition, which commonly occurs in the second decade of life. A large, population-based study found up to 66% of ABCs occurred in

patients younger than 20 years of age and were likely related to skeletal growth and immaturity.⁶ Spinal ABCs have a predilection to the thoracolumbar spine, where they present as ballooning of the posterior elements of the spine with a thin, well-defined rim in the periphery.² However a fluid-filled lesion is not specific to an ABC, thus requiring a biopsy for a definitive diagnosis.

Clinically patients will often present with a gradual onset of back pain due to paravertebral invasion of the lesion. A spinal deformity or palpable mass may be present.^{5,7} When spinal cord compression is present, motor and sensory deficits become apparent. The lesions are characterized by highly vascularized blood-filled cavities with varying degrees of aggressiveness in local tissues, predominantly seen in the posterior elements.^{1,2} Radiographs, MRI, and CT are used to make a diagnosis in conjunction with a biopsy. ABCs appear as a blown out “soap bubble” appearance on radiographs.⁷ MRI allows for evaluation of neural impingement and may show locular lesions and fluid-fluid levels on T2-weighted images. A septate pattern that represents multilocular lytic lesions with cortical erosion and expansion can be visualized on CT. Additionally, angiography can identify arteriovenous shunts by determining blood supply to the lesion.^{5,8}

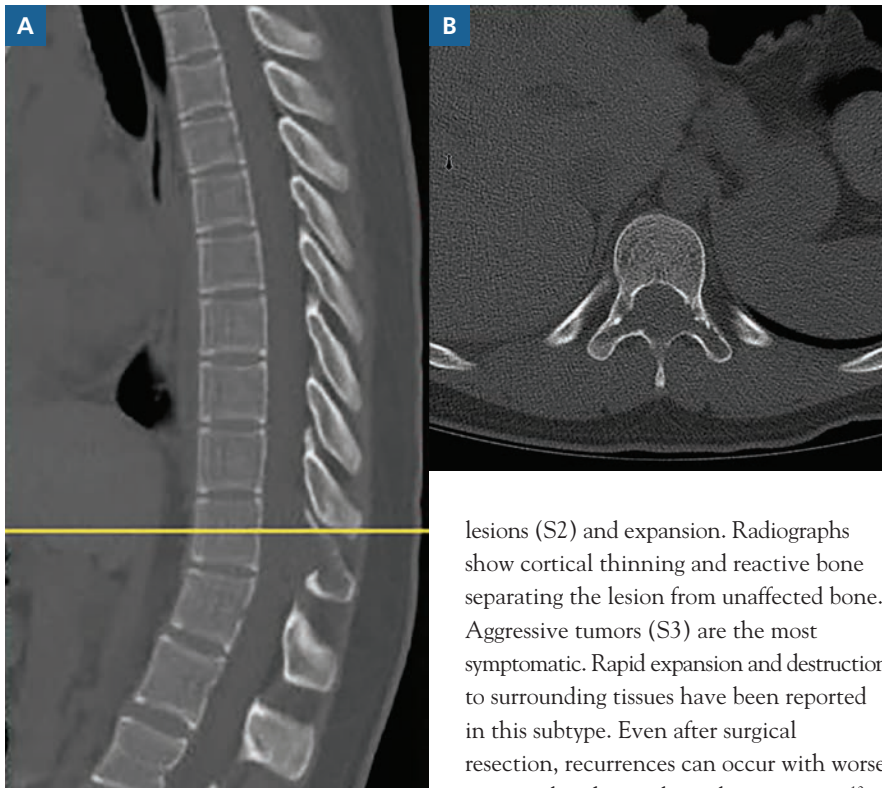


Figure 3. Preoperative **A**, sagittal and **B**, axial CT views. A lytic mass involving the posterior elements of the T11 vertebrae is visible, with erosion of the normal trabeculae resulting in communication with the spinal canal.

Although ABCs of the spine are generally considered benign, they can become locally aggressive, as described by Enneking,⁹ who classified the severity of the invasiveness of cysts relative to 3 stages: inactive, active, and aggressive. An inactive tumor (S1) is fully contained, latent, static, and “self-healing,” and is thus the most benign. There is minimal periosteal reaction or inflammation because expansion is rare. Mild pain symptoms are generally reported in active

lesions (S2) and expansion. Radiographs show cortical thinning and reactive bone separating the lesion from unaffected bone. Aggressive tumors (S3) are the most symptomatic. Rapid expansion and destruction to surrounding tissues have been reported in this subtype. Even after surgical resection, recurrences can occur with worse structural and neurological impairment.¹⁰

Nonsurgical management of clinically significant spinal ABCs has a limited role because early surgical intervention provides satisfactory results.⁵ A variety of interventions has been described including angiography for embolization, radiation, intralesional curettage with or without allografts or polymethyl methacrylate supplementation, and en bloc tumor excision.^{1,2,3,11}

Selective arterial embolization (SAE) is becoming more frequently used in the treatment of ABCs. Given the vascular nature of ABCs, this strategy was previously used simply to reduce intraoperative bleeding. However, SAE

has gained momentum in serving as a modality to heal an ABC without the morbidity of open procedures. As a stand-alone treatment, its goal is to initiate tumor necrosis by stopping blood supply. Additionally, SAE can be used before open resection to help minimize blood loss.^{4,5,6,10,12,13,14} Although a less-invasive procedure, a single SAE treatment may not produce the desired results, requiring repeated attempts. Amendola et al performed SAE on 7 patients with a primary ABC in the mobile spine.¹² The number of embolizations required ranged from a single treatment to 7 procedures to accomplish complete necrosis of the ABC. At mean follow up of 46 months, all patients were free of disease, requiring no additional surgical intervention. Similarly, Boriani et al emphasized the need for multiple embolization treatments due to unsatisfactory results after initial embolization and the overall increased radiation exposure from repeat procedures.³ This group also observed the development of collateral circulation at the tumor site following SAE administration. Additional concerns have been expressed with SAE performed in the thoracic and upper lumbar spine, because accidental embolization of the artery of Adamkiewicz could lead to cord ischemia and anterior cord syndrome.⁴

Adjunct radiation therapy has also been shown to alleviate pain and reduce cyst size but has not become routine practice, given the risks of developing radiation-induced sarcoma, myelopathy, or spinal deformity.¹⁵

An intralesional excision often involves piecemeal removal of the tumor (curettage). The use of structural allograft or polymethyl methacrylate has been shown to be effective in S1 and S2 tumors with a low rate of recurrence. However, if applied to more aggressive tumors (S3), recurrence rates have been reported upwards of 30%, with most occurring within 2 years of the excision.^{5,10,16,17}

En bloc resection is an attempted complete marginal removal of the tumor and has been associated with the lowest rate of recurrence after initial treatment.^{4,6,10,14} Campanacci et al reviewed 47 cases of

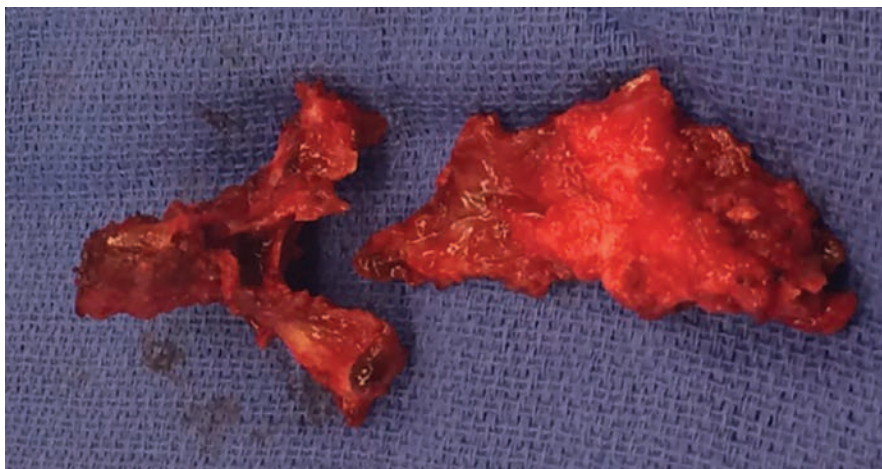


Figure 4. This image reveals the friable lesion involving the posterior elements (left) as well as a portion of the T11 vertebra (right).

ABC in multiple locations (including the spine) where complete en bloc resection was performed. No patients were found to present with an ABC recurrence. Similarly, no spinal ABC patients followed by Boriani et al who underwent an en bloc resection presented with recurrence of an ABC lesion.¹⁰ Nine patients with ABC in the spine were followed for a minimum of 2 years by Mesfin et al.¹⁴ Two patients had tumor recurrence and required extensive anterior and posterior spinal fusion; no additional recurrences have been observed. Harrop et al reviewed several studies specific to spinal ABCs and strongly recommended complete en bloc resection of ABCs that occur in the spine.¹⁸

Complications with en bloc resections are most commonly related to blood loss requiring transfusions.^{5,11} Additionally, en bloc tumor excision without stabilization may lead to spinal instability; therefore, instrumented fusion is often a concomitant procedure.

These procedures are complicated and require a large amount of preoperative planning to successfully remove the tumor with free margins.¹⁹ Despite the morbidity associated with the significant surgical dissection, en bloc resection results in a low tumor recurrence rate while providing a stable, balanced spine.

CONCLUSIONS

Despite their benign nature, ABC lesions can threaten the bony architecture and vital neural structures of the spinal column. Correct treatment depends upon the aggressiveness, size, and location of the lesion. In the case presented here, an ABC caused pain and instability of the spine and cord compression in an otherwise healthy 19-year-old woman. En bloc resection of the T11 vertebra with decompression and fusion of the thoracolumbar spine has successfully relieved her pain, restored stability, and minimized the chance of local recurrence. ○

References and financial disclosures are available online at www.rush.edu/orthopedicsjournal.

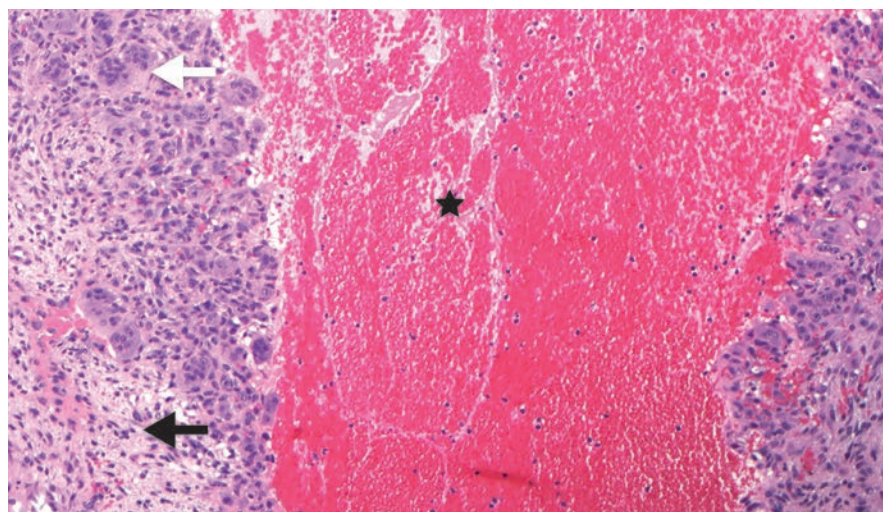


Figure 5. Intermediate power view of an ABC showing clusters of giant cells (white arrow) in a background of spindle cell proliferation within the septa (black arrow). Vascular proliferation may also be seen (star).

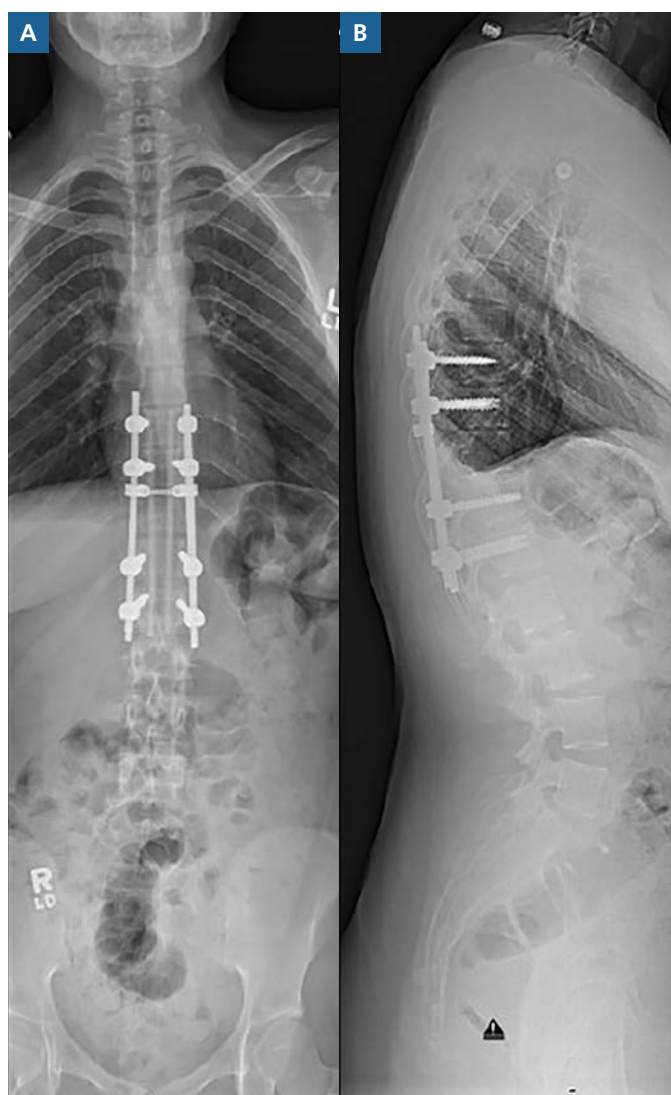


Figure 6. Postoperative **A**, anterior-posterior and **B**, lateral scoliosis radiographs. Status-post T10-T12 decompression, resection of T11 tumor, and posterior spinal instrumentation from T9 to L1. This instrumentation consists of bilateral pedicle screws at T9, T10, T12, and L1 stabilized by vertical connecting rods and a horizontal crosslink.

“Overall, surgery for displaced greater tuberosity fractures is highly successful, with very low complication rates and high patient satisfaction.”

Management of Isolated Greater Tuberosity Fractures

A Systematic Review

DAVID M. LEVY, MD / BRANDON J. ERICKSON, MD / JOSHUA D. HARRIS, MD
BERNARD R. BACH JR, MD / NIKHIL N. VERMA, MD / ANTHONY A. ROMEO, MD

AUTHOR AFFILIATIONS

Department of Orthopedic Surgery, Rush University Medical Center (Drs Levy, Erickson, Bach, Verma, and Romeo) and Midwest Orthopaedics at Rush (Drs Bach, Verma, and Romeo), Chicago, Illinois; Department of Orthopedics and Sports Medicine (Dr Harris), Houston Methodist Hospital, Houston, Texas.

CORRESPONDING AUTHOR

David M. Levy, MD, Department of Orthopedic Surgery, Rush University Medical Center, 1611 W Harrison St, Suite 300, Chicago, IL 60612 (david_levy@rush.edu).

INTRODUCTION

Isolated fractures of the greater tuberosity occur less frequently than other types of proximal humerus fractures. Fracture patterns and displacement determine treatment.^{28,29} Nondisplaced fractures are often managed nonoperatively.^{9,22} Operative intervention may prevent loss of motion from subacromial impingement. Superior displacement decreases abduction and posterior displacement limits external rotation. Posterosuperior displacement has produced the worst outcomes (Figure 1).²⁹ The debated displacement requiring operative care has ranged from 3 to 10 mm. Less displacement is tolerated in young, overhead athletes, and more displacement

may be accepted in older, less-active patients.^{18,24,26} Ideal surgical method is unclear,²⁸ with possibilities including fragment excision, open reduction internal fixation (ORIF), closed reduction with percutaneous fixation, and arthroscopic-assisted reduction with internal fixation.^{5,9,20}

We sought to determine the treatment patterns for management of isolated fractures of the greater tuberosity. We hypothesize that minimally displaced greater tuberosity fractures may be treated nonoperatively while those with significant displacement require surgical fixation.

METHODS

Search Strategy

We conducted a systematic review of the available literature according to Preferred Reporting Items for Systematic Reviews and Meta-Analyses (PRISMA) checklist.¹⁹ Systematic review registration was performed with the PROSPERO International prospective register of systematic reviews (registration number CRD42014010691). Searches were completed in August 2014 using the MEDLINE/PubMed databases and the Cochrane Central Register of Clinical Trials. We designed the keyword selection to capture all Level I-IV evidence (according to the Oxford Centre for

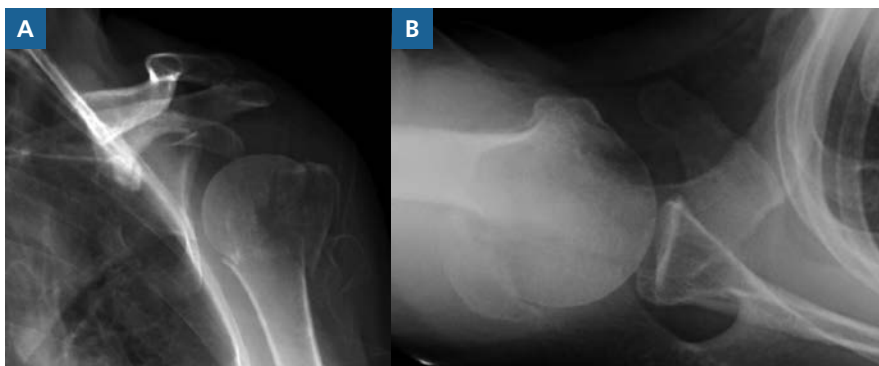


Figure 1. A, Anteroposterior (AP) and B, axillary radiographs of a 66-year-old woman with a greater tuberosity fracture and concomitant surgical neck fracture. Due to extensive medical comorbidities, she has been managed nonoperatively. As a result of the posterosuperior displacement of her greater tuberosity fracture, this patient has had limitations in shoulder abduction and external rotation.

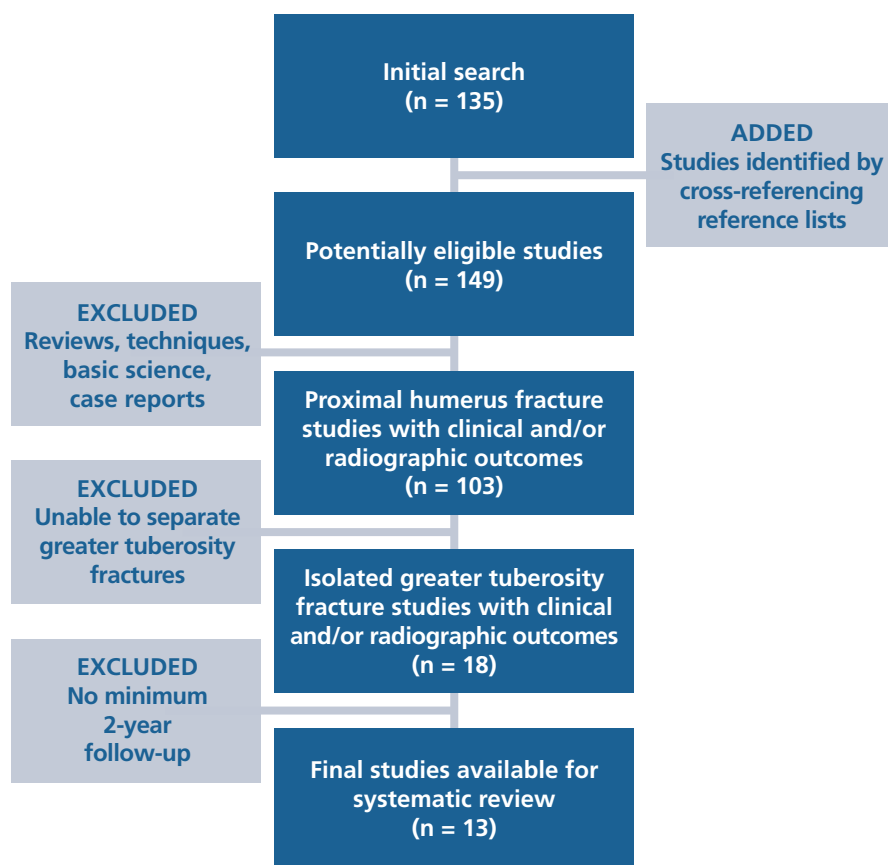


Figure 2. Flowchart demonstrating search strategy based on Preferred Reporting Items for Systematic Reviews and Meta-Analyses (PRISMA).

Evidence-Based Medicine), English-language studies that reported clinical and/or radiographic outcomes. This was accomplished using an electronic search algorithm with keywords and a series of “NOT” phrases designed to match our exclusion criteria. Initial study exclusion criteria consisted of cadaveric, biomechanical, histological, and kinematic results.

Study Selection

The search yielded 135 initial results, which were then reviewed for further differentiation. All references within these initial studies were cross-referenced for inclusion if missed by the initial search; this process added 15 additional studies. We excluded technical notes, letters to the editor, and Level V evidence reviews. To ensure that no patients were counted twice, we reviewed and compared each study’s authors, data collection period, and ethnic population to those of the other studies. If there was any overlap in authorship, period, and place, only the study with longer follow-up, more patients, or more comprehensive data was included. If a study separated outcomes by diagnosis, only

outcomes for patients with isolated greater tuberosity fractures were included. Data on 3- or 4-part proximal humerus fractures and isolated lesser tuberosity fractures were excluded. We also excluded studies that could not be deconstructed as such or that were entirely devoted to 1 of our exclusion criteria. Minimum follow-up duration was 2 years. After accounting for all inclusion and exclusion criteria, 13 studies with 429 patients (429 shoulders) were selected for inclusion (Figure 2).^{1,2,6-8,15,17,23,25-27,29}

Data Extraction

From the 13 studies that satisfied eligibility criteria, we recorded study design, sample size, and demographics. We also tabulated mechanism of injury and presence of concomitant anterior shoulder instability. In order to capture the largest number of patients, radiographic fracture displacement was reported categorically (vs continuously). We divided patients into 1 of 2 groups: less than or greater than 5 mm of displacement. We studied both nonoperative and operative management and abstracted surgical factors such as the approach, method, fixation type (screws or sutures),

and technique (suture anchors or transosseous tunnels). Clinical outcomes included physical exam, functional assessment (percent patient satisfaction, Constant, University of California, Los Angeles [UCLA] scores), and the number of revisions. Radiographic outcomes focused on loss of reduction (as determined by the respective authors), malunion, nonunion, and heterotopic ossification. For nonoperative patients, we defined “loss of reduction” as increased fracture displacement. Each study’s methodological quality and bias were evaluated using the modified Coleman methodology score (MCMS) described by Cowan et al.⁴ The MCMS is a 15-item instrument that has been used to assess both randomized and nonrandomized patient trials.^{11,12} It has a scaled potential score ranging from 0-100, with scores from 85-100 being excellent; 70-84, good; 55-69, fair; and less than 55, poor.

Statistical Analysis

We reported our data as weighted means with standard deviation. A mean was calculated for each study that reported a respective data point, and each mean was then weighed according to its study sample size. This calculation was performed by multiplying a study’s individual mean by the number of patients enrolled in that study and dividing the sum of these weighted data points by the number of eligible patients in all relevant studies. In this way, the nonweighted means from studies with a smaller sample size did not carry as much weight as those from larger studies. Comparisons were made between 3 paired groups: nonoperative vs operative, fracture displacement less than 5 mm vs that greater than 5 mm, and open vs arthroscopic surgery. We compared all subject, surgical, and outcomes data using chi-squared tests and 2-sample and 2-proportion z test calculators with equal variance and an alpha value of .05 (SPSS v.18; IBM Inc., Armonk, NY).

RESULTS

Demographic information and treatment strategies are listed in Table 1. Concomitant shoulder instability was reported in 28.1% of patients. The mechanism of injury

Table 1. Demographics for the Final Cohort of Included Patients

Parameter	Value
Gender ^{1,2,7,8,14,16,23,25-27,29}	
Males, No. (%)	235 (58.0)
Age (years) ^{1,2,7,8,14,16,23,25-27,29}	50.7 ± 9.2
Shoulder dominance ^{7,16,25,26,29}	
Dominant, No. (%)	154 (59.0)
Fracture displacement ^{1,2,7,8,14-16,23,25,26,29}	
Number with displacement under 5 mm, No. (%)	242 (59.2)
Treatment	
Nonoperative management, No. (%) ^{15,25-27}	217 (50.6)
Surgical management, No. (%)	212 (49.4)
Open reduction internal fixation, No. (%) ^{1,7,8,26,29}	132 (30.9)
Arthroscopic fixation, No. (%) ^{14,16,23,29}	56 (13.1)
Percutaneous fixation, No. (%) ^{2,26}	24 (5.6)

was not reported in all studies but most commonly was a fall on an outstretched hand (n = 75); 31 patients suffered sports-related injuries, and 37 patients hurt their shoulders in motor-vehicle collisions. Of 429 patients, 50.1% were treated surgically.

Postoperative physical exam findings were underreported for the sake of comparisons between treatment groups. Four studies reported postoperative forward elevation (160° ± 9.8°) and external rotation (46.4° ± 26.3°).^{1,8,14,23} No malunions and only 1 nonunion were reported in all 13 studies. Eight operative patients required reoperation. Twelve cases of stiffness were reported, all in the surgical group, and 3 required revision surgery. One patient required revision ORIF. There were 2 cases of superficial infection and 4 neurologic injuries after surgery. No deaths or other serious medical complications were documented.

For comparisons between nonoperative and operative, minimally displaced and displaced, and open/percutaneous and arthroscopic groups, see Tables 2, 3, and 4, respectively. Patients with anterior instability were more common in the operative group (vs nonoperative) (39.2% vs 12.0%, *P* < .01); and in the displaced (vs displacement under 5 mm) (44.3% vs 14.5%, *P* < .01) group.

Operative patients had significantly fewer cases of radiographic loss of reduction (5.2% vs 48.6%, *P* < .01) and better patient satisfaction (90.4% ± 13.0% vs 46.1% ± 47.1%, *P* < .01) than the nonoperative group. The operative group had a significantly increased rate of shoulder stiffness (5.7% vs 0.0%, *P* = .03). Compared to fractures with greater than 5 mm of displacement, those with less than 5 mm of displacement had more cases of radiographic loss of reduction (42.7% vs 10.3%, *P* < .01) and fewer instances of heterotopic ossification (0.0% vs 7.5%, *P* < .01). Less than 1% of minimally displaced fractures required eventual surgery compared to a 3.7% reoperation rate in the displaced fracture group. There were no statistically significant differences between arthroscopic and open techniques in terms of stiffness, neurologic injury, or reoperation rates.

The mean MCMS for the 13 studies was 41.1 ± 8.6. All studies, with the exception of 1,²⁶ consisted of Level IV evidence.

DISCUSSION

Five percent of all fractures involve the proximal humerus, of which 20% are isolated greater tuberosity fractures.^{3,10} Neer formulated the 4-part proximal humerus fracture classification and defined

greater tuberosity fracture “parts” using the same criteria as for other fracture “parts.”²¹ He recommended nonoperative management for isolated greater tuberosity fractures with less than 1-cm displacement. And more recent cutoffs for nonoperative treatment include 5 mm in the general population and 3 mm for athletes.^{24,25}

Only 4 studies presented outcomes data on nonoperative treatment of greater tuberosity fractures.^{15,25-27} Two studies assessed nonoperative treatment for displacement less than 5 mm, both with successful outcomes.^{25,27} Platzer et al showed good or excellent results in 97% of 135 shoulders after 4 years.²⁵ The authors did, however, show slightly worse results with superior displacement from 3-5 mm and recommended surgery for overhead athletes in this group. Rath et al described a successful 3-phase rehabilitation protocol of sling immobilization for 3 weeks, pendulum exercises for 3 weeks, and active exercises thereafter. At an average of 31 months, their patient satisfaction scores improved from 4.2 of 10 to 9.5, although the authors cautioned that the average duration of pain and decreased motion was 8 months.²⁷ Conservative treatment was far less successful in the 2 studies of displacement greater than 5 mm.^{15,26} Keene et al reported unsatisfactory results in all 4 patients with over 1.5 cm of displacement.¹⁵ In a separate study from their prior analysis of nondisplaced fractures, Platzer et al evaluated displaced fractures and showed inferior function and patient satisfaction with nonoperative treatment versus surgery.²⁶ These latter 2 studies contribute to the overall lower patient satisfaction rate in the nonoperative group.

Only 2 arthroscopic studies and no open studies looked at surgery for fractures with less than 5 mm of displacement. When treated nonoperatively, less than 1% of these minimally displaced fractures eventually require surgery. By contrast, fractures with over 5 mm of displacement are almost always treated with surgery, and 3.7% require reoperation. Radiographic loss of reduction was more common in the minimally displaced fracture group, primarily because these fractures are

Table 2. Comparison of Outcomes Between Nonoperative and Operative Groups

Parameter	Nonoperative (n = 217)	Operative (n = 212)	P Value
Age (years)	52.2 ± 8.1	44.7 ± 9.1	.12
Number with radiographic follow-up	144	172	
Final radiographic follow-up (months)	46.1 ± 15.2	50.9 ± 17.0	.39
Loss of fracture reduction, No. (%)	70 (48.6)	9 (5.2)	< .01 ^a
Heterotopic ossification, No. (%)	5 (3.5)	8 (4.7)	.60
Number with clinical follow-up	217	212	
Final clinical follow-up (months)	41.5 ± 15.3	49.5 ± 16.6	.09
Constant score	85.7 ± 11.7	87.1 ± 4.2	.67
University of California, Los Angeles score	30.8 ± 4.2	31.1 ± 1.2	.95
Patient satisfaction (%)	46.1 ± 47.1	90.4 ± 13.0	< .01 ^a
Stiffness (%)	0.0	5.7	.03 ^a
Superficial infections (%)	0.0	0.9	.17
Reoperations (%) ^b	0.0	3.8	< .01 ^a
Reoperations for stiffness (%) ^b	0.0	1.4	.08
Revision fixation (%) ^b	0.0	0.5	.31

^aStatistically significant.

^bFor nonoperative management, *reoperations* refers to eventual surgeries during the follow-up period.

managed without fixation. Radiographic loss of reduction was documented in just 9 patients treated operatively, none of whom were symptomatic enough to require a second surgery.²⁶ Reoperations were most commonly performed for stiffness. Bhatia et al reported the highest reoperation rate (3 of 21, 14.3%), but these authors were reporting on more complex, comminuted fractures of the greater tuberosity. Less than 1% of operative cases developed a superficial infection or required revision ORIF. Just under 2% of cases suffered postoperative nerve palsies, only 2 of which were permanent.^{6,13} Overall, surgery for displaced greater tuberosity fractures is highly successful, with very low complication rates and high patient satisfaction.

Surgery was divided into 2 groups for data analysis: arthroscopic and nonarthroscopic. The latter group consisted of open procedures—all done through a deltoid-splitting approach—and percutaneous approaches. Both papers describing a percutaneous approach used screw fixation,^{2,26} and Yin et al commented on 2 open patients treated with screws.²⁹

All other open and arthroscopic studies described suture fixation, half with suture anchors and half with transosseous tunnels. Interestingly, no studies reported on clinical outcomes of fragment excision. There were no statistically significant differences in rates of reoperation, stiffness, infection, or neurologic injury between arthroscopic and nonarthroscopic methods.

Anterior shoulder instability has been associated with greater tuberosity fractures. Loss of dynamic muscle stabilization from the rotator cuff is amplified by tuberosity fracture displacement, because anterior shoulder instability was significantly more common in fractures with greater than 5 mm of displacement (44.3% vs 14.5%). In turn, glenohumeral instability was more common in patients treated with surgery, specifically open surgery, because displaced fractures may not be as easily accessed with arthroscopic techniques. No studies documented concomitant labral repair or capsular plication techniques.

Limitations of this systematic review were related to the studies analyzed. All

studies, with the exception of 1,²⁶ consisted of Level IV evidence. The average MCMS was 41.8 ± 8.6. Any MCMS score below 54 is considered “poor” level methodology, but this scoring system is designed for randomized controlled trials,⁴ of which there were none in this study. Physical exam parameters, such as range of motion, were underreported. In addition, radiographic parameters were not consistently described but rather determined by authors’ subjective interpretations of malunion, nonunion, and loss of reduction. Publication and performance bias are inevitable in such studies. Performance bias is a factor in any systematic review with multiple surgeons and a wide variation in surgical technique.

CONCLUSION

In sum, minimally displaced greater tuberosity fractures (< 5 mm) may be successfully treated without surgery; less than 1% ultimately require surgery. Nonoperative management was initially associated with low patient satisfaction, but this was because early studies had treated

Table 3. Comparison of Outcomes Between Fracture Displacement Less Than or Greater Than 5 mm

Parameter	$x^a < 5$ mm (n = 242)	$x^a > 5$ mm (n = 167)	P Value
Age (years)	50.9 ± 7.4	50.9 ± 10.0	> .99
Number with radiographic follow-up	150	146	
Final radiographic follow-up (months)	42.4 ± 11.8	53.1 ± 16.8	.07
Loss of fracture reduction, No. (%)	64 (42.7)	15 (10.3)	< .01 ^b
Heterotopic ossification, No. (%)	0 (0.0)	11 (7.5)	< .01 ^b
Number with clinical follow-up	242	167	
Final clinical follow-up (months)	37.9 ± 9.3	54.2 ± 14.6	< .01 ^b
Constant score	86.6 ± 7.7	84.5 ± 8.9	.55
University of California, Los Angeles score	31.5 ± 1.0	29.6 ± 3.4	.68
Patient satisfaction (%)	N/A ^c	87.4 ± 30.1	N/A ^c
Stiffness (%)	1.9	5.5	.14
Superficial infections (%)	0.0	0.6	.24
Reoperations (%) ^d	0.9	3.7	.17
Reoperations for stiffness (%) ^d	0.9	1.2	.82
Revision fixation (%) ^d	0.0	0.6	.24

^aDisplacement.

^bStatistically significant.

^cThere were insufficient data reporting patient satisfaction in the minimally displaced group ($x < 5$ mm).

^dFor nonoperative management, *reoperations* refers to eventual surgeries during the follow-up period.

Table 4. Comparison of Outcomes Between Open/Percutaneous and Arthroscopic Fixation

Parameter	Open (n = 156)	Arthroscopic (n = 56)	P Value
Age (years)	44.1 ± 8.8	46.4 ± 10.7	.77
Number with clinical follow-up	156	56	
Final clinical follow-up (months)	57.4 ± 12.2	27.4 ± 18.5	< .01 ^a
Patient satisfaction (%)	91.0 ± 14.7	87.8 ± 7.4	.49
Stiffness	5.8	5.4	.91
Superficial infections (%)	0.6	0.0	.57
Nerve injury (%)	1.9	1.8	.96
Reoperations (%)	3.8	3.6	.92
Reoperations for stiffness (%)	0.6	3.6	.11
Revision fixation (%)	0.6	0.0	.57

^aStatistically significant.

Note: There were insufficient radiographic data in the arthroscopic group for comparison with the open-fixation group.

displaced fractures conservatively.^{15,26} Fractures with greater than 5 mm of displacement respond well to surgical fixation with suture anchors or transosseous tunnels. Stiffness is the most common complication, with just

under 6% followed by heterotopic ossification, transient neurapraxias, and infection. There are no discernible differences in outcome between open and arthroscopic techniques. ○

References and financial disclosures are available online at www.rush.edu/orthopedicsjournal.

“While it seems intuitive that simulators will play substantial roles in enabling the successful development of technical skills, how well simulator skills can be applied in the operating room remains undetermined.”

The Effect of Simulator Training on Safety and Clinical Performance of Common Upper Extremity Procedures

RACHEL M. FRANK MD / LAITH AL-SHIHABI, MD / BRANDON ERICKSON, MD
ROBERT W. WYSOCKI, MD / BRETT LEVINE, MD, MS

AUTHOR AFFILIATIONS

Department of Orthopedic Surgery, Rush University Medical Center (Drs Frank, Al-Shihabi, Erickson, Wysocki, and Levine) and Midwest Orthopaedics at Rush (Drs Wysocki and Levine), Chicago, Illinois.

CORRESPONDING AUTHOR

Rachel M. Frank, MD, Department of Orthopedic Surgery, Rush University Medical Center, 1611 W Harrison St, Suite 300, Chicago, IL 60612 (rmfrank3@gmail.com).

INTRODUCTION

The 2013 changes to postgraduate year 1 (PGY-1) orthopedic surgery resident curriculum, authorized by the Accreditation Council for Graduate Medical Education (ACGME), the American Board of Orthopaedic Surgery (ABOS), and Residency Review Committee (RRC) for Orthopaedic Surgery,¹ mandated that residents participate in surgical skills training programs to develop and improve surgical skills. Surgical simulators are one method of enabling residents to develop surgical skills. The goal of simulator training is to enable the trainee to develop a surgical motor skillset that will promote the delivery of safe, effective, and efficient

patient care. While it seems intuitive that simulators will play substantial roles in enabling the successful development of technical skills, how well simulator skills can be applied in the operating room remains undetermined. In particular, there is a dearth of literature describing the available simulation training models for upper extremity procedures, let alone their potential benefit and/or clinical translatability.²⁻⁴ For simulation of arthroscopy techniques of the knee,⁵⁻¹⁵ shoulder,^{9,16-23} and hip,²⁴ multiple studies are available, though their long-term clinical translatability remains under debate.²⁵⁻²⁷

Carpal tunnel release (CTR) and the use of Kirschner wires (K-wires) for fracture fixation are among the most common procedures utilized by orthopedic surgeons. In fact, CTR is 1 of only 15 categories of procedures for which the ACGME requires residents to perform a minimum number of cases. Simulation training for CTR is increasingly becoming a key component of orthopedic resident surgical training and is postulated to improve surgical performance and enhance patient safety. Specific to K-wire use, fluoroscopy is often used to guide pin placement; however, increased radiation exposure due to an excessive number of images can place patients and

staff at risk.²⁸⁻⁴⁰ The impact of simulation training on performing CTR or on placing accurate K-wires with improved (ie, reduced) fluoroscopy use is unknown.

The purposes of this study were to determine the effect of simulation training on (1) performance of mini-open CTR surgery and (2) fluoroscopy use needed for accurate percutaneous K-wire placement. The authors hypothesized that trainees undergoing simulator training would perform better in all aspects of both the CTR task and the K-wire task compared to trainees without simulation training.

METHODS

A randomized controlled trial of medical students and junior orthopedic surgery residents was conducted. We excluded participants for having previous experience witnessing or participating in CTR surgery. All participants received an introduction lecture followed by demonstration of 2 surgical skills: (1) demonstration of the Sawbones, Inc., Hand and Wrist for Carpal Tunnel Training (Vashon, Washington) and (2) demonstration of fluoroscopic-aided percutaneous K-wire placement into the distal radius of a Sawbones, Inc., Encased Wrist (Vashon, Washington).

Table 1. Procedures and Skills Assessed in Simulation Training

Procedures	Skills Assessed
CTR	Completeness of ligament release Deviation from ideal incision location Damage to surrounding structures Time needed to complete the task
Percutaneous K-wire placement	Number of fluoroscopy shots Safety with fluoroscopy Time needed to complete the task Accuracy

We then randomized participants to receive either a fixed protocol of simulation training on the simulation models, or no training. On the day of training (Day 1), we evaluated each participant on his/her performance of (1) performing a CTR on the model (Figure 1) and (2) placement of a percutaneous, bicortical K-wire into the distal radius of the model, perpendicular to the shaft of the radius (Figure 2).

All participants performed the same task 1 week later (Day 8). Table 1 records the variables analyzed. Descriptive analysis consisted of frequencies and percentages for discrete data and means and standard deviations for continuous data. Statistical analyses with t tests and ANOVA were performed for analysis, with $P < .05$ denoting statistical significance.

RESULTS

Ten trainees (4 junior residents, 6 senior students) were randomized into 2 groups: training (T) or no training (NT), with 2 residents and 3 students per group. There were no significant differences in demographics (age, gender, dominant hand) between groups ($P > .05$ in all cases).

Carpal Tunnel Release

In the T group, 60% of participants performed a complete ligament release on Day 1 compared to 100% on Day 8. In the NT group, 60% of participants performed a complete ligament release on both Day 1

and Day 8. There were no statistical differences between the 2 groups on Day 1 or Day 8 in accuracy of incision or time to task completion. In the T group, there were no statistical improvements when comparing performance on Day 1 to that on Day 8. In the NT group, there was a significant improvement in task time (Day 1, 195 ± 43 vs Day 8, 129 ± 8 seconds,

$P = .012$). As a whole, residents performed significantly better than students in task completion time on Day 8 ($P = .007$); otherwise there were no differences between resident and student performance. There were no cases of damage to surrounding structures in either group at either time point.

K-Wire Fixation

There were no significant differences between the groups in the number of fluoroscopy shots used on either day ($P > .05$). Participants in the NT group captured their own hand in their fluoroscopic images (Day 1, 60%; Day 8, 60%) more often than those in the T group (Day 1, 0%; Day 8, 20%). All participants in the T group used both anteroposterior (AP) and lateral views on Day 1 and Day 8, compared to 0% (Day 1) and 50% (Day 8) of participants in the NT group. Three (60%) participants NT group placed their pin “outside” the bone compared to 1 (20%) participant in the T group; no participants in either group were “outside”

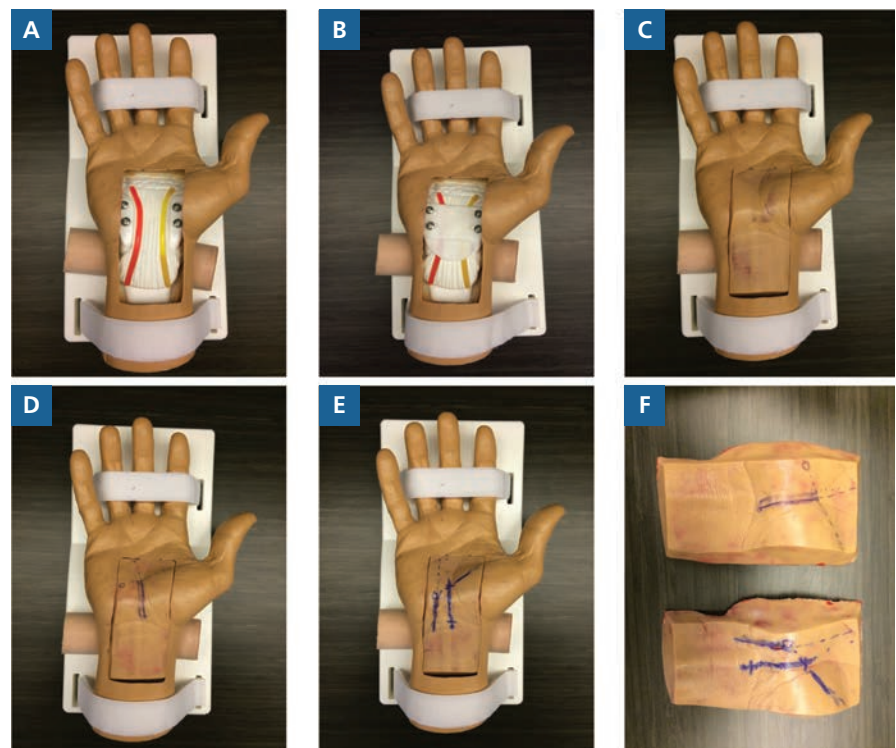


Figure 1. Sawbones, Inc., Hand and Wrist for Carpal Tunnel Training. **A,** Contents of carpal tunnel with transverse carpal ligament removed. **B,** Ligament in place. **C,** Skin in place. **D,** Ideal landmarks and incision. **E,** Deviated incision. **F,** Comparison of ideal and nonideal incisions for simulated carpal tunnel release (CTR).

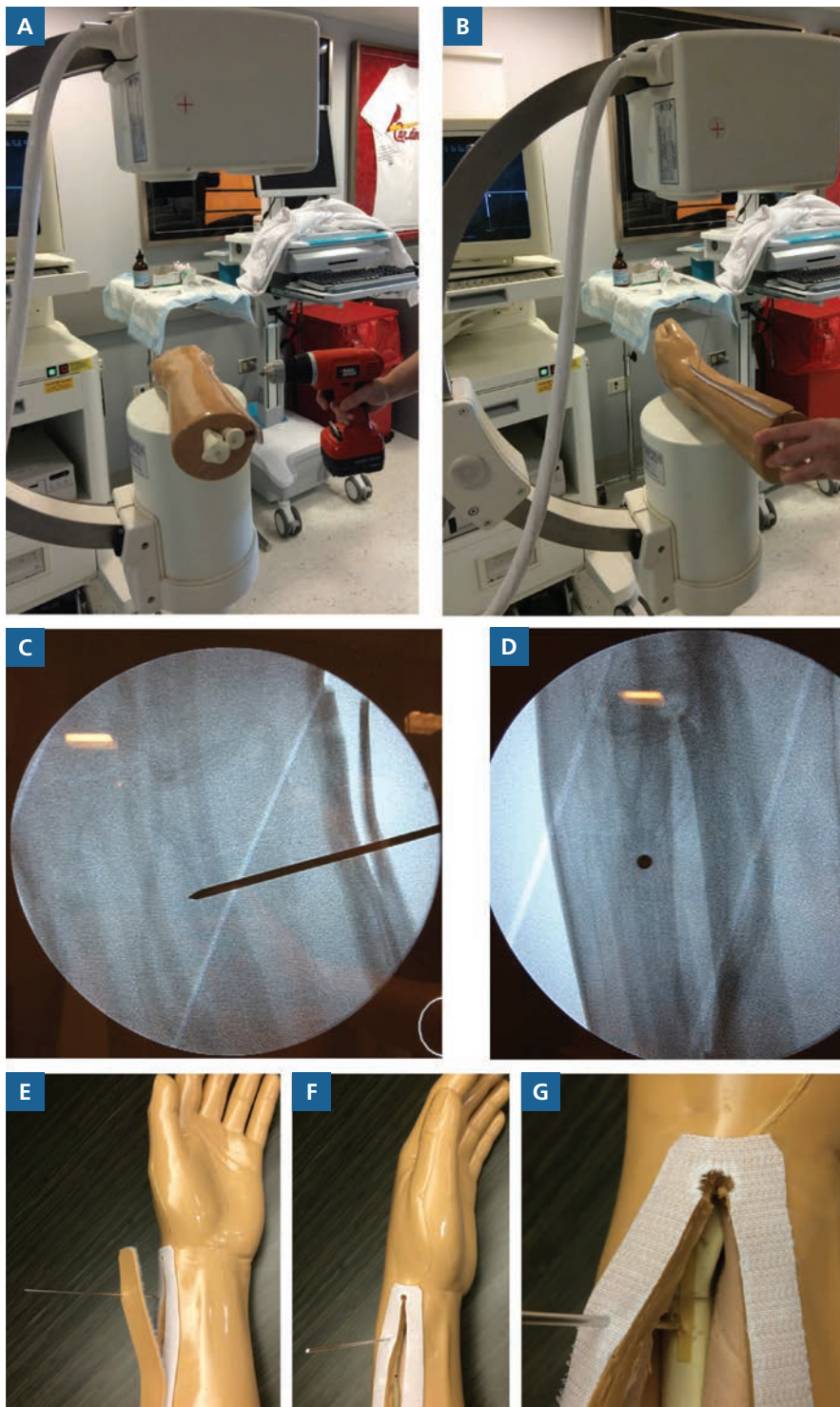


Figure 2. Sawbones, Inc., Encased Wrist Used for K-Wire Placement Simulation. **A**, Anteroposterior (AP) view of K-wire placement under fluoro. **B**, Lateral view under fluoro. **C-D**, AP and lateral views of K-wire placement into distal radius. **E**, K-wire fixation through the Sawbones model. **F**, Skin removed to demonstrate location of pin placement in the sagittal plane. **G**, Close-up view of K-wire placement in the sagittal plane.

the bone on Day 8, demonstrating sagittal plane accuracy. There were no significant differences in pin deviation from the axis of the radius between the groups (coronal plane accuracy, $P > .05$). There were no significant differences in task completion time between the groups on either day ($P > .05$).

DISCUSSION

The principal findings of this study demonstrate that (1) the use of a carpal tunnel release simulation model improves performance in some, but not all, aspects of CTR surgery, (2) participants with more experience perform better than those with

less experience, and (3) participants undergoing simulation training demonstrated safer fluoroscopy practice patterns than those without training: the NT group captured their own hand in the images more often than the T group.

Of all of these findings, perhaps most translatable is the impact of simulation training on safer fluoroscopic practice patterns. Use of fluoroscopy is not without risks, and multiple authors noted substantial exposure to both the staff as well as the patient during cases that involve fluoroscopy.²⁸⁻⁴⁰ In fact, a 2014 study by Vosbikian et al⁴⁰ noted increased exposure to the surgeon's hands using a mini C-arm when compared to a large C-arm. In our study, during the introductory lecture that both groups received, participants were instructed on appropriate use of fluoroscopy, including instructions on how to keep their hands out of the targeted field. However, despite this 1-time instruction to all participants, participants undergoing simulation training demonstrated safer fluoroscopy practice patterns than those without training. Specifically, the no-training group captured their own hand in the images (Day 1, 60%; Day 8, 60%) more often than those in the T group (Day 1, 0%; Day 8, 20%). At the least, therefore, our study suggests that simulation training may allow for safer practice patterns with respect to fluoroscopy use, regardless of the experience level of the trainee.

Regarding trauma-focused simulation studies, several institutions have recently analyzed a variety of simulation models.⁴¹⁻⁴⁵ Yehyawi and colleagues⁴⁵ recently compared the performance of junior and senior residents on a tibial plafond fracture model composed of radio-opaque polyurethane foam encased in a skin/soft-tissue cover, utilizing a motion capture system to analyze hand movements. The authors found that despite comparable numbers of discrete hand motion events (540 actions for senior residents, 511 actions for junior residents), senior residents had a cumulative hand motion distance of 79 m, compared to 390 m for junior residents. They concluded that

senior residents were more precise with their motions than junior residents. These conclusions are similar to those of the present study, in that residents performed better than students on the CTR portion of the study.

Pederson and colleagues⁴⁴ conducted a 2014 study comparing performance between untrained novices and orthopedic surgeons on a virtual hip fracture simulation model. The participants were asked to perform 3 internal fixation techniques. Similar to our study and the study conducted by Yehyawi, the authors found that the experienced surgeons (average score: 73% of maximum) performed better than the novices (average score: 30% of maximum) and were thus able to set a “pass/fail” standard at 58%. With this standard in place, none of the novices passed the standard, while 9 of 10 experienced surgeons passed. The authors concluded that their simulation model could be used to discriminate between novice and experienced surgeons.

A recent study on cast-application simulation found a difference between some, but not all, participants on the basis of their level of training. Specifically, Moktar and colleagues⁴³ recently compared the performance of participants with a variety of experience levels, including orthopedic fellows (including 1 orthopedic technology), residents, and medical students, on their abilities to place a short-arm plaster cast on a synthetic forearm model. While the participants placed the cast, the researchers videotaped their performance. After anonymizing the videos, a panel of 9 experts viewed and graded each participant, using 2 checklists created by the authors [Objective Structured Assessment of Technical Skill (OSATS) and Modified Global Rating Scale (MGRS)]. The authors were able to identify a significant difference in performance when they compared the orthopedic fellow group to the medical student group but were unable to differentiate the orthopedic residents from either the medical students or the orthopedic fellows. They concluded that,

while their model provided high inter- and intraobserver reliability, more work is needed (and likely a study with a larger sample size) to demonstrate construct validity of this particular simulator model.

Overall, the production and analysis of orthopedic simulation training models is growing in popularity. Despite the incredible amount of innovation and technologic advances demonstrated in these and other models, one of the more pressing challenges is determining how effective these models are. To be effective, simulation models must be reliable, valid, and maintain a level of fidelity that is appropriate for the testing analyzed.

High-fidelity simulator models truly mimic the actual operative experience, while low-fidelity simulators, such as our carpal tunnel model or the described cast-application model, reproduce only certain aspects of the surgical technique. The level of fidelity certainly plays a large role in the clinical translatability of the model. Most often, low-fidelity simulators are less complex and more economically feasible to maintain than high-fidelity simulators. On the other hand, high-fidelity simulators, including those that provide haptic feedback (such as a vibrational response following an incorrect motion), may make the training on the model more helpful for translating the specific skill set to the actual clinic and/or operating room. In other fields, including anesthesia and general surgery, a variety of low- and high-fidelity models have demonstrated that each kind is applicable and effective, depending on the specific clinical scenario.

It is important to consider all of these factors when determining how effective a simulator model is with respect to training participants to perform in the “real world.” The simulation models described in the present study are both relatively inexpensive and reproducible. Thus we hope that these pilot studies establish a framework with which we can develop additional studies (with larger sample sizes) to truly establish construct validity, inter- and intraobserver reliability, and ultimately, translatability to the operating room.

Limitations

This study has several limitations, including the small sample size and short-term follow-up. Given the time constraints of trainees and expense of simulation equipment, we had limited resources, and thus it may be difficult to extrapolate our findings to residents/trainees in other programs. Further, the short-term follow-up of 1 week does not allow researchers to determine the overall long-term effect of simulation training on operative performance. Moreover, for a variety of logistical factors, this study did not allow for testing on a cadaveric specimen or in the actual operating room, and thus the true clinical translatability is still undetermined. Additional funding from a 2014 ABOS grant has enabled us to further our research efforts, and we intend to obtain additional long-term follow-up (6 months, 1 year, 2 years) on the current study cohort, increase our sample size, and assess all trainees on fresh-frozen cadaveric models. Finally, similar to the majority of simulation-based studies, this study is limited by a lack of published, validated outcomes assessments with regard to CTR performance and percutaneous K-wire placement performance on simulation models.

CONCLUSIONS

Overall, simulation training resulted in an overall improvement in K-wire accuracy immediately, but not at 1 week following training, and, further, improved performance in some, but not all, aspects of CTR surgery. Importantly, participants undergoing simulation training demonstrated safer fluoroscopy practice patterns. Certainly simulation training has the potential to enable residents to develop skills in a safe environment; however, more research with more participants over a longer period of time is necessary. ○

References and financial disclosures are available online at www.rush.edu/orthopedicsjournal.

“The much higher rate of complications with longer fusion constructs, especially among the elderly, makes it important to identify the cause of hypolordosis.”

Correcting Sagittal Imbalance

A Retrospective Radiographic Study of Decompression and Local Fusion in Cases of Degenerative Scoliosis

PHILIP K. LOUIE, MD / STEVEN PRESCIUTTI, MD / SARAH JOHNSON, BS
EHSAN TABARAE, MD / THOMAS CHA, MD / HOWARD S. AN, MD

AUTHOR AFFILIATIONS

Department of Orthopedic Surgery, Rush University Medical Center (Drs Louie, Presciutti, Tabaraee, and An; and Ms Johnson) and Midwest Orthopaedics at Rush (Dr An), Chicago, Illinois; Department of Orthopedic Surgery (Dr Cha), Massachusetts General Hospital, Boston, Massachusetts.

CORRESPONDING AUTHOR

Philip K. Louie, MD, Department of Orthopedic Surgery, Rush University Medical Center, 1611 W Harrison St, Suite 300, Chicago, IL 60612 (philip_k_louie@rush.edu).

INTRODUCTION

Scoliosis is diagnosed in adult patients when it occurs or becomes relevant after skeletal maturity with a Cobb angle of more than 10° in the coronal plain.¹ The prevalence of adult scoliosis ranges widely from 8.3% to 68% of population,^{2,3} with a higher prevalence occurring among older patients. Scoliosis may have been present since childhood or adolescence and may become progressive and/or symptomatic in adult life, secondary to onset of idiopathic scoliosis, (IS), or degeneration of the idiopathic curve. Scoliosis may also appear de novo in adult life. This latter type is termed *degenerative scoliosis* (DS). Adults with IS usually have a major curve as well as a significant compensatory curve

(Figure 1A), while DS is characterized by a main curve in the lumbar area with a minimal or insignificant compensatory curve in the thoracic spine (Figure 1B).

Asymmetric degeneration of the intervertebral disc and/or facet joints results in the pathologic morphology and mechanism of development of DS. This

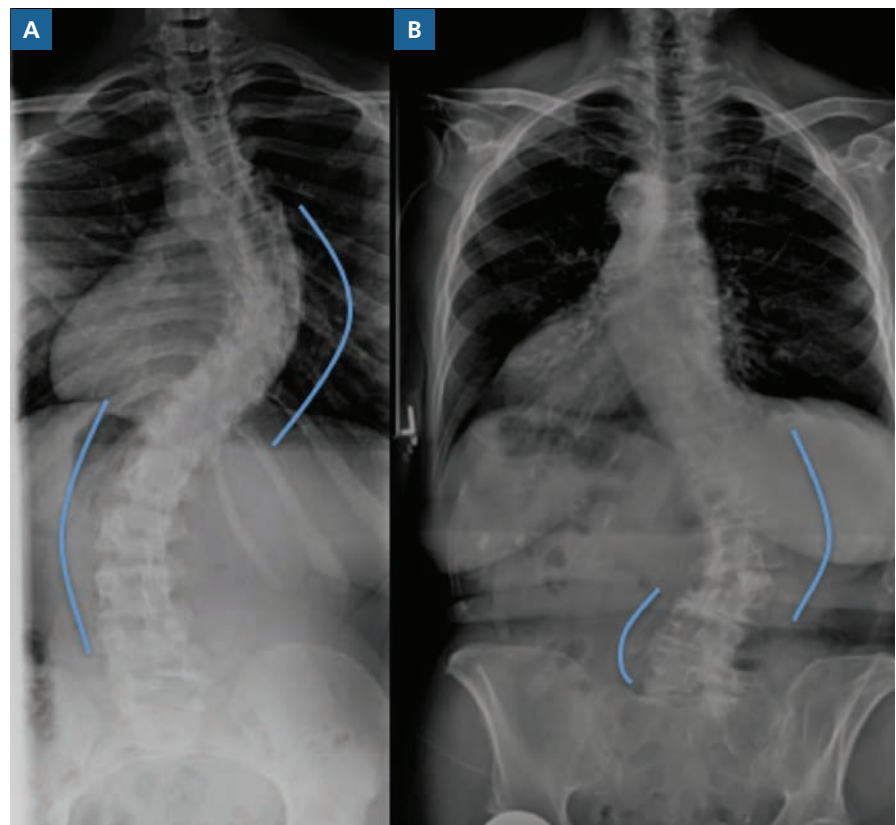


Figure 1. Radiographic comparison of **A**, adult idiopathic scoliosis (IS) and **B**, adult degenerative scoliosis (DS). In IS, the lumbar curve and compensatory thoracic curve are similar sizes. However, in DS, patients generally present with a lumbar curve without a fixed structural secondary curve. Instead, a compensatory lumbar curve is observed in the lower lumbar spine. Additionally, in IS, a rotatory deformity can be observed in the entire lumbar spine (limited to apex of the curve in DS). A lateral subluxation can also be observed in DS spines.

leads to an asymmetric loading of the spinal segment, which in turn leads to an asymmetric deformity. A positive feedback cycle is thus created, with the deformity again triggering further asymmetric degeneration and inducing more asymmetric loading.^{2,4}

While the main symptom of IS is deformity, the symptoms of DS are diverse.⁵ The deformity of DS is compounded by degenerative changes in the vertebral body and discs, which frequently results in the development of spinal stenosis with lower back pain symptoms related to the facet joints and disks as well as lower extremity pain consistent with radiculopathy and/or neurogenic claudication.

A fractional lumbosacral curve, defined as a curvature in the remaining segments between the distal aspect of the thoracolumbar or lumbar curve and the sacrum (usually L3 or L4 to the sacrum), is also typically found in DS. Early studies conducted in painful adult scoliosis patients found fractional curve levels were most responsible for pain and disability in these patients.⁶ This is often due to radiculopathy secondary to nerve root compression on the concavity of the fractional curve.

Additionally, DS is more often accompanied by sagittal and coronal imbalance than IS. These patients typically have lessening of their lumbar lordosis (LL) as well as some degree of compensatory pelvic retroversion.⁷ Full-length spine films in this setting can often show a positive sagittal imbalance.

Ongoing debate regarding the optimal way to address this deformity continues.^{8,9} If nonoperative treatment fails to effectively manage a patient's symptoms, surgery is an option. In addition to decompression of the symptomatic levels, an instrumented posterior spinal fusion is often performed. This can be (1) a short fusion that addresses only the symptomatic levels and ignores the global scoliotic deformity, (2) a regional fusion that includes the major DS curve, or (3) a global fusion (ie, upper instrumented level of T4). Regardless of surgical approach, the goal should be to achieve a postoperative LL within 10° of the pelvic incidence (PI),

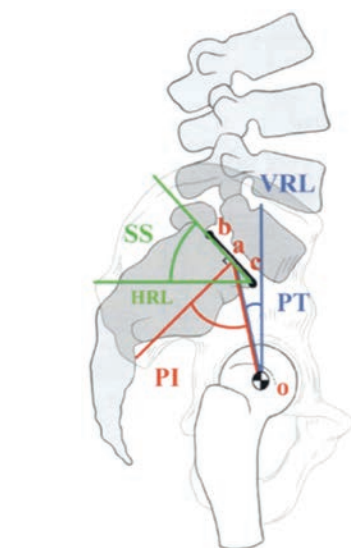


Figure 2. Spinopelvic angles measured in this study. Pelvic incidence (PI) is the angle between the line perpendicular to the midpoint of the superior sacral endplate and a line through the midpoint of the superior sacral endplate to the center of the femoral heads. Sacral slope (SS) is the angle between a horizontal reference line (HRL) and the line through the superior sacral endplate. Pelvic tilt (PT) is the angle between a vertical reference line (VRL) and the line through the midpoint of the superior sacral endplate to the center of the femoral heads.

because this has been shown to correspond to better quality of life.¹⁰

An important distinction to make is whether or not the etiology of the loss of LL and positive sagittal imbalance often seen on preoperative radiographs is truly structural or whether it is more positional, given that spinal stenosis often accompanies DS. This directly affects the decision about whether or not the entire curve needs to be addressed or if a lesser fusion of only the symptomatic levels can be performed with satisfactory result.

Our hypothesis is that the loss of LL often associated with DS is largely due to postural factors and is not structural. By analyzing the pre- and postoperative spinopelvic radiographs of patients who underwent decompression and local fusion of their symptomatic lumbosacral fractional curve only, we hoped to observe an appropriate magnitude of correction in the sagittal plane (PI-LL mismatch $\leq 10^\circ$) without the addition of longer fusions or osteotomy procedures.

METHODS

We retrospectively reviewed the records of consecutive patients from a single

orthopedic surgeon at one quaternary referral medical center. After obtaining institutional review board (IRB) approval, we collected clinical and radiographic data on 114 patients treated between February 2006 and September 2014. We included patients if we observed hypolordosis (positive sagittal imbalance) on their preoperative radiographs and if they had undergone a decompression and local fusion of only their symptomatic levels in the setting of DS. Local fusion was defined as arthrodesis of the symptomatic levels, limited to the fractional curve. Patients were excluded if they had a previous fusion or osteotomy procedure. Of the 114 patients originally identified, 68 were found to fulfill the preceding criteria. Radiographs included pre- and postoperative full-length scoliosis and lumbar spine X-rays. We analyzed preoperative and postoperative anteroposterior (AP) and lateral standing radiographs for the following parameters (Figure 2):

Lumbar lordosis (LL): the angle formed between the superior endplate of L1 to the superior endplate of S1

Pelvic incidence (PI): the angle between the line perpendicular to the midpoint of the superior sacral endplate and the line through the midpoint of the superior sacral endplate to the center of the femoral heads

Sacral slope (SS): the angle between a horizontal reference line (HRL) and the line through the superior sacral endplate

Pelvic tilt (PT): the angle between a vertical reference line (VRL) and the line through the midpoint of the superior sacral endplate to the center of the femoral heads

Three independent researchers made these measurements and calculated statistical averages and standard deviations for each. Interrater reliability measurements were assessed by Kappa coefficient testing. The results of the calculations are shown in Table 1.

RESULTS

Over a 103-month period, we collected clinical and radiographic data from 68 consecutive patients that were captured within our criteria (Table 2). There were

Table 1. Measured Radiographic Parameters Showing Degrees of Angulation Between the Upper and Lower Vertebrae of the Curve

Parameter	Cohort, n = 69 (Degrees [range])
Pelvic incidence	
Preoperative	53.0 ± 13.0 (25.3-81)
Postoperative	54.8 ± 11.3 (30.4-83.2)
Sacral slope	
Preoperative	28.2 ± 10.8 (5.6-60.4)
Postoperative	26.9 ± 10.0 (3.7-57.2)
Pelvic tilt	
Preoperative	23.9 ± 9.5 (2.2-45.7)
Postoperative	27.0 ± 9.5 (10.2-46.6)
Lumbar lordosis	
Preoperative	32.6 ± 14.5 (2.4-60.0)
Immediately postoperative	43.6 ± 11.6 (14.0-67.9)

Table 2. Demographics for the Final Cohort of Included Patients

Parameter	Cohort (n = 69)
Age, y	68.1 ± 8.3
Gender	
Male, No. (%)	24 (35)
Female, No. (%)	45 (65)
Follow-up (months)	21.7 ± 19.1
Prior decompression, No. (%)	12 (17)

24 males and 45 females with an average age of 68.1 years (range, 42-86). The average follow-up was 21.7 months (range, 1-86). All patients underwent conservative therapies of physical therapy, orthosis, and/or anti-inflammatory or pain medication prior to deciding upon surgical intervention. A previous decompression of the lumbar spine had been performed in 12 patients.

Of the 69 patients, concomitant laminectomy and foraminotomy were performed in 64 and 63, respectively. The fusion was most commonly performed from L4 to S1 (2 segments) and secondly, L3-S1 (3 segments).

The average PI angles found pre- and postoperatively were 53° and 54°, respectively. Preoperative LL had a mean Cobb angle of 32.6° (range, 2.4°-60°). Initial postoperative radiographs (average 2.5 weeks) revealed that the LL was

corrected to a mean Cobb angle of 43.6° (range, 14°-67.9°). These results are summarized in Figure 3. There were no intraoperative complications.

Seven patients required revision procedures at an average of 17.6 months (range, 2.2-34.3) from the index procedure. Three patients experienced recurrent stenosis at their fused levels, requiring revision decompression. Two patients underwent a revision laminectomy and foraminotomy at the proximal segment due to radicular symptoms secondary to degenerative disc disease and proximal junctional kyphosis. One patient, who originally underwent a L4-S1 laminectomy and instrumented fusion, suffered a herniated nucleus pulposus at L3-L4 requiring a microdiscectomy and laminectomy with extension of the fusion 1 level cephalad. One patient also had prominent instrumentation that required removal.

DISCUSSION

DS is a common cause of adult spinal deformity that represents a complex 3-dimensional deformity, affecting the coronal, sagittal, and axial planes.^{4,11} Spinal stenosis with symptoms of neurogenic claudication is frequently observed with DS. Radicular symptoms often arise from compression of the nerve roots within the foramen and typically occur on the concave side of the fractional curve caudal to the main DS curve. It is our experience that the majority of these radicular symptoms often arise from the L5 and/or S1 nerve root, which we found in 54 of our 68 patients.

Previous studies have demonstrated a relationship between curve concavity and the side and pattern of radiculopathy. Simmons and colleagues¹² showed that patients with scoliosis and radiculopathy had symptoms originating from lumbar curve concavities: L5 and S1 radiculopathy originating in 7 of 9 cases from the side of the concavity of the lumbosacral fractional curve. In a more recent study, Liu et al used selective nerve-root injections to identify symptomatic radiculopathy in adults with DS. The authors found L3 and/or L4 nerve root compression at the lumbar structural curve concavity in 15 of 20 cases and L5 and/or S1 nerve compression on the side of the lumbosacral fractional curve concavity in 12 of 16 cases.

For fear of inadequacy of decompression alone for foraminal stenosis, we performed instrumented fusions in our patients. Compression of nerve roots within their foramen in lumbosacral fractional curve concavities often occurs in both anterior-posterior and cranial-caudal directions, the latter often referred to as *pedicular kinking*. While anterior-posterior compression can be effectively reduced with good surgical technique during a decompression-only procedure, it is much more difficult to address cranial-caudal compression without transpedicular instrumentation.¹³ Pedicular kinking occurs when advanced disc degeneration results in settling of the vertebral bodies. As the upper vertebral body descends

during weight bearing, its pedicle may kink the exiting nerve root to a significant degree. In addition to providing immediate stability, transpedicular instrumentation facilitates reduction in pedicular kinking and indirect decompression of the foramen after segmental pedicular distraction. In a cadaveric study, Inufusa and colleagues¹⁴ were able to increase the foraminal dimensions by 22.6% at L4-5 and by 39.6% at L5-S1 with only 6 mm of rod distraction.

A consideration in treating adult DS patients is how long a fusion to perform. Patients with a symptomatic DS often have a loss of LL as seen on preoperative radiographs. An important distinction is whether this hypolordosis is truly structural, and therefore requires complex surgical correction such as regional/global fusions or osteotomies, or whether it is more positional in nature. This distinction directly affects whether or not the entire curve needs to be addressed with longer regional/global fusions or if a lesser local fusion can be performed. The much higher rate of complications with longer fusion constructs,^{4,9,15,16} especially among the elderly, makes it important to identify the cause of hyperlordosis.

Because of the previous experience of the senior author, we hypothesized that

the hypolordosis seen on preoperative radiographs was due largely to positional factors. Given that these patients often have associated spinal stenosis and poor standing tolerance due to symptoms of neurogenic claudication, it is not likely that this sagittal deformity is rigid and structural. We therefore elected to perform decompression and local fusion of only the symptomatic levels and ignore most of the deformity of the main DS curve cephalad. We based this decision on the idea that, if the hypolordosis seen preoperatively was only positional, including correction when prone on the operating room table, it would likely correct once the patient was no longer standing.

Many surgeons, particularly with recent awareness of the importance of sagittal alignment on postoperative quality of life,¹⁰ consider hypolordosis in this subset of DS patients an indication for longer regional/global fusion constructs or osteotomies as ways to decrease the PI-LL mismatch. While these are powerful methods, we wanted to investigate, with this study, if the same goal of achieving a PI-LL mismatch less than 10° could be achieved with lesser surgery. Radiographically, successful correction of sagittal imbalance can be calculated on the basis of PI.^{17,18,19,20} Specifically, Berjano

and colleagues^{7,17} showed that correcting LL to within 10° of the PI is effective to produce proper alignment, thereby improving the clinical sequelae produced from the sagittal imbalance of adult DS. Similarly, Schwab et al²¹ developed an equation, $LL = PI \pm 9^\circ$, to predict the ideal LL for good clinical outcome.

Pelvic incidence has been found to be an important constant morphometric parameter that may dictate the amount of LL needed to achieve a globally aligned spine. It is independent of age, once growth is completed; pelvic position; and negligible SI joint mobility.²² As expected, there was no difference in PI following the local lumbar fusion performed in our study. The average PI found pre- and postoperatively after decompression and local fusion was 53° and 54°, respectively.

As described above, the LL of our patient cohort presented with a mean Cobb angle of 32.6° (range, 2.4-60). This is in line with the expected degenerative collapse and decompensation of lumbar segments described in previous studies.^{7,23}

Our study revealed that we were, in fact, able to achieve a satisfactory reduction of the PI-LL mismatch after decompression and local fusion of a symptomatic DS without the need for a longer fusion or even osteotomies (Figure 4). Our results indicate that it is possible to achieve adequate correction of sagittal balance with a shorter, local fusion procedure without the need for regional/global fusions or even osteotomies. These results lend themselves to the ideas that the hypolordosis often observed preoperatively is not structural, that it is perhaps more positional in nature, and that the PI-LL mismatch can be reduced to near target levels without longer, more complex procedures.

Multiple studies have investigated the idea that postoperative lumbar hypolordosis may not always be structural and how LL can change, depending on position. Pain-related voluntary or involuntary muscle contraction has been shown to lead to a reduction in LL in the upright position.²⁴ During surgery, this effect is mitigated

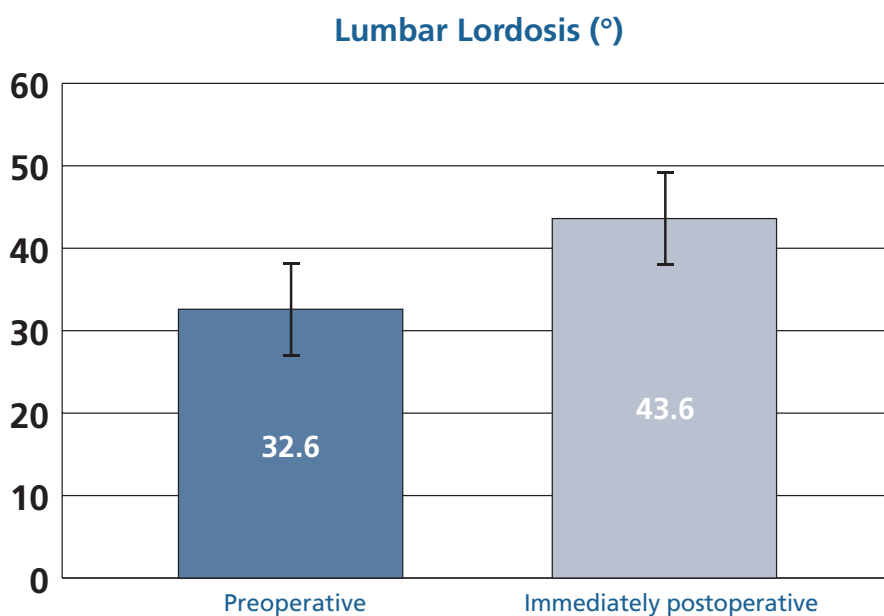


Figure 3. Mean Cobb Angle: Preoperative and Immediately Postoperative.

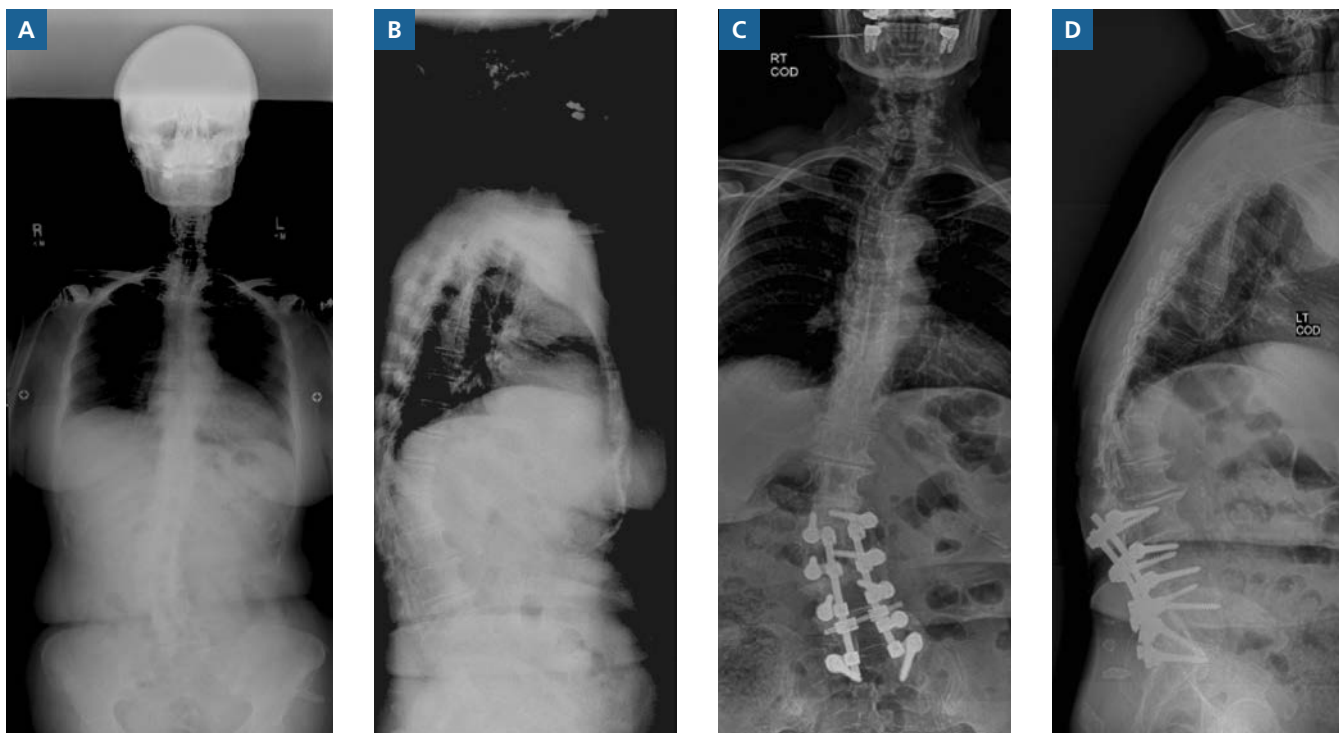


Figure 4. This 69-year-old female had progressive neurogenic claudication and back pain. **A**, Anteroposterior (AP) and **B**, lateral radiographic findings show a degenerative lumbar scoliosis. PI-LL mismatch preoperatively at 19°. L3 to S1 decompression and posterior spinal fusion of her lumbar curve with instrumentation reduced her PI-LL mismatch to 9°. Postoperative radiographs show resulting **C**, fractional curve and **D**, lumbar lordosis.

secondary to the muscle relaxation effect of general anesthesia as well as intraoperative muscle dissection. Harimaya and colleagues²⁵ examined patients who presented with lumbar hypolordosis and concluded that those patients with preoperative hypolordosis, when positioned prone during reconstructive surgery, had a significantly increased LL compared to their preoperative standing radiographs. Additionally, Peterson et al²⁶ found that positioning a patient prone on a Jackson table increased segmental lordosis at L5-S1 by 22% and preserved total and segmental standing lordosis at all other levels.

We should note that, in our study, we found no difference between the preoperative and postoperative SS (28.2° vs 26.9°, respectively) or PT (23.9° vs 26.9°, respectively). A similar finding was observed in short fusions performed on patients with degenerative spondylolisthesis by Kim and colleagues.²⁷ They achieved significant improvement in the LL without significant changes in the SS or PT. Baghdadi et al⁷ studied a similar DS patient population that had undergone posterior instrumented spinal fusion. They also found no significant changes in PT or SS with adequate correction of LL.

This may be partly due to the difficulty in changing pelvic parameters without fusing across the sacroiliac (SI) joint.

Limitations of this study include the relatively small numbers of patients and the short duration of follow-up. We also did not record any subjective or objective clinical outcomes for many of these patients, including pain, symptom relief, or range of motion. Although significant improvements in radiographic measures were observed, we cannot directly correlate these findings with subjective or objective clinical outcomes. Additionally, our study focused on a very specific patient cohort, those with DS who underwent local fusions of their symptomatic levels only. Presumably there were many other patients who underwent regional or global fusions because their deformities were more severe. Our study's findings cannot be more broadly applied to all adult deformity patients.

CONCLUSION

The operative management of DS remains challenging and is characterized by a variety of approaches. We were able to correct LL to within 10° of the PI in this cohort of symptomatic DS patients

with decompression and local/short instrumented fusion of their symptomatic levels only, without the intraoperative and postoperative complications often seen with long instrumented fusions and osteotomy procedures. Importantly, we recommend this technique only for moderate scoliosis curves with mild subluxation of the apical vertebra.⁸ Longer fusions (regional or global) for curve and sagittal balance correction are generally indicated in the setting of more severe curves or in the presence of progressive collapse without a single level identified as a pain source. ○

References and financial disclosures are available online at www.rush.edu/orthopedicsjournal.

“...while the literature on pigmented villonodular synovitis of the hip may still be limited, this review provides insight into expected outcomes.”

Pigmented Villonodular Synovitis of the Hip

A Systematic Review

DAVID M. LEVY, MD / BRYAN D. HAUGHOM, MD / SHANE J. NHO, MD, MS / STEVEN GITELIS, MD

AUTHOR AFFILIATIONS

Department of Orthopedic Surgery, Rush University Medical Center (Drs Levy, Haughom, Nho, and Gitelis) and Midwest Orthopaedics at Rush (Drs Nho and Gitelis), Chicago, Illinois.

CORRESPONDING AUTHOR

David M. Levy, MD, Department of Orthopedic Surgery, Rush University Medical Center, 1611 W Harrison St, Suite 300, Chicago, IL 60612 (david_levy@rush.edu).

INTRODUCTION

Pigmented villonodular synovitis (PVNS) is a rare monoarticular disorder that affects the joints, bursa, or tendon sheaths of 1.8 patients per 1 000 000.^{1,2} It is defined by the exuberant proliferation of synovial villi and nodules. Although its etiology is unknown, it behaves much like a neoplastic process with occasional chromosomal abnormalities, local tissue invasion, and the potential for malignant transformation.^{3,4} Radiographs may show cystic erosions or joint-space narrowing, while magnetic resonance imaging (MRI) reveals characteristic low signal intensity on both T1- and T2-weighted sequences due to high hemosiderin content. Biopsy remains the gold standard for diagnosis and demonstrates hemosiderin-laden macrophages, vascularized villi, mononuclear cell infiltration, and sporadic mitotic figures.⁵ Diffuse PVNS appears as a thickened synovium with matted villi and synovial folds, while localized PVNS

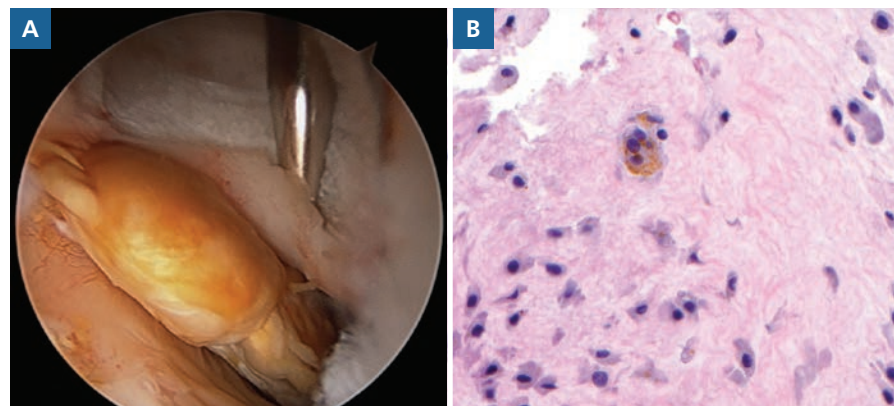


Figure 1. A, Arthroscopic image of a yellowish-red mass with frond-like projections consistent with hip PVNS in a 24-year-old woman with groin pain. B, A hemosiderin-laden macrophage is identified via a CT-guided core needle biopsy.

presents as a pedunculated, firm, yellow nodule (Figure 1).⁶

PVNS has a predilection for large joints, most commonly the knee (up to 80% of cases) followed by the hip.^{1,2,7} Treatment strategies of knee PVNS have been well studied and, as an aggregate, show no superiority between arthroscopic and open techniques.⁸ The literature on hip PVNS is less abundant and more case based, making it difficult to reach a consensus on effective treatment. Open synovectomy and arthroplasty have been the mainstays of treatment for the past 60 years, but the advent of hip arthroscopy has introduced a new treatment method for PVNS.^{1,9} As arthroscopic management becomes more readily available, it is therefore important to understand the effectiveness of synovectomy compared to arthroplasty. The purpose of this systematic review is to describe the

treatment modalities for hip PVNS, to determine the relative efficacy of synovectomy versus arthroplasty, and to compare the revision rates between procedures.

METHOD

Search Strategy

We conducted a systematic review of the available literature according to Preferred Reporting Items for Systematic Reviews and Meta-Analyses (PRISMA) guidelines using the PRISMA checklist.¹⁰ Searches were completed in July 2014 using the MEDLINE/PubMed databases and the Cochrane Central Register of Clinical Trials. We designed the keyword selection to capture all Level I-V evidence English-language studies that reported clinical and/or radiographic outcomes. This was accomplished using a keyword search of all

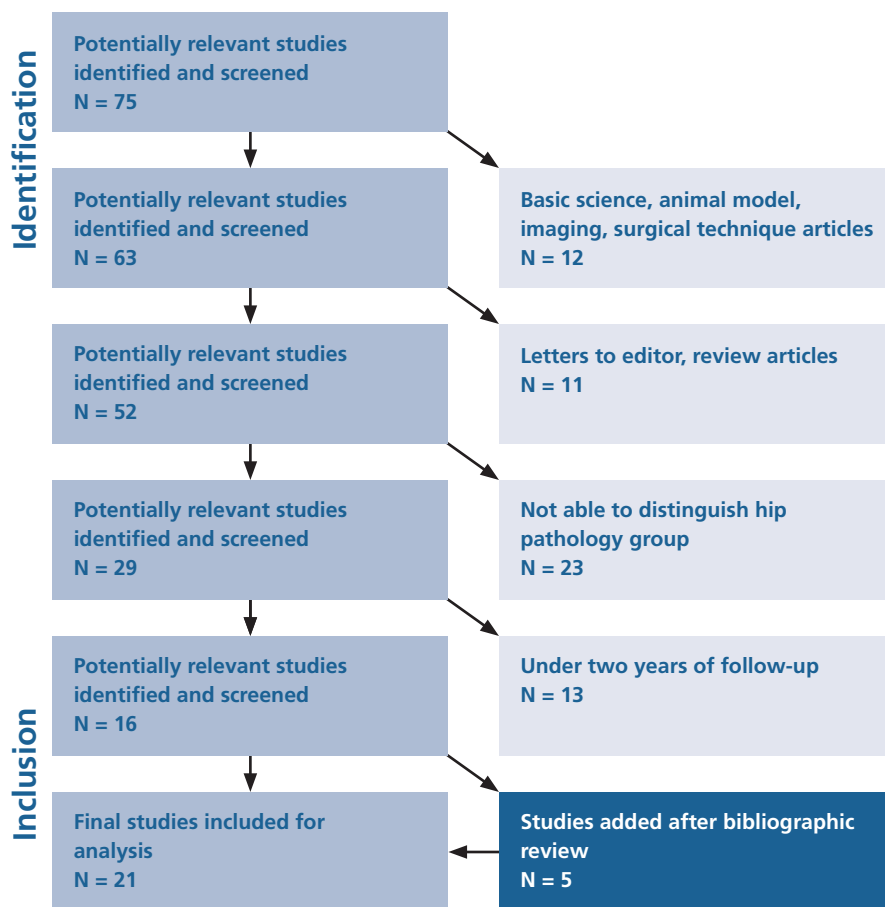


Figure 2. Systematic Review Search Algorithm According to PRISMA Guidelines.

available titles and manuscript abstracts. We reviewed abstracts from the 75 resulting studies for exclusion criteria, which consisted of any cadaveric, biomechanical, histologic, and/or kinematic results as well as a lack of any clinical and/or radiographic data (eg, review or technique articles). We also excluded studies that did not have at least 2 years of clinical follow-up. We did not immediately exclude studies that were not dedicated to hip PVNS specifically but rather reviewed them for outcomes data specific to the hip PVNS subpopulation. If we could distinguish a specific hip PVNS population distinct from other subjects, we included that study for review. If a study could not be deconstructed as such or was entirely devoted to one of our exclusion criteria, we excluded it from our review. This initial search strategy yielded 16 studies.^{1,6,7,11-28}

Bibliographical review from these 16 studies yielded several more studies that were reviewed. To ensure that no patients were counted twice, each study's authors, data collection period, and ethnic population were reviewed and compared to those of

the other studies. If there was any overlap in authorship, period, and place, we included only the study with the most relevant or comprehensive data. After accounting for all inclusion and exclusion criteria, a total of 21 studies with 86 patients (86 hips) were selected for inclusion (Figure 2).

Data Extraction

We recorded details of study design, sample size, and patient demographics, including age, sex, and duration of symptoms. The presence of a diagnostic biopsy, joint-space narrowing on radiographs, the method of treatment, and the use of radiation therapy were also abstracted. Some studies described multiple treatment methods. If those treatment methods could not be differentiated into distinct outcomes groups, we excluded the study for a lack of specific clinical data. We deconstructed those studies that had sufficient data, such that the patients from each treatment group were isolated.

Fewer than 5 studies either reported physical examination findings, validated

survey scores, or radiographic results. Therefore, the primary outcomes reported and compared between treatment groups were disease recurrence; clinical worsening, defined as progressive pain or loss of function; and revision surgery. We subdivided patients with the latter outcome into those who had a repeat synovectomy and those who had an eventual arthroplasty, arthrodesis, or revision arthroplasty. We also documented the time to revision surgery. Each study's methodological quality and bias were evaluated using the modified Coleman methodology score (MCMS) described by Cowan et al.²⁹ The MCMS is a 15-item instrument that has been used to assess both randomized and nonrandomized patient trials.^{30,31} It has a scaled potential score ranging from 0 to 100, with scores from 85 to 100 being excellent; 70 through 84, good; 55 through 69, fair; and less than 55, poor.

Statistical Analysis

We reported our data as weighted means with standard deviations. A mean was calculated for each study reporting on a respective data point, and each mean was then weighed according to its study sample size. This calculation was performed by multiplying 1 study's individual mean by the number of patients enrolled in that study and dividing the sum of these weighted data points by the number of eligible patients in all relevant studies. In this way, the nonweighted means from studies with a smaller sample size did not carry as much weight as those from larger studies. The 2 primary treatment groups compared were those who received a synovectomy alone and those who underwent arthroplasty. The former group was also compared to patients who underwent total hip arthroplasty (THA) specifically (Figure 3). Comparisons between groups were made with student *t* test (SPSS v.18; IBM Inc., Armonk, NY), and an α value of .05 was set as statistically significant.

RESULTS

The final data set included a total of 21 studies representing 86 subjects (Table 1). Nineteen studies were retrospective case series (Level IV evidence) from which the number of

eligible hip PVNS subjects ranged from 1 to 13. The remaining 2 studies were case reports (Level V evidence). The average MCMS was 25.0 ± 10.9 .

Fifty-one patients (59.3%) were female. The average age of all patients was 33.2 ± 12.6 years, and the average duration of symptoms was 4.2 ± 2.7 years. The right hip was affected in 59.5% of patients in whom laterality was documented. Sixty-eight subjects (79.1%) had biopsy-proven PVNS, while the presence or absence of a biopsy was not documented for the remaining 18 patients.

For treatment, 45 subjects (52.3%) underwent synovectomy without arthroplasty. Two of these patients underwent staged radiation to augment the synovectomy, and 1 series reported 13 cases of arthroscopic synovectomy,¹ with all other synovectomies being open. Thirty-seven patients (43.0%) underwent arthroplasty at the time of synovectomy, and, within that group, there

were 26 THAs, five cup arthroplasties (interposed vitallium surface placed without fixation after reaming the femoral head and acetabulum for congruency), two metal-on-metal hip resurfacings, and one hemiarthroplasty. Of the remaining subjects, three were managed nonoperatively and one was treated with a primary arthrodesis.

Comparisons between the synovectomy and arthroplasty treatment groups may be found in Table 2. On average, synovectomy patients were younger than arthroplasty patients, but this was not statistically significant ($P = .28$). Only 6 studies distinguished between local and diffuse PVNS histology, and the diffuse type was detected in 87.0% with insufficient data to detect a difference between synovectomy and arthroplasty groups. Among studies with documented radiographic findings, 75.0% of patients had evidence of joint-space narrowing, which was significantly more common in the arthroplasty group (96.7% vs 31.3%) ($P = .03$).

The average clinical follow-up was 8.4 ± 5.9 years for all subjects. A greater percentage of synovectomy patients suffered recurrence and worsened symptoms, but neither trend achieved statistical significance. The rate of eventual THA or arthrodesis after synovectomy was nearly identical to the rate of revision THA in the arthroplasty group (26.2 vs 24.3) ($P = .17$). The time to revision surgery, however, was significantly longer in the arthroplasty group ($P = .02$). Two additional patients in the arthroplasty group had a repeat synovectomy alone, while 0 patients in the synovectomy group had a repeat synovectomy without arthroplasty.

One nonoperatively managed patient experienced progression of his symptoms over the course of 10 years, while the other 2 subjects were stable after 2 and 4 years of follow-up. The arthrodesis patient did not experience a recurrence or revision operation in the 5 years after his index procedure.

DISCUSSION

PVNS is a proliferative disorder of synovial tissue with a high risk of recurrence.^{15,32} Metastasis is extremely rare: there has been only 1 case report of a fatality within 42 months.¹² Chiari et al suggested that PVNS recurrence is greatest in large joints. Therefore, hip PVNS necessitates early surgical resection to limit articular destruction and the potential for recurrence. The 2 primary treatment modalities are synovectomy alone and synovectomy with arthroplasty, which includes THA, cup arthroplasty, hip resurfacing, and hemiarthroplasty. In this systematic review, we found that about one-quarter of all patients from both treatment groups ultimately underwent a revision operation. Patients with a prior synovectomy underwent revision within an average of 6.5 years, whereas the time to revision was significantly longer in the arthroplasty group, nearly 12 years. One potential explanation for this is that it may take longer for arthroplasty component fixation to loosen than for an inadequately synovectomized joint to recur. We did in fact find a higher rate

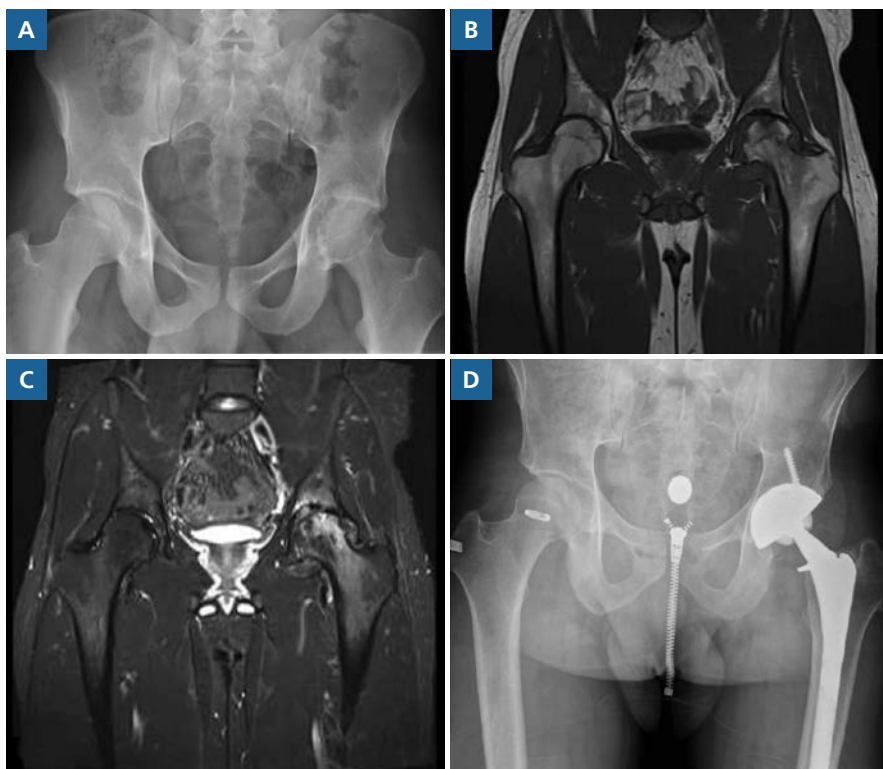


Figure 3. Anteroposterior (AP) radiograph of the pelvis in a 22-year-old male demonstrates advanced joint-space narrowing and cortical erosions in the femoral head and acetabulum of the left hip (A). Magnetic resonance imaging reveals characteristic synovial process with low signal intensity in both T1- and T2-weighted sequences (B and C, respectively). This patient underwent total hip arthroplasty (D).

Table 1. All Studies Included for Review

Author(s)	Level of Evidence	N	Treatment(s), n*	MCMS
Shoji et al ¹¹	IV	2	Synovectomy (open)	27
Byrd et al ¹	IV	13	Synovectomy (arthroscopic)	49
Li and Jeffery ¹²	V	1	Hemiarthroplasty	15
Hoberg and Amstutz ¹³	IV	2	Hip resurfacing	15
Yoo et al ¹⁴	IV	8	THA	46
Park et al ²⁸	V	1	THA	15
Chiari et al ¹⁵	IV	3	Synovectomy (open)	35
Vastel et al ¹⁶	IV	15	Synovectomy (open), 8 THA, 4 Cup arthroplasty, 3	31
Shabat et al ¹⁷	IV	1	Synovectomy (open, plus adjuvant radiation)	40
Gonzalez Della Valle et al ¹⁸	IV	3	Synovectomy (open), 1 Nonoperative, 2	34
Martin et al ⁶	IV	4	Synovectomy (open), 1 THA, 3	30
de Visser et al ¹⁹	IV	3	Synovectomy (open), 1 Synovectomy (open, plus adjuvant radiation), 1 THA, 1	27
Aboulafia et al ²⁰	IV	1	Synovectomy (open)	15
Moroni et al ²¹	IV	4	Synovectomy (open)	27
Aglietti et al ²²	IV	6	Synovectomy (open), 4 THA, 2	15
Danzig et al ⁷	IV	5	Synovectomy (open), 1 THA, 2 Arthrodesis, 1 Nonoperative, 1	24
Docken ²³	IV	1	Synovectomy (open)	15
Scott ²⁴	IV	1	Synovectomy (open)	15
Chung and Janes ²⁵	IV	2	THA, 1 Cup arthroplasty, 1	18
McMaster ²⁶	IV	2	Synovectomy (open)	15
Ghormley and Romness ²⁷	IV	4	Cup arthroplasty	18

Abbreviations: MCMS, modified Coleman methodology score; N, number of patients per study who were eligible for this review; n, number of patients per treatment; THA, total hip arthroplasty.

*If there is no value for n, then number of treatments = N in third column.

of recurrence in the synovectomy group, although this difference did not achieve statistical significance.

Open synovectomy is the most widely described technique for addressing hip PVNS. The precise pathophysiology of PVNS remains largely unknown, but most authors agree that an aggressive debridement is required to halt its locally invasive course. Scott described the invasion of vascular foramina from

synovium into bone and felt that radical synovectomy was essential to remove the stalks of these synovial villi.²⁴ Furthermore, PVNS most commonly affects younger adults in their third through fifth decades of life,⁷ and many surgeons wish to avoid prosthetic components that may loosen over time in this age group. However, synovectomy has been troubled by persistently high recurrence rates, and, without removal of the femoral head and neck, it can be difficult to obtain adequate

exposure for a complete debridement. Adjuvant external beam radiation has been utilized by some authors,^{17,19,33} but its utility is unproven, and other authors caution against unnecessary irradiation to reproductive organs.^{1,24,34}

The high frequency of bony involvement, joint destruction, and recurrence after synovectomy has prompted many surgeons to turn to arthroplasty. Gonzalez, Della Valle, et al theorized that joint-space

Table 2. Comparison of Synovectomy and Arthroplasty Patients

	Synovectomy (n = 45)	Arthroplasty: ALL (n = 37)	P Value ^a	Arthroplasty: THA only (n = 26)	P Value ^a	TOTAL (n = 86)
Age (y)	31.0 ± 11.3	36.7 ± 14.8	.28	36.4 ± 14.1	.43	33.2 ± 13.0
Duration of symptoms (y)	3.2 ± 2.4	4.9 ± 2.9	.22	5.7 ± 3.0	.08	4.2 ± 2.7
Preoperative joint-space narrowing (%)	31.3	96.7	.03 ^b	100	.02 ^b	75.0
Average follow-up (y)	7.3 ± 6.6	10.0 ± 5.9	.65	10.1 ± 5.1	.71	8.4 ± 5.9
Recurrence (%)	17.8	5.4	.30	3.8	.33	12.0
Worsening symptoms (%)	40.5	32.4	.55	26.9	.37	36.1
Eventual THA or revision THA (%) ^c	26.2	24.3	.17	23.1	.18	24.1
Average time to revision (y)	6.5 ± 3.9	11.8 ± 4.5	.02 ^b	11.9 ± 5.2	.08	8.6 ± 5.3

^aAll P values reported here represent t tests used to compare either synovectomy and all arthroplasty patients or synovectomy and just total hip arthroplasty patients.

^bStatistical significance.

^cTwo patients in the synovectomy group underwent eventual arthrodeses (ie, not arthroplasty).

narrowing is more common in hip PVNS because of the poor distensibility of the hip capsule compared to that of the knee and other joints.¹⁸ In turn, bony lesions and arthritis present earlier in hip PVNS.¹⁴ Yoo et al showed a statistically significant increase in Harris hip scores and a high rate of return to athletic activity after THA for PVNS.¹⁴ However, these authors also reported revisions for component loosening and osteolysis in 2 of 8 patients and periprosthetic osteolysis without loosening in another 2 patients. Vastel et al similarly reported aseptic loosening of the acetabular component in half of their patient cohort.¹⁶ No studies to date have been able to differentiate whether or not accelerated loosening rates in this demographic are due to PVNS recurrence or debris-related osteolysis.

Byrd et al recently described hip arthroscopy in the treatment of PVNS.¹ In their cohort of 13 patients, they demonstrated statistically significant improvements in Harris hip scores, no postoperative complications, and only 1 revision operation (a THA at 6 years postoperatively). While there is a prevailing perception that nodular PVNS is more appropriately treated by arthroscopic excision than diffuse PVNS, no studies have reported data to this effect: in fact Byrd et al showed a trend of slightly

better outcomes in diffuse PVNS than in the nodular variant.¹ The primary challenge of hip arthroscopy is its steep learning curve and the ability to obtain adequate exposure. Recent innovations include additional arthroscopic portals and an enlarged T-capsulotomy, which may be contributing to decreased complication rates in hip arthroscopy in general.³⁵

Limitations of this systematic review were largely imposed by the studies analyzed. The primary limitation was the relative paucity of clinical and radiographic data relating to hip PVNS. To our knowledge, there are no studies on the treatment of hip PVNS that have reported higher than Level IV evidence. In addition, those studies that were included often had just 1 or 2 patients satisfy our inclusion criteria. For this reason, we elected to include case reports, which further lowered the level of evidence of studies used. There were no consistently reported physical examination, survey, and radiographic findings that could be used to compare studies. All studies with sufficient data on the outcomes of hip PVNS treatment were rated poorly according to the MCMS system.²⁹ Selection bias was minimized in this review due to the inclusive nature of studies with Levels of Evidence I-V, but this created a study design bias in that most studies consisted of

Level IV evidence. Another potential concern with this paper is the fact that the arthroplasty and synovectomy groups were not identical at baseline; the arthroplasty group had significantly greater preoperative joint-space narrowing. The purpose of this review, however, was not to compare the efficacy of procedures in identical patient populations but rather to report the expected outcomes for patients who have been indicated for the respective operations.

In conclusion, while the literature on PVNS of the hip may still be limited, this review provides insight into expected outcomes. It is important that surgeons preoperatively counsel their patients on the high rate of revision no matter what surgery is performed. One out of 4 patients may ultimately need a second surgery, and, for patients who have a synovectomy without arthroplasty, that surgery may take place just 6 or 7 years after the first surgery. As it is further developed and innovated, hip arthroscopy may transform the treatment of PVNS. In turn, we encourage prospective comparative trials with higher level evidence to assess the utility of arthroscopy and other treatment modalities. ○

References and financial disclosures are available online at www.rush.edu/orthopedicsjournal.

“...the configuration we tested here is of particular interest, given its potential use in posterior-only surgery without the need for a separate anterior approach.”

Anterior Cage Reconstruction Improves Stiffness and Decreases Cancellous Subsidence in a Spondylectomy Model

MATTHEW W. COLMAN, MD / ANDREW GUSS, MS / KENT BACHUS, PHD / W. RYAN SPIKER, MD
BRANDON D. LAWRENCE, MD / EHSAN TABARAEI, MD / DARREL S. BRODKE, MD

AUTHOR AFFILIATIONS

Department of Orthopedic Surgery, Rush University Medical Center (Drs Colman and Tabaraee) and Midwest Orthopaedics at Rush (Dr Colman), Chicago, Illinois; Department of Orthopedic Surgery (Drs Guss, Bachus, Spiker, Lawrence, and Brodke), University of Utah Hospital, Salt Lake City.

CORRESPONDING AUTHOR

Matthew W. Colman, MD, Department of Orthopedic Surgery, Rush University Medical Center and Midwest Orthopaedics at Rush, 1611 W Harrison St, Suite 300, Chicago, IL 60612 (matthew.colman@rushortho.com).

INTRODUCTION

Traumatic, infectious, or oncologic processes of the anterior spine can cause instability and impair its normal functions: body support, flexibility, and protection of neural elements. For patients with such pathologies, the surgeon may choose to reconstruct the anterior spine to regain structural rigidity, correct coronal or sagittal alignment, protect neural structures, improve fusion rates, and limit posterior fusion extent. Modern options to reconstruct the anterior spine include structural allograft or autograft with static, modular, or expandable synthetic cages, with or without anterior plates or rod

systems.^{1-4,6} In most circumstances, fusion will occur even in the face of limited cage subsidence, with internal fixation becoming secondary to biologic bony support.

However, there are certain clinical scenarios where the biomechanical or biologic attributes of the local anatomy are so disrupted that biologic reconstitution will either not occur or significantly lag behind the fatiguing point of the materials. Examples include any situation where the blood supply and osseo-ligamentous anatomy are circumferentially disrupted, such as with en bloc spondylectomy for a tumor or anteroposterior (AP) surgery for extensive bony infection or trauma.⁷

Additional biologic limitations to the healing potential include poor nutritional status, chemotherapy, or external radiotherapy.^{8,9} Biomechanical disadvantages may include underlying osteopenia or the need for endplate resection to obtain wide negative margins for tumors.

When biologic healing or biomechanical stability is compromised, it becomes crucial to limit macromotion at the reconstruction site to prevent fatigue failure of the internal fixation. When the vertebral column becomes incompetent, a stable anterior column reconstruction becomes important in reducing increased flexion moments placed on the posterior tension band

complex. Significant cage subsidence and angular deformation signifies increased instability and allows progressively more flexion-extension motion. In fact, in multiple series evaluating spondylectomy reconstructions, significant cage subsidence has been noted to be as high as 50% and is attributed as the major reason for failure of posterior instrumentation.^{10,11}

A modern strategy to address this problem involves connecting the anterior column support to the posterior instrumentation. Doing so theoretically stiffens the overall construct and, in contrast to other anterior reconstructions, allows the cage to become a fixed-angle device whose endplates move in relative parallel to the cephalad and caudad pedicle screws. In this configuration, the cage is biomechanically restrained from free translation, angulation, and subsidence.

The purpose of this study was to quantify the biomechanical effects of this configuration on the stiffness and simulated subsidence in an idealized spondylectomy model. We hypothesized that connecting the anterior column reconstruction cage to the posterior rods using pedicle screws results in a stiffer construct with less subsidence of the cage.

METHODS

As a control, we constructed an idealized thoracolumbar spondylectomy model



Figure 1. The control: an idealized thoracolumbar spondylectomy model, with Delrin vertebral bodies, posterior segmental screw and rod instrumentation, Sawbones cancellous foam at superior endplate, and a free Delrin anterior cage.



Figure 2. The test state: an idealized spondylectomy model, with Delrin vertebral bodies, posterior segmental screw-and-rod instrumentation, Sawbones cancellous foam at superior endplate, and connected Delrin anterior cage.




Figure 3. A specimen from the test-state group, shown on the custom multiaxis spine simulator.

(Figure 1) using Delrin (Dupont, Wilmington, Delaware) vertebral bodies with predrilled and pretapped pedicle holes; posterior pedicle screw and titanium rod fixation (Solera; Medtronic Sofamor Danek, Memphis, Tennessee); a free Delrin anterior interbody cage predrilled and pretapped with 2 staggered pedicle holes at 90° to one another; and a 1-cm-thick, third-generation Sawbones (Vashon Island, Washington) open-cell cancellous foam at the superior endplate.

We modified the model by connecting the anterior cage to the posterior rods using additional pedicle screws and rod-screw connectors (Figure 2). We kept the cage position at the endplates precisely constant, using indelible positioning marks.

Simulated in vivo thoracolumbar mechanical stress created on a custom multiaxis spine simulator (Figure 3) using 10 cycles of flexion-extension motion, 200 N of axial preload, and a

12-Nm flexion-axial stress load. These loads are comparable to prior analogous biomechanical studies.¹²⁻¹⁵

All instrumentation and end caps were secured prior to each test. Some element of hysteresis was observed in the system as the foam endplate compressed, but all specimens had achieved a steady-state motion arc by cycle 4 or 5. We measured rigid body position in space over the motion arc using an optical motion-capture system and combined range of motion with known loads to calculate stiffness of the system. We quantified cancellous subsidence of the cage into the Sawbones' foam (Figure 4A and 4B) using a precision digital surface-mapping device accurate to within 0.2 mm (Microscribe G; Solution Technologies, Inc., Oella, Maryland). Subsidence volume was calculated using geometric integration.

A priori power analysis was based on a preliminary 3-specimen pilot test. At 80%




Figure 4. Foam indentation specimens from the control (A) and test (B) groups.

power with a significance of 0.05 and an effect size of 30%, 6 specimens per group were required. In actual testing, we used 10 foam specimens in the control state and 10 additional foam specimens in the test state.

RESULTS

The control group exhibited significantly greater foam indentation after cycling, with a mean subsidence volume of 1906 mm³ (STDEV 154 mm³, 95% CI 1810-2001 mm³) compared to the connected cage group subsidence volume of 977 mm³ (STDEV 79 mm³, 95% CI 928-1026 mm³; $P < .001$; Figure 5). Construct motion for both groups changed throughout cycling as the foam settled, but the steady-state flexion-extension arc (Figure 6) was significantly greater in the control group (8.4°, STDEV 0.3°, 95% CI 8.2-8.6°) than in the connected-cage group (6.1°, STDEV 0.1°, 95% CI 6.1-6.2°; $P < .001$, Figure 7). Correspondingly, construct stiffness was greater in the connected-cage group (3.1 N/°, STDEV 0.1 N/°, 95% CI 3.1-3.2 N/°) compared with the control group (2.3 N/°, STDEV 0.1 N/°, 95% CI 2.2-2.4 N/°; $P < .001$, Figure 7).

DISCUSSION

Failure of circumferential spinal reconstruction and fusion following extensive osseo-ligamentous resection is often due to anterior cage subsidence and cyclical macro motion.^{10,11} In this idealized spondylectomy model, we found that connecting the anterior column cage to the posterior instrumentation using additional pedicle screws resulted in a construct that is nearly 40% stiffer and exhibits 50% less cancellous subsidence compared with a traditional constructs. This allows the most rigid circumferential construct without the risks and time commitment of a more traditional anteroposterior procedure.

There were several limitations. First, this model may not be a true reflection of in vivo constructs. Confounding variables to be considered include dynamic muscular forces, imperfect preload due to cage malalignment, fatigue from long-term cyclical motion, and the varying material

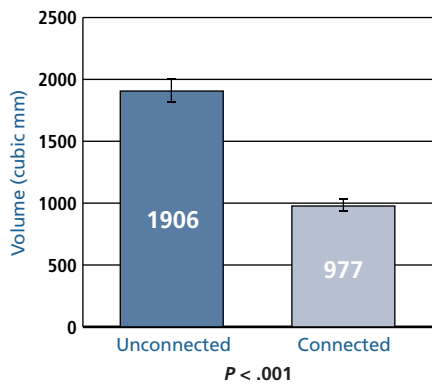


Figure 5. Mean cancellous subsidence volume for the control and test groups, with 95% confidence intervals.

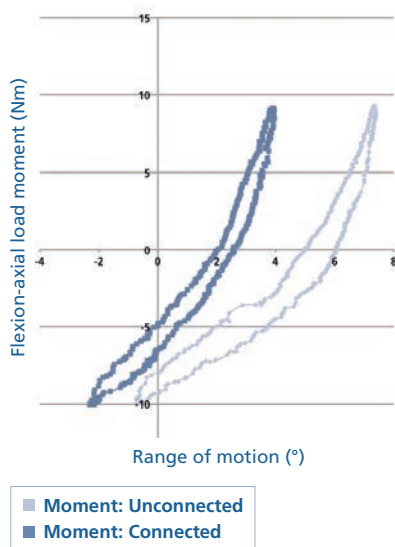


Figure 6. Stiffness curve for both the control and test groups during cycle 10, with range of motion along the flexion-extension axis (°) depicted on the x-axis, and flexion-axial load moment (Nm) in addition to the preload depicted on the y-axis.

properties of bone. However, using an idealized model, generalizability is often compromised for a more reliable and reproducible biomechanical model. The goal of this study was a proof of concept. Second, this model simplifies the reconstructive options into a connected and a completely free cage, when in fact other configurations such as Kaneda instrumentation or anterior side plates may have a similar or greater effect.¹⁶ However, the configuration we tested here is of particular interest, given its potential use in posterior-only surgery without the need for a separate anterior approach.¹⁷

Several studies have evaluated reconstruction following total en bloc spondylectomy without the described configuration. In 8 human cadaveric spines after L2 spondylectomy and Harms titanium mesh cage interbody support, Oda tested stiffness with varying combinations of Kaneda and posterior segmental instrumentation.¹⁵

Although they did not connect the posterior and anterior instrumentation, they found that only circumferential reconstructions (ie, Kaneda and posterior pedicle screws in addition to the mesh interbody cage) had a stiffness better than the intact state. In their thoracolumbar spondylectomy model using 10 human spines, Shannon et al confirmed the importance of circumferential reconstruction following spondylectomy and found that pins-and-cement plus pedicle screws configuration was stiffer than an anterior plate/rib graft plus pedicle screws without interbody cage or cement.¹⁴ Again, this study did not use a connected configuration. Lastly, Kato et al suggested that for multilevel resections, spinal shortening may impart some stability to an anterior cage-posterior pedicle screw construct.¹⁸

The specific concept of connecting the anterior cage to the posterior instrumentation is not a new one. Several available commercial products employ this technique. However, clinical evidence has been limited to small, retrospective studies.^{19,20} The concept was evaluated biomechanically in 2 related

studies using 6 human cadaver spines and a custom 6-degrees-of-freedom spine motion simulator.^{13,21} The authors found that the main determinant of stability following en bloc resection and reconstruction was length of the posterior segmental instrumentation (at least 2 segments compared with 1) and did not find any differences between other configurations such as connected vs unconnected cages, expandable vs stackable cages, and use or omission of an anterior plate. Unfortunately, confidence intervals were wide for nearly every configuration, and with 9 subgroups across only 6 specimens, our study was underpowered to accept any null hypothesis.

Although examples of the use of a connected cage can be found in the clinical and biomechanical literature, no study has ever quantified its effect on construct stiffness or vertebral cancellous subsidence. We have shown significant benefits with regard to both of these properties and suggest that further translational study be performed to confirm the clinical benefits in vivo. ○

References and financial disclosures are available online at www.rush.edu/orthopedicsjournal.

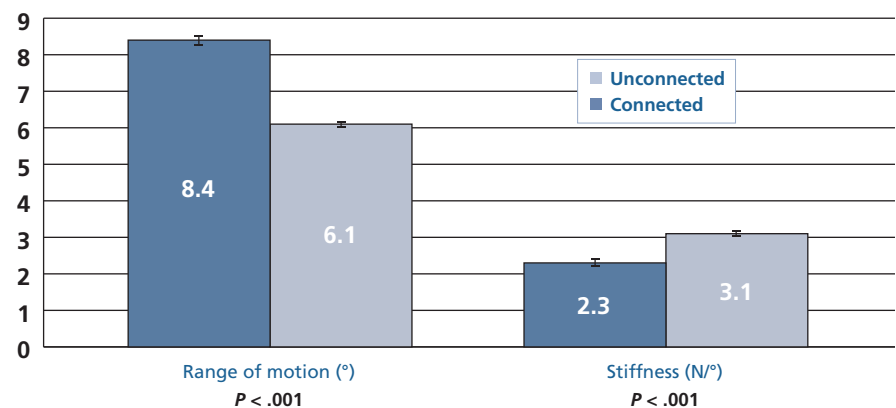


Figure 7. A graphical depiction of mean range of motion (°) and stiffness (N/°) for the control and test groups.

“The clinical relevance of determining the precise volume of intra-articular saline needed to detect a traumatic arthrotomy is crucial, because the result of this test may be the deciding factor when considering surgery.”

Detection of Traumatic Arthrotomy Using the Saline Load Test

RACHEL M. FRANK, MD / WILLIAM SLIKKER III, MD / SIMON X. LEE, MPH / JOHNNY LIN, MD / JOHN J. FERNANDEZ, MD
ROBERT W. WYSOCKI, MD / MARK S. COHEN, MD / DAVID GARRAS, MD / SIMON LEE, MD

AUTHOR AFFILIATIONS

Department of Orthopedic Surgery, Rush University Medical Center (Drs Frank, Slikker, Lin, Fernandez, Wysocki, Cohen, Garras, and Lee; and Mr Lee) and Midwest Orthopaedics at Rush (Drs Lin, Fernandez, Wysocki, Cohen, Garras, and Lee), Chicago, Illinois.

CORRESPONDING AUTHOR

Rachel M. Frank, MD, Department of Orthopedic Surgery, Rush University Medical Center, 1611 W Harrison St, Suite 300, Chicago, IL 60612 (rmfrank3@gmail.com).

INTRODUCTION

Traumatic periarticular lacerations located around the wrist and ankle joints are common, and injuries associated with such lacerations may communicate with the articular space. Periarticular lacerations may result from high-energy mechanisms such as a motor vehicle collision; open periarticular fractures from falls or other impacts; or periarticular penetration from explosions, gunshot wounds, or stab wounds. Traumatic violation of the joint capsule may result in septic arthritis, which is cytotoxic to articular cartilage.¹ While such injuries may be fairly obvious, with large wounds or clearly exposed articular surfaces, smaller wounds may be deceiving because the depth of penetration, and thus

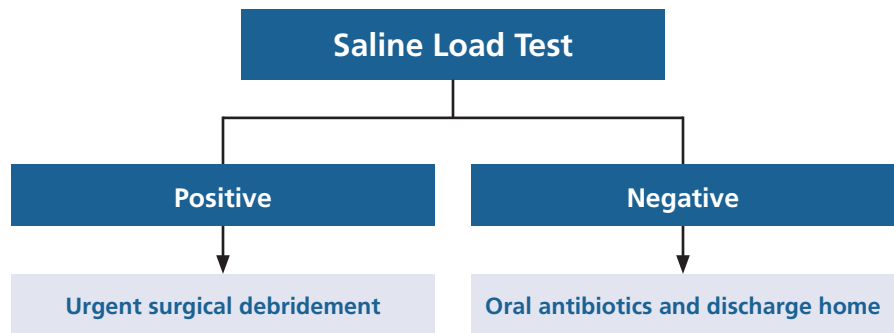


Figure 1. Algorithm for Assessment and Management of Periarticular Lacerations with the Saline Load Test.

possible communication with the articular surface, may not be readily appreciable.

Several physical examination maneuvers, including visual inspection, palpation, and range of motion testing, can be performed to help the clinician determine the extent of the injury and if there is communication with the joint. The saline load test is a diagnostic modality that involves injecting sterile saline into the joint of interest and then examining the wound or laceration for evidence of fluid leakage both at rest and with passive movement.² Visualization of fluid extravasation from the laceration site indicates a positive test. One of the main challenges of the saline load test is determining the volume of fluid needed to provide an accurate diagnosis of joint involvement. Previous studies have demonstrated the usefulness of this

test in the knee as well as in the elbow (biomechanical data only);³⁻⁷ however, to date, there is a paucity of data available for other joints, with no published studies on the wrist. The lone ankle study was published in 2013,⁸ at the time of data collection for the present study. In that study, Bariteau and colleagues performed the saline load test on 21 patients and found that, on average, 10.3 mL of fluid was needed to result in extravasation, with 30 mL needed to identify 95% of arthrotomies. Their study provides a baseline for interpreting the saline load test for periarticular injuries about the ankle but is limited by both a small sample size as well as uncertainty as to the exclusion of patients with prior ipsilateral ankle surgery. The potential inclusion of patients with prior ipsilateral ankle surgery is important to consider, because violation of the joint

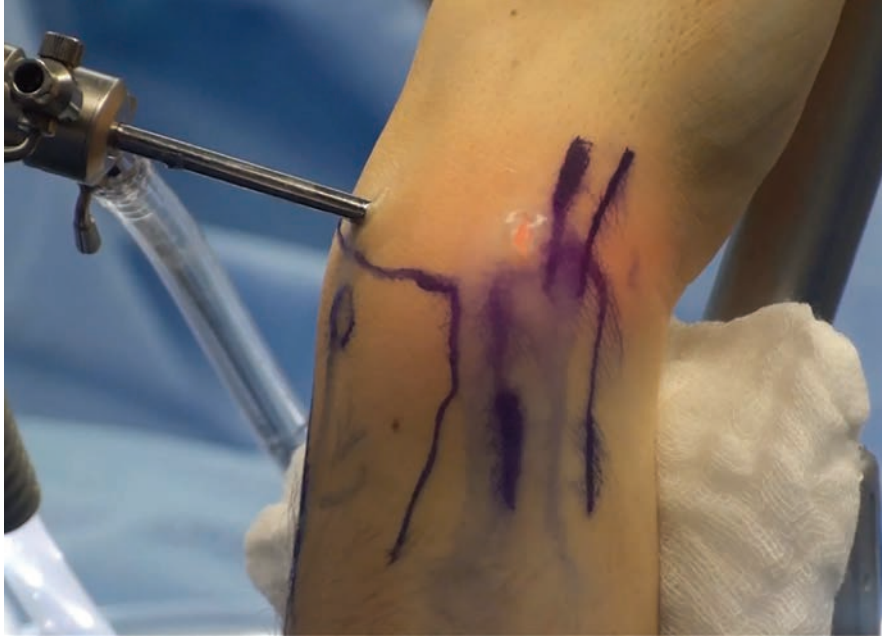

Figure 2. Intraoperative Photograph of a Patient Undergoing Right Wrist Arthroscopy.

capsule via surgical arthrotomy may alter overall joint capsular integrity, ultimately making interpretation of the simulated saline load test difficult.

The clinical relevance of determining the precise volume of intra-articular saline needed to detect a traumatic arthrotomy is crucial, because the result of this test may be the deciding factor when considering surgery (Figure 1). Voit and colleagues⁹ performed the saline load test in 50 patients with periarticular lacerations (multiple joints including knee, elbow, ankle, wrist, and fingers) and compared the results of the saline load test to pretest surgeon prediction regarding involvement of the joint. Interestingly, the authors reported a 39% false positive rate and 43% false negative rate when comparing the surgeons' predictions to the results of the saline load test, indicating the importance of obtaining objective data whenever possible. In order to interpret the results of a test such as the saline load test, however, one must have a reliable reference point with which to compare individual results. Therefore the purpose of this project was to identify the minimum fluid volume necessary to obtain 95% sensitivity for detection of periarticular injuries about the wrist and ankle. We hypothesized that

we will be able to determine a reliable saline load needed to accurately diagnosis an open joint injury in the setting of a traumatic periarticular laceration overlying the wrist and ankle.

MATERIALS AND METHODS

After obtaining approval from our university's institutional review board, we prospectively enrolled consecutive patients previously scheduled for elective outpatient wrist or ankle arthroscopy. Prior to enrollment, we discussed the protocol in detail with patients and obtained informed consent. We excluded patients with previous ipsilateral surgery on the index joint. We collected and analyzed all relevant demographic information and preoperative data, including prior injuries to the involved joint. All patients underwent surgery under regional anesthesia with sedation. Following performance of the saline load test, we performed for all patients the planned operative procedure as indicated. For all patients, we placed an uninflated tourniquet on the limb prior to performing the saline load test. We did not apply traction for either the wrist or the ankle arthroscopy until after performing the saline load test. The administration of

the saline load test added approximately 1-2 minutes to the operative case. For postoperative pain management and rehabilitation, we followed the treating surgeon's standard of care in all cases.

Wrist Protocol

In the course of routine elective wrist arthroscopy (Figure 2), a standard 3-4 portal of 5 mm was established in the usual fashion, just distal to Lister's tubercle between the third and fourth extensor compartments, between the extensor pollicus longus and extensor digitorum communis tendons. We created all portals without the application of traction and without joint insufflation. We used a #11 blade to incise the skin and penetrated the joint capsule with a hemostat. We then inserted the arthroscope without arthroscopic fluid (dry arthroscopy) and confirmed correct placement into the joint by visual inspection of the radiocarpal articulations. Under direct visual inspection, we inserted an 18-gauge needle percutaneously in the 6R portal and subsequently removed the arthroscope from the 3-4 portal following confirmation of accurate placement of the needle. We steadily injected sterile saline through the needle in the 6R portal at a rate of approximately 0.2 mL per second until there was visual confirmation of extravasation of fluid from the 3-4 arthroscopic portal site. We recorded the quantity of fluid injected, in mL, at the time of outflow. We then removed the needle, and the case proceeded as clinically indicated.

Ankle Protocol

In the course of routine elective ankle arthroscopy (Figure 3), we created a standard anterolateral ankle portal, just lateral to the lateral border of the peroneus tertius tendon at the level of the tibiotalar joint. We used a #11 blade to incise the skin and a hemostat to penetrate the joint capsule. We inserted the arthroscope without arthroscopic fluid (dry arthroscopy) and confirmed correct placement into the joint by visual inspection. Under direct visual inspection, we inserted an 18-gauge

needle percutaneously in the location of the anteromedial portal. We removed the arthroscope the anterolateral following confirmation of accurate placement of the needle. We injected sterile saline slowly and steadily through the needle at a rate of approximately 0.2 mL per second until there was visual confirmation extravasation of fluid from the anterolateral arthroscopic portal site. We recorded the quantity of fluid injected, in mL, at the time of outflow. We then removed the needle, and the case proceeded as clinically indicated.

ANALYSIS

Descriptive analysis consisted of frequencies and percentages for discrete data and means and standard deviations for continuous data. We transformed logarithmically the measured volume of saline injected into the joint space until fluid extravasation to produce normal distributions. We then used these distributions to determine the volume necessary to detect 95%, 80%, and 75% of traumatic arthrotomies.

We produced statistical analysis using SPSS (SPSS Statistics Version 21.0; IBM, Armonk, New York). All reported *P* values are 2-tailed, with an α -level of .05 detecting significant differences.

RESULTS

Wrist

We included 30 consecutive patients with an average age of 45 ± 21 years (range, 23-64 years). The indications for surgery included triangular fibrocartilage complex pathology, wrist impingement, ulnocarpal impaction, and pain refractory to nonoperative treatment. Overall, an average volume of 0.77 ± 0.70 mL of saline solution was required to achieve a positive result and induce effusion through the 3-4 arthrotomy site. The amount of fluid needed to obtain a positive result ranged from 0.2 mL to 3 mL. We did not observe any correlation between the gender, height, weight, or body mass index (BMI) of the patients and the amount of saline injected. We injected a saline load of 1.1 mL to achieve 70% sensitivity; 1.4 mL to achieve 80% sensitivity, and 1.9 mL to achieve 95% sensitivity for a positive saline load test (Figure 4).

Ankle

We included 30 consecutive patients with an average age of 38 ± 13 years (range, 19-60 years). The indications for surgery included recurrent ankle sprain,

osteochondral defect of the talus, ankle impingement, and ankle pain refractory to nonoperative treatment. Overall, an average volume of 17.6 ± 14.28 mL was required to achieve a positive result and induce effusion through the anteromedial arthrotomy site. The amount of fluid needed to obtain a positive result ranged from 2.0 mL to 30.0 mL. We observed no correlation between the gender, height, weight, or body mass index (BMI) of the patients and the amount of saline injected ($P > .05$). We injected a saline load of 25.4 mL to achieve 70% sensitivity; 30.1 mL to achieve 80% sensitivity, and 42.0 mL to achieve 95% sensitivity for a positive saline load test (Figure 5).

DISCUSSION

The principal findings of this study are as follows: (1) an average of 0.77 mL of saline was required for the saline load test to identify a simulated traumatic wrist arthrotomy while 1.9 mL of saline needs to be injected into the wrist to detect 95% of traumatic wrist arthrotomies, and (2) an average of 17.6 mL of saline was required for the saline load test to identify a simulated traumatic ankle arthrotomy, with 42.0 mL needed to detect 95% of traumatic ankle arthrotomies. These values apply to a wide array of patients of both genders and with different heights, weights, and BMIs because there was no correlation between patient demographics and the amount injected to obtain a positive result.

Joint penetration of periarticular wrist injuries can be difficult to ascertain in the emergent setting, and timely diagnosis of traumatic violation of the joint capsule can be critical to management and prevention of septic arthritis. At the same time, the risks of surgical intervention must be considered, and thus it is crucial for clinicians to determine if lacerations near a joint are isolated to the superficial soft tissues or if true communication with the joint has occurred. The saline load test is a minimally invasive procedure that can be easily performed in the triage setting. First described in 1975 by Patzakis et al,² the saline load test has

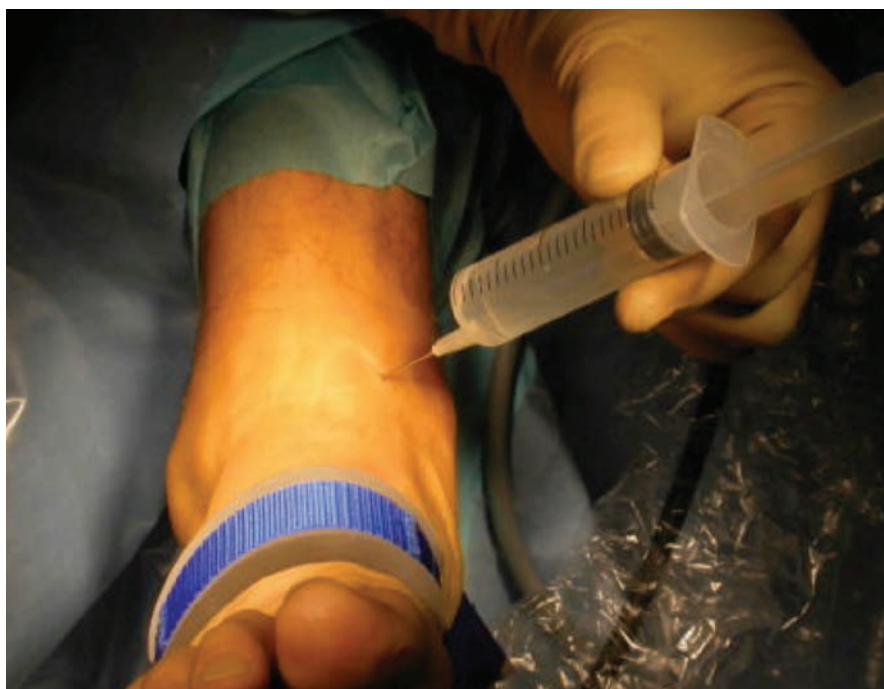

Figure 3. Intraoperative Photograph of a Patient Undergoing Right Ankle Arthroscopy.

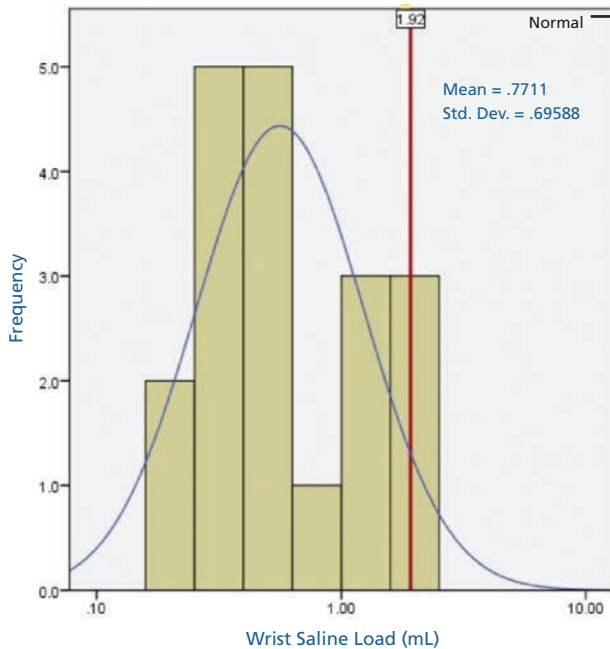


Figure 4. Wrist saline load test results: An average of 0.77 mL of saline was required for the saline load test to identify a simulated traumatic wrist arthrotomy while 1.9 mL of saline needs to be injected into the wrist to detect 95% of traumatic wrist arthrotomies.

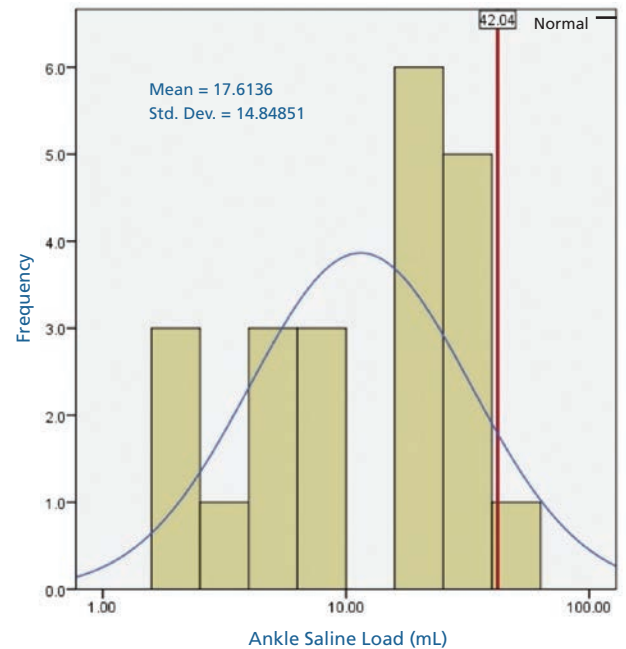


Figure 5. Ankle saline load test: An average of 17.6 mL of saline was required for the saline load test to identify a simulated traumatic ankle arthrotomy, with 42.0 mL needed to detect 95% of traumatic ankle arthrotomies.

subsequently been shown to be extremely useful in the evaluation of periarticular lacerations. For the knee, multiple studies have been performed, with somewhat varying results. Cut-off values for the knee have been reported as either 155 mL for 95% sensitivity¹⁰ and 194 mL for 95% sensitivity⁷. Interestingly, however, several other authors have recently questioned the accuracy of the saline load test with regard to the knee. Specifically, Metzger and colleagues⁶ studied the saline load test in patients undergoing elective knee arthroscopy, placing them randomly into either a normal saline group or a methylene blue group, and performed the test. Interestingly, the authors found an overall false-negative rate of 67% and noted that methylene blue dye did not help to improve the diagnostic utility of the test. For those patients that did have a positive test, the authors reported that the mean volume of fluid injected was between 95 and 105 mL. Tornetta and colleagues¹¹ also assessed the sensitivity of the saline load test in 80 knees undergoing elective knee arthroscopy. The authors loaded 60 mL into the joint and assessed for saline

leakage through an established arthroscopy portal (infrapatellar or suprapatellar). They reported 36% (22 knees) to have a positive test, with an additional 8 knees found to be positive after being put through range of motion, for an overall dynamic sensitivity of 43% (30 knees). Overall, the researchers concluded that the saline arthrogram has low sensitivity for detecting known, small traumatic arthrotomy wounds of the knee, although it should be noted that the volume of saline used in their study was 60 mL, substantially less than the 105 mL reported by Metzger et al,⁶ the 155 mL reported by Nord et al,¹⁰ and the 194 mL reported by Keese et al.⁷

Unfortunately, the data for analyzing the evaluation of traumatic arthrotomies to smaller joints, such as the wrist and ankle,⁸ are limited. Currently, there is only 1 study available to help guide decision making in the ankle, and there are no studies available for the wrist. Published during the time of data collection for our own research, the study by Bariteau and colleagues⁸ analyzed the use of the saline load test for the detection of traumatic arthrotomies of the ankle. Similar to our

study protocol and those published for the knee, the authors evaluated the saline load test in patients undergoing elective ankle arthroscopy. In their study, the authors performed the saline load test in 21 patients (11 males, 10 females) with an average age of 44 years. Their technique was similar to ours, in that they created a standard anterolateral portal as the arthrotomy and then injected saline via the anteromedial portal. Overall, the authors reported that an average of 10.3 mL was needed to diagnose the arthrotomy, with males requiring 14.5 mL and females requiring only 7.3 mL ($P = .0706$), and that 30 mL was needed to achieve 95% sensitivity. It is unknown if the authors utilized traction in their arthroscopy set-up before performing the saline load test, or further, if patients with prior ipsilateral ankle surgery were excluded. We determined that, on average, nearly 1.5 times as much fluid was necessary for a positive test when compared to the data presented by Bariteau et al, and further, we found that the amount of fluid necessary to reach 95% sensitivity was greater in our cohort: 42 mL vs 30 mL.

Our study combined with that of Bariteau et al provide a baseline to help guide clinical decision making when evaluating patients with a possible traumatic arthrotomy about the ankle. With respect to the wrist, our study is the first to quantify the volume of saline needed to accurately detect a traumatic arthrotomy of the wrist and allows clinicians to use the 1.9 mL as a cutoff volume.

Limitations

This study is not without limitations. Similar to previously published studies discussing the saline load test for traumatic arthrotomies of the knee, this study utilized an artificially created arthrotomy, which is certainly a different presentation than what may be seen in the setting of a traumatic arthrotomy. The artificial arthroscopy model likely creates an environment that requires less pressure to achieve fluid extravasation when compared to a true traumatic arthrotomy, and thus the clinical translation of such a simulated traumatic arthrotomy model may be limited. In the setting of a true traumatic arthrotomy,

given the potential degree of soft tissue disruption, there is a risk of obtaining a false positive result via overinsufflation of the joint due to loss of integrity of the joint capsule and surrounding soft tissue. Second, the patient population in this study consisted of young to middle-aged patients, and may not be generalizable to younger or older patients with varying degrees of baseline soft tissue and/or periarticular capsular laxity. Additionally, this study was performed solely in a static fashion: neither the wrist nor the ankle was taken through a range of motion during or after the injection of fluid. Repeating this study in a dynamic fashion may provide different results, as motion of the wrist and/or ankle joint may increase the detection rate through the artificially created arthrotomy. Finally, the saline load test was performed in the setting of an operating room with the patient sedated and under regional anesthesia. During clinical utilization of the saline load test, patients are typically awake and in significant pain, often unable to lie still as a needle is injected into an already injured joint. Similar to the

potential for arriving at different results when performing a static test versus a dynamic test, the differences in setting (controlled environment in the operating room versus actual traumatic periarticular laceration) may impact the technical feasibility of performing the test, ultimately resulting in different outcomes.

CONCLUSIONS

Often the decision to proceed with emergent surgical irrigation and debridement of a suspected open joint injury is based on the results of the saline load test. The results from this study will provide clinicians with the volume load needed to accurately diagnosis an open joint injury in the setting of a traumatic periarticular laceration. This information will therefore change and guide clinical/surgical decision making. ○

References and financial disclosures are available online at www.rush.edu/orthopedicsjournal.

“Our results suggest that if computed tomography has been obtained, the images should not be ignored, because a positive result makes sepsis 4.68 times more likely and a negative result, 0.5 times less likely.”

Computed Tomography for the Diagnosis of Periprosthetic Sepsis

PETER N. CHALMERS, MD / HERMAN G. BOTERO, DO / JOHN MEYER, DO
JONATHAN M. FRANK, MD / SCOTT M. SPORER, MD / BRETT R. LEVINE, MD, MS

AUTHOR AFFILIATIONS

Department of Orthopedic Surgery (Drs Chalmers, Botero, Frank, Sporer, and Levine) and Department of Radiology (Dr Meyer), Rush University Medical Center and Midwest Orthopaedics at Rush (Drs Sporer and Levine), Chicago, Illinois.

CORRESPONDING AUTHOR

Peter N. Chalmers, MD, Department of Orthopedic Surgery, Rush University Medical Center, 1611 W Harrison St, Suite 300, Chicago, IL 60612 (p.n.chalmers@gmail.com).

INTRODUCTION

Studies predict that the incidence of total hip arthroplasty (THA) revision will double by 2026, with 97 000 procedures projected annually by 2030.¹ Many patients who undergo THA will require revision. Approximately 10% of revisions are performed for periprosthetic joint infection (PJI).² Infection is a complication that is difficult to treat,³⁻⁵ and failure to diagnose PJI in a timely manner can decrease the chance of eradication. Early and accurate diagnosis is crucial, but the patient's presenting symptoms may be unclear and can be similar to those for aseptic causes of failure.^{6,7} There are valuable tests including serum erythrocyte sedimentation rate (ESR), serum C-reactive protein (CRP), synovial white blood cell (WBC) count, and synovial

differential percent of segmented leukocytes.^{6,8-13} In cases where these tests are abnormal, the current American Academy of Orthopaedic Surgery Clinical Practice Guidelines (AAOS CPG) recommends preoperative testing with ESR and CRP followed by aspiration.¹⁴

When a patient presents with a painful THA to an emergency department, primary care physician, or inpatient medical hospitalist team, medical professionals often obtain a computed tomographic (CT) scan prior to orthopedic consultation. It is difficult to know whether the results of this test are clinically useful. The current AAOS CPG does not recommend for or against the use of CT in the diagnosis of PJI.¹⁴ While many authors have investigated other types of advanced imaging in the diagnosis of PJI,¹⁵⁻²⁹ there is only a single published study that examines the sensitivity and specificity of CT scans in testing for PJI. This study measures the diagnostic value of scans interpreted by only 2 musculoskeletal radiologists.¹⁸ The diagnostic value of interpretations of CT scans in this context by orthopedic residents, adult reconstruction fellows, and fellowship-trained adult reconstruction surgeons remains unknown. This study is aimed specifically at determining the diagnostic value of CT scans for PJI when radiologists and orthopedists with varying levels of

training interpreted these scans. We hypothesized that CT scans would be neither sensitive nor specific for PJI regardless of the interpreter or level of training.

MATERIALS AND METHODS

After receiving institutional review board approval, we retrospectively reviewed the operative logs of the 2 senior authors. We reviewed the medical records of all patients who had undergone revision THA since our institution began using an electronic medical record in 2004, with a total search period of August 2004 to September 2012. We included patients who had undergone a CT scan of the hip as part of the evaluation of a painful THA within 3 months prior to revision. We excluded patients for whom the images associated with the scan could not be located.

Data Collection

We recorded data in Excel X (Microsoft, Redmond, Washington) and analyzed data in SPSS 18 (IBM, Armonk, New York). We collected the following data from the charts: patient demographics, whether the laboratory performing the test considered the values for serum CRP and ESR to be abnormal, the appearance of the preoperative radiographs as dictated by the attending surgeon in the preoperative consultation, the results of intraoperative

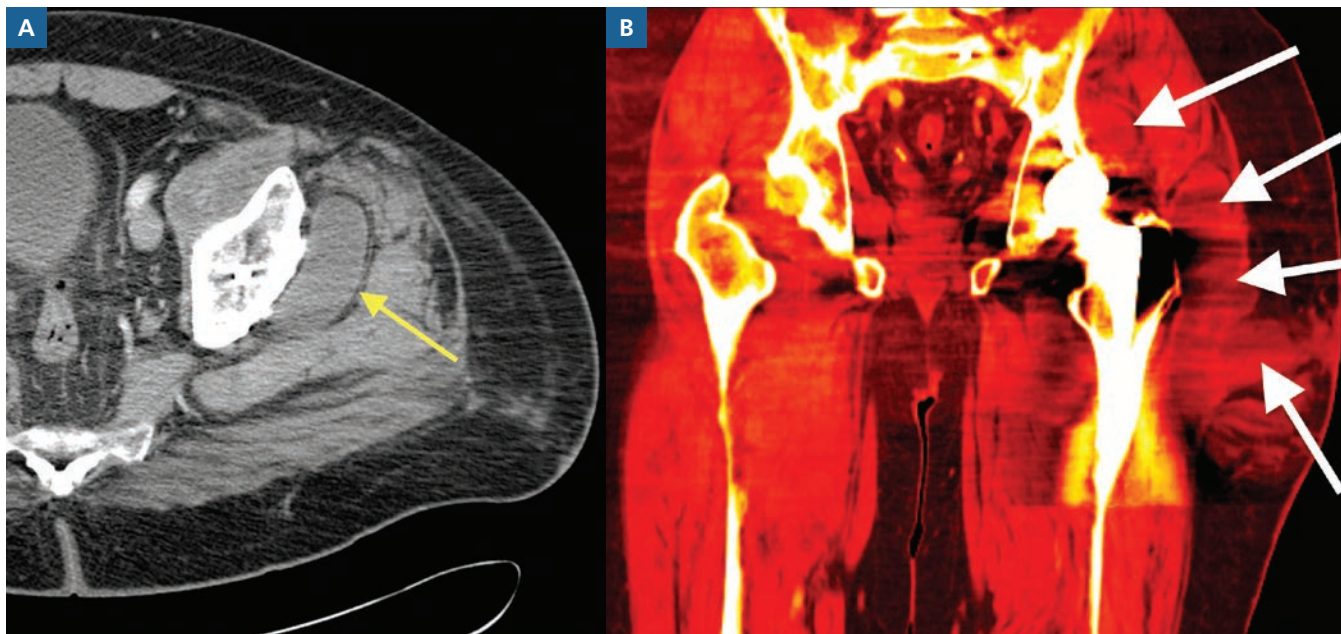


Figure 1. Fluid Collection

A, An axial slice of a computed tomographic scan of the hip in a patient with periprosthetic sepsis demonstrates a nonphysiologic fluid collection (arrow) beneath the abductor complex along the cortex of the pelvis. **B**, A coronal slice from the computed tomographic scan of the hip in a patient with periprosthetic sepsis, shown here in color enhancement, demonstrates multiple fluid collections under the abductors, beneath the fascia, and extending distally into the subcutaneous fat (arrows).

pathologic frozen section, aspirate WBC count, percent of segmented WBCs, and final culture results. For frozen section, those that had > 5 neutrophils per high-powered field on the greatest number of cellular fields were considered to be positive.^{30,31} We reviewed all preoperative consultation notes and operative reports.

We used the following criteria to determine whether PJI was the cause of failure: a sinus tract or other open communication between a wound and the involved joint; intraoperative purulence; any patient with bacterial growth from synovial aspirate cultures; or a combination of 3 of the following 4: abnormal CRP, abnormal ESR, synovial WBC count > 3000, or positive intraoperative frozen section.³² We considered the cultures negative if a single broth culture grew a common skin contaminant and all other cultures were negative.

CT Scan Review

CT reviewers included 2 senior orthopedic surgery residents, an adult reconstruction fellow, a musculoskeletal radiology fellow, a fellowship-trained musculoskeletal

radiologist, and 2 fellowship-trained adult reconstruction surgeons. We reviewed the CTs in a blinded fashion: no reviewer was aware of the diagnosis or the number of infection cases. To attempt to best replicate the clinical scenario in which scans are normally reviewed, the orthopedic resident, fellow, and attending surgeons reviewed scans within our standard electronic medical record program on standard computer screens within our clinic, while the radiology fellow and attending surgeons reviewed scans in their reading room using picture archiving and communication system (PACS) software and high-resolution screens. Both systems permit the viewer to vary light, color, intensity, magnification, etc, as desired by the viewer. This was a retrospective review and thus scans were heterogeneous as to the performing facility in slice thickness and other details of scan protocol. For each scan the reviewers produced a binary “infected”/“not infected” determination, and, in cases where they felt it was warranted, they also provided their reasoning, such as the presence or absence of a fluid collection, air within the

deep tissues, osteolysis, periosteal reaction, or heterotopic bone formation. Reviewers did not apply or utilize any a priori criteria because the purpose of the study was to replicate the clinical scenario in which scans are currently reviewed. We instructed reviewers to use their clinical judgment as to whether, based upon the findings of the CT scan alone, the patient was suffering from periprosthetic sepsis.

Data Analysis

For each reviewer, we calculated sensitivity, specificity, positive predictive value (PPV), negative predictive value (NPV), positive likelihood ratio (PLR), negative likelihood ratio (NLR), and accuracy. We performed linear regression between years since medical school graduation and accuracy. We calculated reliability using intraclass correlation coefficients quantified by Cronbach α . A priori we considered values of ≤ 0.50 to represent unacceptable, $> .50$ to ≤ 0.60 , poor; > 0.60 to ≤ 0.70 , acceptable; > 0.70 to ≤ 0.90 , good; and > 0.90 as excellent internal consistency.

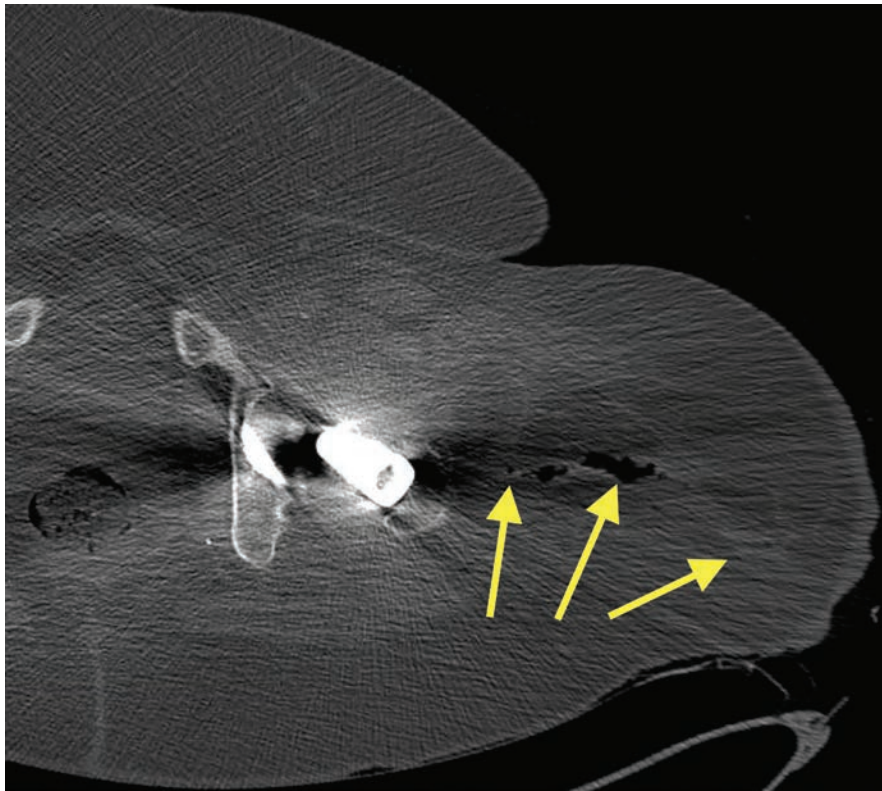


Figure 2. Subcutaneous Air
 This axial slice from a computed tomographic scan of the hip in a patient with periprosthetic sepsis demonstrates a tract of subcutaneous air consistent with a sinus tract (arrows).

RESULTS

We reviewed 309 charts and 40 potential CT scans, of which 23 scans met the inclusion criteria (7.3% of all charts). In most cases emergency department physicians and primary care doctors, rather than the treating orthopedic surgeons, provided these scans. The scans had been performed at a variety of institutions using a variety of protocols, and, in the majority of cases, no specific protocol to avoid beam-hardening artifacts was employed. Using the diagnostic criteria, we determined the following patient counts for given conditions: PJI: 4, aseptic loosening: 10, polyethylene wear: 2, metal-on-metal adverse local tissue reactions: 2, component fractures: 2, reimplantation after placement of a spacer: 2, and sarcoma: 1. Patients both with and without PJI had similar demographics (Table 1). Table 1 also shows results for ESR, CRP, aspiration characteristics, and culture results for both groups.

We reported sensitivity, specificity, PPV, NPV, PLR, NLR, and accuracy in Table 2. Cronbach α was 0.827 (0.680-0.922, 95% confidence intervals), and reliability thus qualified as “good.” Univariate regression demonstrated that years since medical school positively correlated with specificity ($P = .001$), PPV ($P = .028$), NPV ($P = .040$), and accuracy ($P = .029$) but not sensitivity ($P = .111$), PLR ($P = .096$), or NLR ($P = .358$). Mean accuracy was 74% for orthopedic residents, 80% for the musculoskeletal radiology fellow and attending surgeon, and 81% for the adult reconstruction fellow and attending surgeons. Reviewers noted a number of characteristics that they felt suggested a diagnosis of periprosthetic sepsis. The most commonly described findings to suggest infection were fluid collection (14 instances, Figure 1), air within the deep tissues (5 instances, Figure 2), osteolysis (4 instances), periosteal reaction (1 instance, Figure 3), and heterotopic bone formation (1 instance).

DISCUSSION

Nonorthopedic physicians frequently obtain CTs in the evaluation of painful THA; in our sample 13% of patients had undergone a CT within 3 months of revision. However, the utility of these studies remains largely unknown. Current AAOS CPG does not recommend for or against the use of CT in the diagnosis of PJI.¹³ The specific aim of this study is to determine the diagnostic value of CT for PJI when radiologists and orthopedists of varying levels of training interpreted these scans. We hypothesized that CT would be insensitive and nonspecific for PJI regardless of the interpreter or level of training. We found CT to have a sensitivity of 57%, a specificity of 83%, a PPV of 43%, an NPV of 91%, and an accuracy of 79%. Cronbach α was 0.827, and interrater reliability qualified as “good.” Years since medical school correlated with specificity, PPV, NPV, and accuracy but not sensitivity, PLR, or NLR. Our results suggest that if a CT has been obtained, the images should not be ignored, because a positive result makes sepsis 4.68 times more likely and a negative result, 0.5 times less likely.

As mentioned earlier, the reviewers in our series felt that the following CT characteristics suggested infection: fluid collection, air within the deep tissues, and osteolysis. Previous authors have identified osteolysis, periprosthetic soft-tissue fluid collection, periostitis/periosteal reaction, low osseous attenuation, asymmetric position of the femoral head, joint distention, fluid-filled bursae, and fluid with communicating nonbursal cavities with irregular planes as characteristic attributes of infection.^{18,23,26,29} Given that the effective joint space encompasses the entirety of the implant,³³ fluid collections can be seen at the distal aspect of the stem and within the pelvis.

Several issues remain with CT scans in diagnosing PJI. While this imaging modality is readily available in most facilities, beam-hardening artifact¹⁶ can prevent the reviewer from fully evaluating the periprosthetic tissues. New protocols have been developed to reduce artifact,

Table 1. Demographic and intraoperative characteristics of patients with periprosthetic sepsis and those with aseptic causes of failure. Unless otherwise noted, mean ± standard deviation is reported.

Variable	Patients without PJI	Patients with PJI
Number	19	4
Gender (M, F)	6, 13	2, 2
Age (yrs)	61 ± 12	64 ± 4
BMI	35 ± 9	38 ± 7
Time from primary to revision (yrs)	12 ± 11	0.4 ± 0.5
Serum CRP	6 normal, 6 abnormal, 7 not available	4 abnormal
Serum ESR	5 normal, 6 abnormal, 8 not available	4 abnormal
Frozen section (negative, positive)	16, 0	3, 0
Synovial WBC (cells/μL)	1440 ± 1827	45883 ± 42541
Synovial RBC (cells/μL)	426564 ± 330577	415000 ± 77781
Synovial segmented cells (%)	56 ± 22	85 ± 4
Synovial lymphocytic cells (%)	28 ± 5	5 ± 4
Synovial monocytic cells (%)	16 ± 17	7 ± 6
Cultures	18 negative, 1 case of CNSA in a single broth	3 negative, 1 case of MSSE

Abbreviations: BMI, body mass index; CNSA, coagulase-negative *Staphylococcus aureus*; CRP, C-reactive protein; ESR, erythrocyte sedimentation rate; F, female; M, male; MSSE, methicillin-sensitive *Staphylococcus epidermidis*; RBC, red blood cell; WBC, white blood cell.

Table 2. Sensitivity, specificity, positive predictive value (PPV), negative predictive value (NPV), positive likelihood ratio (PLR), negative likelihood ratio (NLR), and accuracy for each reviewer and in aggregate

Reviewer	Sensitivity (%)	Specificity (%)	PPV (%)	NPV (%)	PLR	NLR	Accuracy (%)
Ortho res #1	50	74	29	88	1.90	0.68	70
Ortho res #2	25	89	33	85	2.38	0.84	78
HK flw	100	79	50	100	4.75	0.00	83
MSK flw	25	89	33	85	2.38	0.84	78
MSK attg	50	89	50	89	4.75	0.56	83
Ortho attg #1	75	68	33	93	2.38	0.37	70
Ortho attg #2	75	95	75	95	14.25	0.26	91
Mean	57	83	43	91	4.68	0.51	79
95% CI high	69	87	50	93	6.47	0.63	82
95% CI low	46	79	37	88	2.89	0.38	76

Abbreviations: attg, attending; CI, confidence interval; HK, hip and knee; flw, fellow; MSK, musculoskeletal radiology; NLR, negative likelihood ratio; NPV, negative predictive value; ortho, orthopaedic; PLR, positive likelihood ratio; PPV, positive predictive value; res, resident.

which may improve the utility of CT in the diagnosis of periprosthetic pathology such as infection. In addition this modality exposes patients to radiation and imposes significant costs. Our results are not sufficiently robust to suggest that CT should be incorporated into the diagnostic algorithm for periprosthetic sepsis. However, a prospective trial in patients suspected to have periprosthetic sepsis utilizing a standardized protocol to reduce artifact could be ethically considered. Such a trial would have to weigh the expense and radiation exposure associated with CT against the diagnostic utility of a positive likelihood ratio of 4.68 and a negative likelihood ratio of 0.5. Periprosthetic sepsis is difficult to treat, and early diagnosis may improve the chance of eradicating infection, so early and accurate diagnosis is crucial, and all available diagnostic modalities should be considered. There may be value to the information obtained from CT in the diagnosis of PJI, particularly in cases where other parameters are conflicting.

Several authors have attempted to use advanced imaging to aid in the diagnosis of infection.¹⁵⁻²⁹ Much of this work has focused on nuclear medicine tests.^{17,20-24,26}

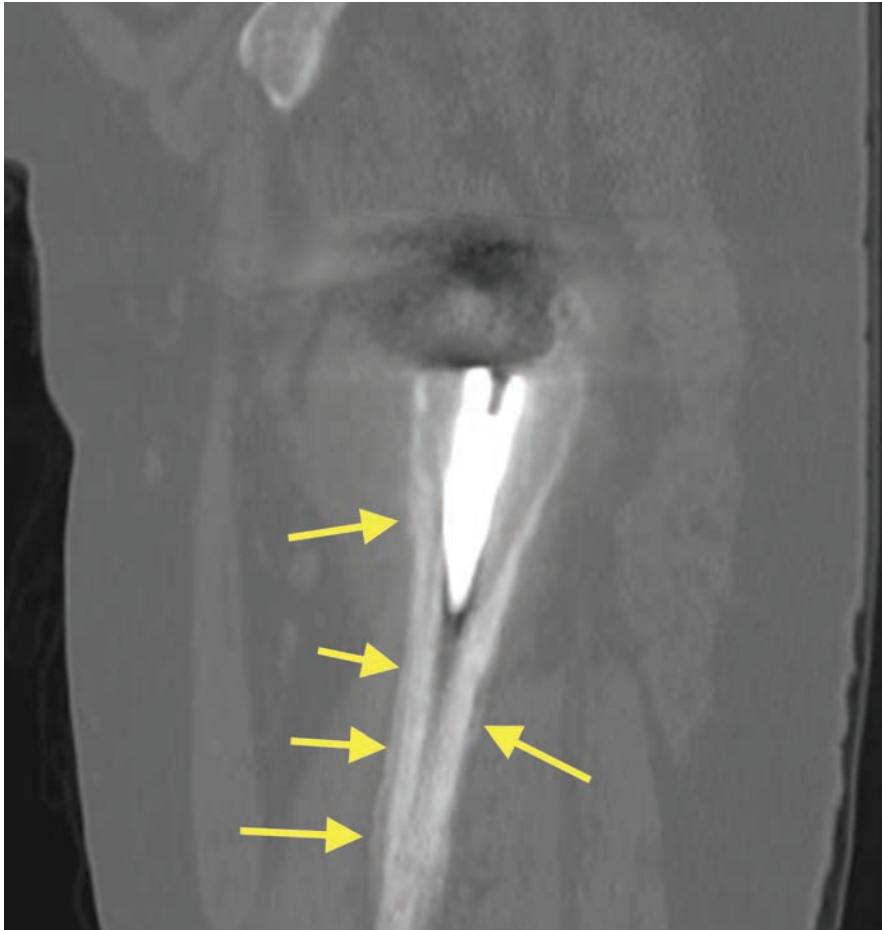


Figure 3. Periosteal Reaction
 This sagittal slice from the computed tomographic scan of the hip in a patient with periprosthetic sepsis demonstrates irregular distal femoral periosteal reaction (arrows).

Plain films have a low sensitivity and specificity for fluid collection.²⁴ Ultrasound can only characterize superficial collections.³⁴ Magnetic resonance imaging (MRI), while reproducible, is time consuming, less readily available, and may be overly sensitive.¹⁵ Only 2 published clinical studies have investigated the diagnostic value of CT for PJI.^{18,29} Cyteval et al conducted a prospective evaluation of 73 consecutive revision THAs evaluated by 2 musculoskeletal radiologists and determined that the finding of a fluid collection had a sensitivity of 41% and a specificity of 100% with a PPV of 100%, an NPV of 88%, and an accuracy of 89%. The finding of joint distention had even better diagnostic value with a sensitivity of 83%, a specificity of 96%, a PPV of 83%, an NPV of 96%, and an accuracy of 94%.¹⁸ These values exceed those of aspiration

in many clinical studies.³⁵ However, their study has several weaknesses, including that CT scans were performed on all revision THAs, not just on those suspected of infection, which likely artificially inflates the sensitivity and specificity reported. It is difficult to know whether Cyteval et al would have obtained similar results if scans were just obtained in those cases with a clinical suspicion.

Tomas et al conducted a similar prospective analysis of 63 patients.²⁹ While these authors did not explicitly report the sensitivity and specificity of CT findings, a post hoc analysis of their data reveals that the finding of a fluid collection had a sensitivity of 61%, a specificity of 83%, a PPV of 80%, an NPV of 66%, and an accuracy of 71% for PJI. Our own data more closely match the data from this latter study.

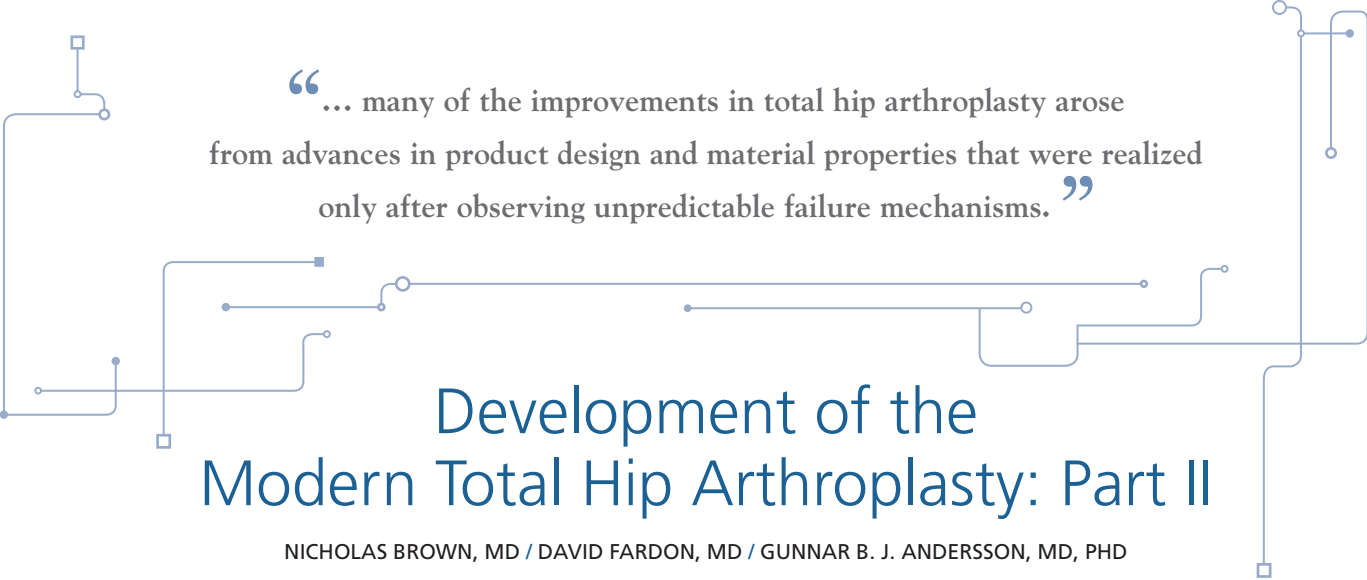
Given the evidence from these studies and from our own study, aspiration remains the gold standard for the diagnosis of periprosthetic sepsis and CT is not indicated in the evaluation of the patient with a suspected infection.

Our study has several limitations. Because it was performed retrospectively, we are limited by the information available in the medical records. In addition, our study is small in size, which limits statistical power. Our study was purposefully conducted in a similar clinical scenario to how these scans would be interpreted. While the lack of standardization in the technique in which the scans were obtained improves generalizability, it may influence validity. Ideally a larger prospective study could better address this question; however, because of the cost and radiation exposure, retrospective evidence regarding the diagnostic value of this modality is necessary before such a trial can ethically be conducted.

CONCLUSIONS

Though derived from a relatively small number of cases, our data suggest that CT in the diagnosis of periprosthetic sepsis provides a sensitivity of 57%, a specificity of 83%, a positive predictive value of 43%, a negative predictive value of 91%, and an accuracy of 79%. The interpreters' years of experience correlates with diagnostic accuracy. Interrater reliability is good. If a CT has been obtained, the images should not be ignored, because a positive result makes sepsis 4.68 times more likely and a negative result, 0.5 times less likely. ○

References and financial disclosures are available online at www.rush.edu/orthopedicsjournal.



“... many of the improvements in total hip arthroplasty arose from advances in product design and material properties that were realized only after observing unpredictable failure mechanisms.”

Development of the Modern Total Hip Arthroplasty: Part II

NICHOLAS BROWN, MD / DAVID FARDON, MD / GUNNAR B. J. ANDERSSON, MD, PHD

AUTHOR AFFILIATIONS

Department of Orthopedic Surgery, Rush University Medical Center (Drs Brown, Fardon, and Andersson) and Midwest Orthopaedics at Rush (Drs Fardon and Andersson), Chicago, Illinois.

CORRESPONDING AUTHOR

Nicholas Brown, MD, Department of Orthopedic Surgery, Rush University Medical Center, 1611 W Harrison St, Suite 300, Chicago, IL 60612 (nmb2116@gmail.com).

Editor's Note: This is the second of a 2-part article that presents the history of hip arthritis and arthroplasty from the modern era to the present, emphasizing Rush's contributions. Part 1 was published in the 2014 *Rush Orthopedics Journal*.

INTRODUCTION

Over the past 2 centuries, a vast array of treatments for hip arthritis appeared, ranging from simple resection of the proximal femur to a variety of interpositional materials. Several prosthetic devices began to resemble modern total hip implants. Unfortunately the majority of these attempts met with limited success. However, the knowledge gained from prior mistakes allowed for the development of modern total hip arthroplasty.

In the early 1960s, in England, Sir John Charnley, MD, developed the first successful total hip arthroplasty (THA). His implant consisted of a cemented, stainless-steel femoral stem and a cemented, high-density polyethylene cup. Charnley performed surgery through a large incision with removal of the greater trochanter. Patients were typically kept in the hospital for many weeks following the surgery, which was usual for the time.

Initially indications were strict, and replacement surgery was performed mainly on patients who had severe disability and pain at rest.¹ Similarly, the expected results were comparatively modest: freedom from pain and the ability to walk and function in daily activities. It is unlikely that Charnley would have foreseen a 2-sport professional athlete returning to play in both areas following arthroplasty surgery.

Charnley initially restricted sales of his device to those who had learned the procedure by training with him, and, due to these limitations, a large number of copycat device designs using different materials developed over the next several years (see Part 1).

As Charnley had proposed, surgeons fixed initial prostheses with cement. While this reasonable means of fixation is still in use, patients would sometimes present with loosening. This complication had a

variety of underlying etiologies including less-refined first-generation cementing and surgical techniques, errors in prosthesis design, and use of bearing surfaces that were more susceptible to wear.² However, many surgeons blamed the loosening on cement particles,³ resulting in the term *cement disease*. Doctors of the time did not realize that a major cause of loosening was osteolysis resulting from an inflammatory reaction to polyethylene debris.

These device failures led investigators to search for other methods of fixation. These early years of prosthesis development were the medical equivalent of the American Wild West. It was much easier then to bring a new product to market and implant it in a patient because of simpler product approval processes and less liability for the surgeon or manufacturer. Additionally, there were fewer limits on intellectual property rights. Therefore, a multitude of different products entered the market.⁴

In 1968 Jorge O. Galante, MD, DMSc, (Figure 1) former chairman of the Department of Orthopedic Surgery at Rush University Medical Center, traveled to England to meet with Charnley. Upon Galante's return to Rush, he questioned whether it would be possible to "have an implant made of porous metal so bone can grow into the implant and fix it."⁵ He posed this question to William Rostoker,



Figure 1. Jorge O. Galante, MD, DMSc, former chairman of the Department of Orthopedic Surgery at Rush, pioneered cementless hip arthroplasty.

PhD, a metallurgist at the University of Illinois, and together they developed a porous ingrowth surface utilizing titanium fiber-metal. At the time it was unclear if titanium was even a suitable prosthetic material. Some data suggested that it was biocompatible, but using this metal as an orthopedic implant was essentially uncharted territory: cemented stems primarily consisted of stainless steel or cobalt-chrome.⁶ Experiments first presented in 1970 at the American Academy of Orthopaedic Surgeons annual meeting demonstrated ingrowth of fiber-metal prostheses when implanted into the joints of monkeys and dogs. Because the work occurred during the Vietnam War era when the military was investigating bone replacement options for soldiers with severe extremity injuries, much of the development was funded by the National Institutes of Health and the Department of Defense. The *in vitro* and *in vivo* development process lasted about 10 years before the first implantation into a living patient.⁵

In the 1970s, most total hip prostheses were fixed with cement, although some devices were also developed with porous surfaces. Currently 86% of prostheses used in the United States utilize cementless fixation; however, the opposite is true in

the majority of European countries.⁷ This “Atlantic divide” is potentially due to the respective national origins of the 2 fixation techniques. Additionally, initial American results with cemented stems were unfavorable due to poor cementing techniques and frequent use of roughened stems, which, in reality, lead to increased cement mantle wear, while the Europeans continued to use tapered polished stems with more favorable results.⁸ The unfavorable outcomes with cement in the United States led to fewer American surgeons using cemented fixation and therefore fewer surgeons being taught the proper technique.

While the transition to cementless fixation in the United States was gradual, an objective look at the current percentage of cementless hips suggests that the introduction of the Harris-Galante prosthesis represented the beginning of a paradigm shift in joint replacement among American surgeons. However, as with Charnley’s early prototypes, there were unforeseen design issues. While the initial Harris-Galante cup demonstrated excellent survivorship,⁹ the stems had less successful results due to a lack of circumferential porous coating that increased the effective joint space and allowed for distal osteolysis. The polyethylene locking mechanism was another design issue because it permitted excess motion at the metal-poly interface and led to backside wear. These setbacks were addressed in updated generations of devices. However, they illustrate the point that many of the improvements in THA arose from advances in product design and material properties that were realized only after observing unpredictable failure mechanisms.

One area where this point is abundantly clear is with improvements in polyethylene quality. As noted previously, in the 1970s aseptic loosening was thought to be due to cement disease, and researchers surmised that a cementless hip could significantly reduce the incidence of aseptic loosening. This idea partially arose after histologists found polymethylmethacrylate debris in tissues with osteolysis.¹⁰ However, it soon became clear that cementless stems could

also suffer aseptic loosening. Over time researchers came to understand that these component failures were at least in part due to polyethylene debris, and the need for bearing surfaces with improved wear resistance became apparent.

One approach was to improve the quality of polyethylene used to make the bearings. While Charnley’s decision to use polyethylene (which was then used in printer looms), was a major factor that made THA possible, more sophisticated methods of sterilization have significantly improved the material’s quality. Years of research and development led to the conclusion that polyethylene is best sterilized by gamma rays in an inert environment after formation by molding. It must be packaged in such a way that it has no subsequent access to oxygen. Further, the gamma irradiation that induces cross linking leaves residual free radicals in the crystalline structure that are best removed by heating the polyethylene to a precise temperature less than its melting point, which preserves the material’s strength.¹¹ The chemistry necessary for manufacturing this thin, rudimentary-appearing plastic semicircle is remarkable, especially when put in its historical context.

In addition to better methods of processing polyethylene, new bearing surfaces were




Figure 2. Joshua J. Jacobs, MD, developed analysis of the effects of metal ion shedding in hip arthroplasty.

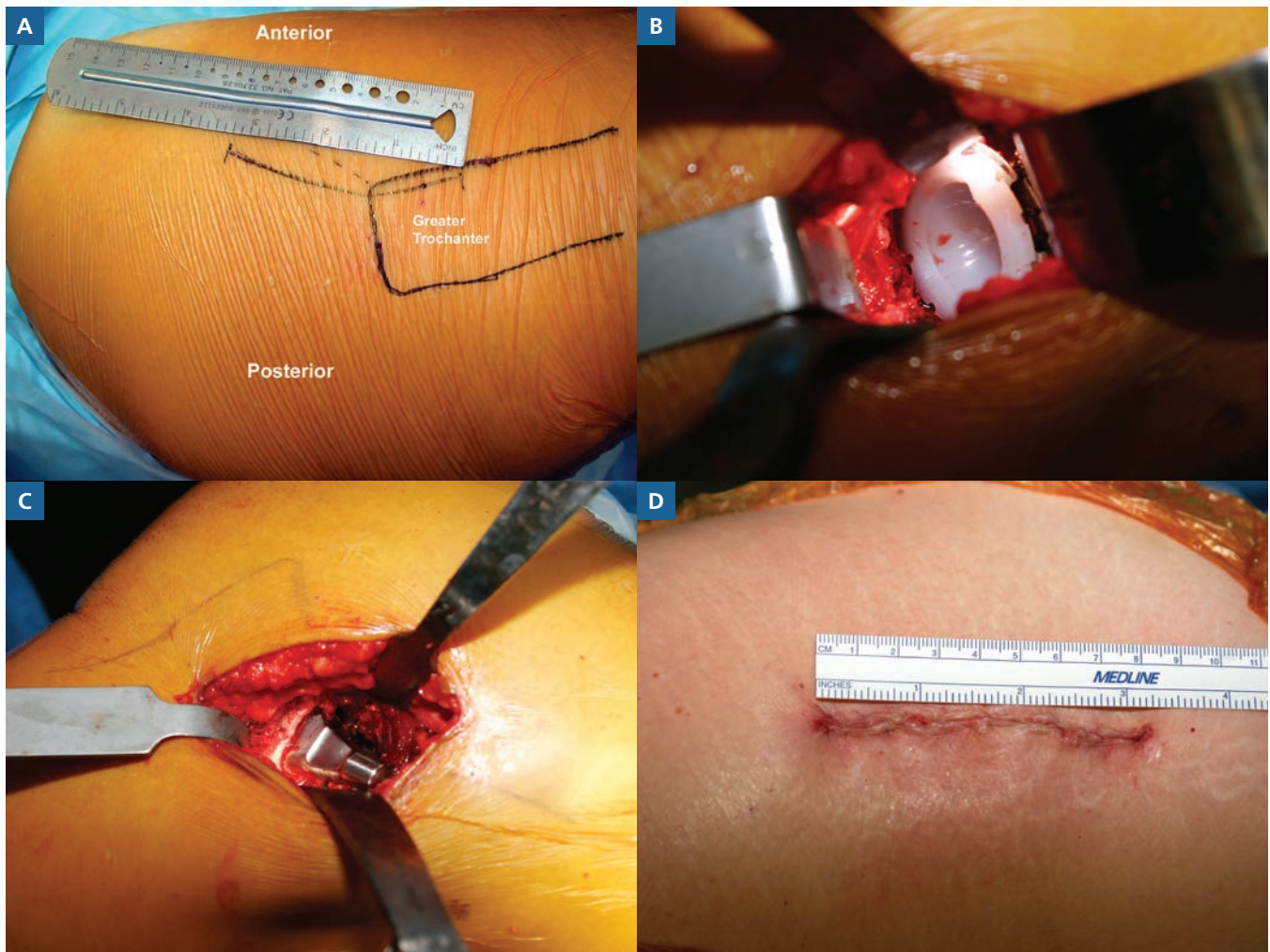


Figure 3. Intraoperative images of a minimally invasive total hip arthroplasty: **A**, Curvilinear incision bordering the Waston-Jones interval. **B**, Placement of the acetabular component and liner after reaming. **C**, Final femoral exposure. **D**, Incision closed with surgical sutures.

developed. Ceramic, with its high strength, excellent scratch resistance, and low coefficient of friction, was first utilized in 1971; however, early ceramic formulations used commercially pure alumina, a brittle material with the potential for catastrophic failure due to fracture. Concern over this complication prevented widespread use of ceramic as a bearing surface. However, the material properties of ceramic have since been improved, with zirconium replacing alumina, and the use of ceramic bearing surfaces is becoming increasingly prevalent.¹²

In the 1950s, George McKee and John Watson-Farrar had used metal-on-metal hips as some of the earliest bearing surfaces.¹³ These hips had high failure rates, and with the development of Charnley's low-friction hip, the concept

was discarded. During the 1990s, metal-on-metal bearing surfaces re-emerged as "new" technology with high strength, reduced wear, smaller particulate debris, and ability to self-polish. They provided a large femoral head size that could improve range of motion and prevent dislocations. During the re-emergence of this bearing surface, the initial results were excellent. However, consistent with many new ideas introduced into THA, there were unforeseen issues with the metal-on-metal bearing surface. Many of the pitfalls with THA have resulted from what Donald Rumsfeld eloquently noted to be "unknown unknowns."¹⁴ While many metal-on-metal hips, especially resurfacings, have excellent track records, some patients have had issues with elevated systemic metal-ion levels, adverse local tissue reactions

(ALTR), and aseptic lymphocytic vasculitis associated lesions (ALVAL). Joshua Jacobs, MD, (Figure 2), the current chairman of the Department of Orthopedic Surgery at Rush, has been on the forefront of studying the reasons behind the failures of metal-on-metal total hips. The wear particles, initially thought to be benign and nonbiologically active, in some cases incite a robust inflammatory immune response due to the formation of reactive metal-protein complexes known as haptens.¹⁵

However, proponents of metal-on-metal bearing surfaces, especially in the context of resurfacing arthroplasty, argue that a few poorly designed, subsequently recalled components have led to unfair generalization that metal-on-metal is an unsuitable bearing surface. Resurfacing,

in fact, has a rich history dating back to the initial Smith-Peterson interposition cup used in the 1930s and 1940s.¹⁶ The modern era of resurfacing seems to have begun in the 1970s with cemented cobalt-chrome stems articulating with cemented, all-polyethylene cups. Throughout the 1980s cementless fixation was used because some thought cement was a cause of failure. However, by the 1990s it was clear that polyethylene debris caused osteolysis, and surgeons were looking for a way to maintain the large head size while decreasing wear and finding a way to use a smaller acetabular component that required less bone removal. Further, the technical aspects of the procedure had been improved by using a posterior rather than transtrochanteric approach and providing suction during cementation to allow for better fixation. This confluence of factors set the stage for re-emergence of metal-on-metal as a bearing surface: it allowed for a thin, single-component acetabular shell that required less acetabular reaming and had better wear properties. The improved wear resistance and increased range of motion available with these implants in theory renders them an ideal choice for younger, more active patients. Proponents of metal-on-metal point to the excellent reported survivorships as well as the relative rarity and unclear consequences of reactions induced by metal debris and conclude that wear-related issues are due to improperly positioned components, not the intrinsic properties of the bearing surface.¹⁷


While many of the advances in the field of THA have come from advances in design and engineering, there have been improvements in technique as well. Charnley's original surgical approach placed the patient in a supine position and required an osteotomy of the greater trochanter and significant manipulation of the operative extremity to implant a prosthesis. As a result of these shortcomings, the posterior approach was developed, but this led to an increased dislocation rate. In an attempt to remedy this problem, lateral approaches were developed, but these often led to delayed recovery and limp due to abductor



Figure 4. The current joint-replacement team at Rush University Medical Center, from left to right: Scott Sporer, MD, MS, Aaron Rosenberg, MD, Wayne G. Paprosky, MD, Joshua J. Jacobs, MD, Richard A. Berger, MD, Brett Levine, MD, MS, Steven Gitelis, MD, and Craig J. Della Valle, MD. Not pictured, Tad L. Gerlinger, MD. Photo courtesy of Allen Bourgeois.

dysfunction. Surgeons would often oscillate between the 2 later approaches, depending on which complication they were better able to stomach. The direct anterior approach has recently become increasingly popular because it is a form of minimally invasive surgery. Lesser known is that the first prosthesis implanted using a version of this approach was performed in Paris by French surgeon Robert Judet, MD, in 1947 and called the Heuter approach.¹⁸ While others had experimented with decreasing incision size, the first specifically designed minimally invasive technique was through a 2-incision approach,^{19,20} developed primarily by Richard A. Berger, MD, an adult reconstructive surgeon at Rush University Medical Center, who later pioneered a minimally invasive 1-incision method, shown in Figure 3. Concomitantly with the approach, he and his team at Rush developed a more rapid postoperative rehabilitation protocol, often including discharge on the same day as the surgery—a remarkable contrast to Charnley's regimen of many weeks in the hospital after surgery. The 2-incision approach, which occasionally caused femoral nerve problems, has mostly been replaced by minimally invasive anterolateral and anterior approaches. The literature on the benefits of minimally invasive arthroplasty is inconclusive, and there are experts who are firmly on either side of the argument regarding both the smaller incision and

accelerated postoperative protocols, but it is clear that these aspects of arthroplasty are now commonplace.²¹

It is estimated that 2.5 millions Americans currently have a total hip prosthesis in place.²² Adult reconstructive surgeons at Rush (Figure 4) have performed more than 18,000 hip arthroplasties over the past three decades. Hip arthroplasty is performed routinely in dogs and cats, and an artificial hip has even been placed into an arthritic, middle-aged gorilla at the Brookfield Zoo (Brookfield, Illinois). The Associated Press reported this landmark event in its article “Arthritis-Crippled Gorilla Gets New Hips From People Doctor.”²³ While the article humorously notes that the most worrisome aspect of the surgery was the postoperative therapy, it speaks clearly to the quality of surgical techniques and confidence in prosthetic design that have developed over the past half-century. There have been setbacks along the way, but the surgery's prevalence and enormous positive impact on the lives of patients provide legitimacy to the often-quoted claim that total hip replacement is the orthopedic operation of the century.²⁴ 

References and financial disclosures are available online at www.rush.edu/orthopedicsjournal.

Select Publications 2014*

- Abey S, **Mathew MT**, Lee DJ, Knoernschild KL, **Wimmer MA**, Sukotjo C. Electrochemical behavior of titanium in artificial saliva: influence of pH. *J Oral Implantol*. 2014;40(1):3-10.
- Abrams GD, Gupta AK, Hussey KE, Tetteh ES, Karas V, **Bach BR Jr**, **Cole BJ**, **Romeo AA**, **Verma NN**. Arthroscopic repair of full-thickness rotator cuff tears with and without acromioplasty: randomized prospective trial with 2-year follow-up. *Am J Sports Med*. 2014;42(6):1296-1303.
- Abrams GD, Hussey KE, Harris JD, **Cole BJ**. Clinical results of combined meniscus and femoral osteochondral allograft transplantation: minimum 2-year follow-up. *Arthroscopy*. 2014;30(8):964-970.e1.
- Adams JE, King GJ, Steinmann SP, **Cohen MS**. Elbow arthroscopy: indications, techniques, outcomes, and complications. *J Am Acad Orthop Surg*. 2014;22(12):810-818.
- An HS**, Al-Shihabi L, Kurd M. Surgical treatment for ossification of the posterior longitudinal ligament in the cervical spine. *J Am Acad Orthop Surg*. 2014;22(7):420-429.
- Anand A, Frank RM, Haughom B, Strong B, Hellman MD, **Levine BR**. Blood management in total knee arthroplasty. *J Am Acad Orthop Surg*. 2014;22(11):681-682.
- Andersson GB**. Epidural glucocorticoid injections in patients with lumbar spinal stenosis. *N Engl J Med*. 2014;371(1):75-76.
- Anissipour AK, **Hammerberg KW**, Caudill A, Kostiuk T, Tarima S, Zhao HS, Krzak JJ, Smith PA. Behavior of scoliosis during growth in children with osteogenesis imperfecta. *J Bone Joint Surg Am*. 2014;96(3):237-243.
- Barão VA, Yoon CJ, **Mathew MT**, Yuan JC, Wu CD, Sukotjo C. Attachment of *Porphyromonas gingivalis* to corroded commercially pure titanium and titanium-aluminum-vanadium alloy. *J Periodontol*. 2014;85(9):1275-1282.
- Barrack RL, Ruh EL, Chen J, Lombardi AV Jr, Berend KR, Parvizi J, **Della Valle CJ**, Hamilton WG, Nunley RM. Impact of socioeconomic factors on outcome of total knee arthroplasty. *Clin Orthop Relat Res*. 2014;472(1):86-97.
- Bauer TW, Campbell PA, Hallerberg G, Greenfield E, **Jacobs JJ**, Mont MA, Purdue E, Schwarz EM, Smith R, Sumner D, Wooley PH. How have new bearing surfaces altered the local biological reactions to byproducts of wear and modularity? *Clin Orthop Relat Res*. 2014;472(12):3687-3698.
- Bayne CO, Stanley R, Simon P, **Espinoza-Orias A**, Salata MJ, **Bush-Joseph CA**, **Inoue N**, **Nho SJ**. Effect of capsulotomy on hip stability: a consideration during hip arthroscopy. *Am J Orthop (Belle Mead NJ)*. 2014;43(4):160-165.
- Bhatia S, Frank RM, Ghodadra NS, Hsu AR, **Romeo AA**, **Bach BR Jr**, Boileau P, Provencher MT. The outcomes and surgical techniques of the latarjet procedure. *Arthroscopy*. 2014;30(2):227-235.
- Biswas D, Van Thiel GS, Wetters NG, Pack BJ, **Berger RA**, **Della Valle CJ**. Medial unicompartmental knee arthroplasty in patients less than 55 years old: minimum of two years of follow-up. *J Arthroplasty*. 2014;29(1):101-105.
- Biswas D, **Wysocki RW**, **Fernandez JJ**, **Cohen MS**. Local and regional flaps for hand coverage. *J Hand Surg Am*. 2014;39(5):992-1004.
- Bozic KJ, Ward DT, Lau EC, Chan V, Wetters NG, Naziri Q, Odum S, Fehring TK, Mont MA, Gioe TJ, **Della Valle CJ**. Risk factors for periprosthetic joint infection following primary total hip arthroplasty: a case control study. *J Arthroplasty*. 2014;29(1):154-156.
- Brown NM, Foran JR, **Della Valle CJ**, Moric M, **Sporer SM**, **Levine BR**, **Paprosky WG**. The inter-observer and intra-observer reliability of the Paprosky femoral bone loss classification system. *J Arthroplasty*. 2014;29(7):1482-1484.
- Campbell J, Filardo G, Bruce B, Bajaj S, Friel N, Hakimiyani A, Wood S, Grumet R, Shafikhani S, Chubinskaya S, **Cole BJ**. Salvage of contaminated osteochondral allografts: the effects of chlorhexidine on human articular chondrocyte viability. *Am J Sports Med*. 2014;42(4):973-978.
- Campbell PA, Kung MS, Hsu AR, **Jacobs JJ**. Do retrieval analysis and blood metal measurements contribute to our understanding of adverse local tissue reactions? *Clin Orthop Relat Res*. 2014;472(12):3718-3727.
- Chalmers PN, Gupta AK, Rahman Z, Bruce B, **Romeo AA**, **Nicholson GP**. Predictors of early complications of total shoulder arthroplasty. *J Arthroplasty*. 2014;29(4):856-860.
- Chalmers PN, Mall NA, Moric M, Sherman SL, Paletta GP, **Cole BJ**, **Bach BR Jr**. Does ACL reconstruction alter natural history?: a systematic literature review of long-term outcomes. *J Bone Joint Surg Am*. 2014;96(4):292-300.
- Chalmers PN, **Sporer SM**, **Levine BR**. Correlation of aspiration results with periprosthetic sepsis in revision total hip arthroplasty. *J Arthroplasty*. 2014;29(2):438-442.
- Chalmers PN, Trombley R, Cip J, Monson B, **Forsythe B**, **Nicholson GP**, **Bush-Joseph CA**, **Cole BJ**, **Wimmer MA**, **Romeo AA**, **Verma NN**. Postoperative restoration of upper extremity motion and neuromuscular control during the overhand pitch: evaluation of tenodesis and repair for superior labral anterior-posterior tears. *Am J Sports Med*. 2014;42(12):2825-2836.
- Chee AV, Ren J, Lenart BA, Chen EY, **Zhang Y**, **An HS**. Cytotoxicity of local anesthetics and nonionic contrast agents on bovine intervertebral disc cells cultured in a three-dimensional culture system. *Spine J*. 2014;14(3):491-498.
- Cohen MS**, Jupiter JB. Intra-articular osteotomy for malunited articular fractures of the distal end of the humerus. *J Shoulder Elbow Surg*. 2014;23(4):579-585.
- Cole BJ**, Mellano C. Is there a role for arthroscopy in the treatment of glenohumeral arthritis? *Am J Orthop (Belle Mead NJ)*. 2014;43(2):59-60.
- Colman MW**, Kirkwood JM, Schott T, Goodman MA, McGough RL III. Does metastasectomy improve survival in skeletal melanoma? *Melanoma Res*. 2014;24(4):354-359.
- Cooper HJ, Sanders SA, **Berger RA**. Risk of symptomatic venous thromboembolism associated with flying in the early postoperative period following elective total hip and knee arthroplasty. *J Arthroplasty*. 2014;29(6):1119-1122.

*This is a partial list of published works for the faculty members of the Department of Orthopedic Surgery at Rush in 2014. Works with electronic publication dates in 2014 and print publication dates in 2015 are not included in this list. Although only faculty members are cited, the department gratefully acknowledges the co-authorship of students, nurses, practitioners, therapists, residents, fellows, and colleagues at Rush. Source: PubMed.

- Cross MB, Yi PH, Thomas CF, Garcia J, **Della Valle CJ**. Evaluation of malnutrition in orthopaedic surgery. *J Am Acad Orthop Surg*. 2014;22(3):193-199.
- Cross MB, Yi PY, Moric M, **Sporer SM, Berger RA, Della Valle CJ**. Revising an HTO or UKA to TKA: is it more like a primary TKA or a revision TKA? *J Arthroplasty*. 2014;29(suppl 9):229-231.
- Cvetanovich GL, Chalmers PN, **Yanke AB**, Gupta AK, Klosterman EL, **Verma NN, Romeo AA**. Feasibility of an osteochondral allograft for biologic glenoid resurfacing. *J Shoulder Elbow Surg*. 2014;23(4):477-484.
- Cvetanovich GL, Hsu AR, Frank RM, **An HS, Andersson GB**. Spontaneous resorption of a large cervical herniated nucleus pulposus. *Am J Orthop (Belle Mead NJ)*. 2014;43(7):E140-145.
- Cvetanovich GL, Mascarenhas R, Saccomanno MF, **Verma NN, Cole BJ, Bush-Joseph CA, Bach BR**. Hamstring autograft versus soft-tissue allograft in anterior cruciate ligament reconstruction: a systematic review and meta-analysis of randomized controlled trials. *Arthroscopy*. 2014;30(12):1616-1624.
- Dahl B, McNeely C, Robinson BS, Maloney WJ, **Paprosky WG**, Ries MD, Saleh KJ. Acetabular reconstruction in revision total hip arthroplasty: maximizing function and outcomes in protrusio and cavitary defects. *Instr Course Lect*. 2014;63:219-225.
- Dai Y, Scuderi GR, Penninger C, Bischoff JE, **Rosenberg A**. Increased shape and size offerings of femoral components improve fit during total knee arthroplasty. *Knee Surg Sports Traumatol Arthrosc*. 2014;22(12):2931-2940.
- Delemarre EM, Roord ST, van den Broek T, Zonneveld-Huijssoon E, de Jager W, Rozemuller H, Martens AC, Broere F, Wulffraat NM, **Glant TT**, Prakken BJ, van Wijk F. Brief report: Autologous stem cell transplantation restores immune tolerance in experimental arthritis by renewal and modulation of the T cell compartment. *Arthritis Rheumatol*. 2014;66(2):350-356.
- Deyo RA, Dworkin SF, Amtmann D, **Andersson G**, Borenstein D, Carragee E, Carrino J, Chou R, Cook K, DeLitto A, Goertz C, Khalsa P, Loeser J, Mackey S, Panagis J, Rainville J, Tosteson T, Turk D, Von Korff M, Weiner DK. Focus article: report of the NIH task force on research standards for chronic low back pain. *Eur Spine J*. 2014;23(10):2028-2045.
- Dhawan A, Mather RC III, Karas V, Ellman MB, Young BB, **Bach BR Jr, Cole BJ**. An epidemiologic analysis of clinical practice guidelines for non-arthroplasty treatment of osteoarthritis of the knee. *Arthroscopy*. 2014;30(1):65-71.
- Doomberg JN, Bosse T, **Cohen MS**, Jupiter JB, Ring D, Kloen P. Temporary presence of myofibroblasts in human elbow capsule after trauma. *J Bone Joint Surg Am*. 2014;96(5):e36.
- Elboghdady IM, Naqvi A, Jorgenson AY, Marquez-Lara A, **Singh K**. Minimally invasive transforaminal lumbar interbody fusion for lumbar spondylolisthesis. *Ann Transl Med*. 2014;2(10):99.
- Erickson BJ, Gupta AK, Harris JD, **Bush-Joseph C, Bach BR**, Abrams GD, San Juan AM, **Cole BJ, Romeo AA**. Rate of return to pitching and performance after Tommy John surgery in Major League Baseball pitchers. *Am J Sports Med*. 2014;42(3):536-543.
- Erickson BJ, Harris JD, Fillingham YA, Frank RM, **Bush-Joseph CA, Bach BR Jr, Cole BJ, Verma NN**. Anterior cruciate ligament reconstruction practice patterns by NFL and NCAA football team physicians. *Arthroscopy*. 2014;30(6):731-738.
- Erickson BJ, Harris JD, Heninger JR, Frank R, **Bush-Joseph CA, Verma NN, Cole BJ, Bach BR**. Performance and return-to-sport after ACL reconstruction in NFL quarterbacks. *Orthopedics*. 2014;37(8):e728-734.
- Fardon DE**, Williams AL, Dohring EJ, Murtagh FR, Gabriel Rothman SL, Sze GK. Lumbar disc nomenclature: version 2.0: recommendations of the combined task forces of the North American Spine Society, the American Society of Spine Radiology and the American Society of Neuroradiology. *Spine J*. 2014;14(11):2525-2545.
- Fardon DE**, Williams AL, Dohring EJ, Murtagh FR, Gabriel Rothman SL, Sze GK. Lumbar disc nomenclature: version 2.0: recommendations of the combined task forces of the North American Spine Society, the American Society of Spine Radiology, and the American Society of Neuroradiology. *Spine (Phila)*. 2014;39(24):E1448-1465.
- Farr J, Tabet SK, Margerrison E, **Cole BJ**. Clinical, radiographic, and histological outcomes after cartilage repair with particulated juvenile articular cartilage: a 2-year prospective study. *Am J Sports Med*. 2014;42(6):1417-1425.
- Figgie MP, Wright TM, Drinkwater D, Brown TD, D'Lima DD, Greenwald A, Phil D, Harman MK, Kurtz SM, Mihalko WM, Muratoglu OK, Rimnac CM, **Wimmer MA**. What design and material factors impact the wear and corrosion performance in total elbow arthroplasties? *Clin Orthop Relat Res*. 2014;472(12):3770-3776.
- Fillingham YA, Erickson BJ, Cvetanovich GL, **Della Valle CJ**. Dislocation of a total hip arthroplasty: acute management in the ED. *Am J Emerg Med*. 2014;32(12):1554.e1-3.
- Fillingham YA, **Kogan M**. Technique for rapid identification and removal of slipped capital femoral epiphysis screws. *Am J Orthop (Belle Mead NJ)*. 2014;43(5):238-239.
- Fillingham YA, Kroin E, Frank RM, Erickson B, Hellman M, **Kogan M**. Post-operative delay in return of function following guided growth tension plating and use of corrective physical therapy. *J Child Orthop*. 2014;8(3):265-271.
- Fineberg SJ, Nandyala SV, Kurd MF, Marquez-Lara A, Noureldin M, Sankaranarayanan S, Patel AA, Oglesby M, **Singh K**. Incidence and risk factors for postoperative ileus following anterior, posterior, and circumferential lumbar fusion. *Spine J*. 2014;14(8):1680-1685.
- Frank JM, Chahal J, Frank RM, **Cole BJ, Verma NN, Romeo AA**. The role of acromioplasty for rotator cuff problems. *Orthop Clin North Am*. 2014;45(2):219-224.
- Frank RM, Biswas D, **Levine BR**. Fracture of a dual-modular femoral component at the stem-sleeve junction in a metal-on-metal total hip arthroplasty. *Am J Orthop (Belle Mead NJ)*. 2014;43(3):E57-60.
- Frank RM, Erickson B, Frank JM, **Bush-Joseph CA, Bach BR Jr, Cole BJ, Romeo AA**, Provencher MT, **Verma NN**. Utility of modern arthroscopic simulator training models. *Arthroscopy*. 2014;30(1):121-133.
- Frank RM, Lee S, **Bush-Joseph CA**, Kelly BT, Salata MJ, **Nho SJ**. Improved outcomes after hip arthroscopic surgery in patients undergoing T-capsulotomy with complete repair versus partial repair for femoroacetabular impingement: a comparative matched-pair analysis. *Am J Sports Med*. 2014;42(11):2634-2642.
- Frank RM, Mall NA, Gupta D, Shewman E, **Wang VM, Romeo AA, Cole BJ, Bach BR Jr**, Provencher MT, **Verma NN**. Inferior suture anchor placement during arthroscopic Bankart repair: influence of portal placement and curved drill guide. *Am J Sports Med*. 2014;42(5):1182-1189.

- Frank RM, Shin J, Saccomanno MF, Bhatia S, Shewman E, **Bach BR Jr**, **Wang VM**, **Cole BJ**, Provencher MT, **Verma NN**, **Romeo AA**. Comparison of glenohumeral contact pressures and contact areas after posterior glenoid reconstruction with an iliac crest bone graft or distal tibial osteochondral allograft. *Am J Sports Med*. 2014;42(11):2574-2582.
- Frank RM, Walker G, Hellman MD, McCormick FM, **Nho SJ**. Evaluation of hip pain in young adults. *Phys Sportsmed*. 2014;42(2):38-47.
- Garbis N, Uquillas CA, Strauss EJ, **Bach BR Jr**. The arthroscopic-assisted removal of a distal femoral condylar locking plate: a case report. *Bull Hosp Jt Dis*. 2014;72(2):185-188.
- Gebhart JJ, Streit JJ, Bedi A, **Bush-Joseph CA**, **Nho SJ**, Salata MJ. Correlation of pelvic incidence with cam and pincer lesions. *Am J Sports Med*. 2014;42(11):2649-2653.
- Ghanem E, Heppert V, Spangehl M, Abraham J, Azzam K, Barnes L, Burgo FJ, Ebeid W, Goyal N, Guerra E, Hitt K, Kallel S, Klein G, Kosashvili Y, **Levine BR**, Matsen L, Morris MJ, Purtil JJ, Ranawat C, Sharkey PF, Sierra R, Stefansdottir A. Wound management. *J Orthop Res*. 2014;32(suppl 1):S108-119.
- Glant TT**, **Mikecz K**, **Rauch TA**. Epigenetics in the pathogenesis of rheumatoid arthritis. *BMC Med*. 2014;12:35.
- Gomoll AH, Gillogly SD, **Cole BJ**, Farr J, Arnold R, Hussey K, Minas T. Autologous chondrocyte implantation in the patella: a multicenter experience. *Am J Sports Med*. 2014;42(5):1074-1081.
- Gross CE, Haughom B, Chahal J, **Holmes GB Jr**. Treatments for avascular necrosis of the talus: a systematic review. *Foot Ankle Spec*. 2014;7(5):387-397.
- Gupta AK, Abrams GD, **Nho SJ**. What's new in femoroacetabular impingement surgery: will we be better in 2023? *Sports Health*. 2014;6(2):162-170.
- Gupta AK, Chalmers PN, Rahman Z, Bruce B, Harris JD, McCormick F, Abrams GD, **Nicholson GP**. Reverse total shoulder arthroplasty in patients of varying body mass index. *J Shoulder Elbow Surg*. 2014;23(1):35-42.
- Hall A, Eilers M, Hansen R, Robinson BS, Maloney WJ, **Paprosky WG**, Ries MD, Saleh KJ. Advances in acetabular reconstruction in revision total hip arthroplasty: maximizing function and outcomes after treatment of periacetabular osteolysis around the well-fixed shell. *Instr Course Lect*. 2014;63:209-218.
- Hamlekhan A, Butt A, Patel S, Royhman D, Takoudis C, Sukotjo C, Yuan J, Jursich G, **Mathew MT**, Hendrickson W, Viridi A, Shokuhfar T. Fabrication of anti-aging TiO₂ nanotubes on biomedical Ti alloys. *PLoS One*. 2014;9(5):e96213.
- Haro MS, Riff A, **Bach BR Jr**. Tips for successful transtibial anterior cruciate ligament reconstruction. *J Knee Surg*. 2014;27(5):331-342.
- Harris JD, Abrams GD, **Bach BR**, Williams D, Heidloff D, **Bush-Joseph CA**, **Verma NN**, **Forsythe B**, **Cole BJ**. Return to sport after ACL reconstruction. *Orthopedics*. 2014;37(2):e103-108.
- Haughom BD, Erickson BJ, Rybalko D, Hellman M, **Nho SJ**. Arthroscopic acetabular microfracture with the use of flexible drills: a technique guide. *Arthrosc Tech*. 2014;3(4):e459-463.
- Haughom BD, Goldstein Z, Hellman MD, Yi PH, Frank RM, **Levine BR**. An analysis of references used for the Orthopaedic In-Training Examination: what are their levels of evidence and journal impact factors? *Clin Orthop Relat Res*. 2014;472(12):4024-4032.
- Haughom BD, Schairer WW, Hellman MD, Yi PH, **Levine BR**. Does resident involvement impact post-operative complications following primary total knee arthroplasty? An analysis of 24,529 cases. *J Arthroplasty*. 2014;29(7):1468-1472.e2.
- Haughom BD, Schairer WW, Hellman MD, Yi PH, **Levine BR**. Resident involvement does not influence complication after total hip arthroplasty: an analysis of 13,109 cases. *J Arthroplasty*. 2014;29(10):1919-1924.
- Hellman MD, Riff AJ, Frank RM, Haughom BD, **Nho SJ**. Operative treatment of femoroacetabular impingement. *Phys Sportsmed*. 2014;42(3):112-119.
- Hong JT, Qasim M, **Espinoza Orías AA**, **Natarajan RN**, **An HS**. A biomechanical comparison of three different posterior fixation constructs used for c6-c7 cervical spine immobilization: a finite element study. *Neurol Med Chir (Tokyo)*. 2014;54(9):727-735.
- Hsu AR, Gross CE, **Lee S**, Carreira DS. Extended indications for foot and ankle arthroscopy. *J Am Acad Orthop Surg*. 2014;22(1):10-19.
- Hsu AR, **Lee S**. Evaluation of tarsal navicular stress fracture fixation using intraoperative o-arm computed tomography. *Foot Ankle Spec*. 2014;7(6):515-521.
- Hussain M, Nassr A, **Natarajan RN**, **An HS**, **Andersson GB**. Relationship between biomechanical changes at adjacent segments and number of fused bone grafts in multilevel cervical fusions: a finite element investigation. *J Neurosurg Spine*. 2014;20(1):22-29.
- Illingworth KD, Wachter N, Maloney WJ, **Paprosky WG**, Ries MD, Saleh KJ. Advances in acetabular osteolysis: biomarkers, imaging, and pharmacologic management. *Instr Course Lect*. 2014;63:177-186.
- Iorio R, **Della Valle CJ**, Healy WL, Berend KR, Cushner FD, Dalury DF, Lonner JH. Stratification of standardized TKA complications and adverse events: a brief communication. *Clin Orthop Relat Res*. 2014;472(1):194-205.
- Jacobs JJ**, Jevsevar DS, Brown GA, Cummins DS. AAOS Osteoarthritis Guideline: transparency and credibility. *Arthroscopy*. 2014;30(6):656-658.
- Kancherla VK, Del Gaizo DJ, **Paprosky WG**, **Sporer SM**. Utility of trephine reamers in revision hip arthroplasty. *J Arthroplasty*. 2014;29(1):210-213.
- Kido M, Ikoma K, Hara Y, Imai K, Maki M, Ikeda T, Fujiwara H, Tokunaga D, **Inoue N**, Kubo T. Effect of therapeutic insoles on the medial longitudinal arch in patients with flatfoot deformity: a three-dimensional loading computed tomography study. *Clin Biomech (Bristol, Avon)*. 2014;29(10):1095-1098.
- Kobezda T, Ghassemi-Nejad S, **Mikecz K**, **Glant TT**, Szekanecz Z. Of mice and men: how animal models advance our understanding of T-cell function in RA. *Nat Rev Rheumatol*. 2014;10(3):160-170.
- Konigsberg BS, **Della Valle CJ**, Ting NT, Qiu F, **Sporer SM**. Acute hematogenous infection following total hip and knee arthroplasty. *J Arthroplasty*. 2014;29(3):469-472.
- Kurkó J, Vida A, **Glant TT**, Scanzello CR, Katz RS, Nair A, **Mikecz K**, Szekanecz Z. Identification of myeloid-derived suppressor cells in the synovial fluid of patients with rheumatoid arthritis: a pilot study. *BMC Musculoskelet Disord*. 2014;15:281.
- Kurkó J, Vida A, Ocskó T, Tryniszewska B, **Rauch TA**, **Glant TT**, Szekanecz Z, **Mikecz K**. Suppression of proteoglycan-induced autoimmune arthritis by myeloid-derived suppressor cells generated in vitro from murine bone marrow. *PLoS One*. 2014;9(11):e111815.
- Kwon YM, Fehring TK, Lombardi AV, Barnes CL, Cabanela ME, **Jacobs JJ**. Risk stratification algorithm for management of patients with dual modular taper total hip arthroplasty: consensus statement of the American Association of Hip and Knee Surgeons, the American Academy of Orthopaedic Surgeons and the Hip Society. *J Arthroplasty*. 2014;29(11):2060-2064.

- Kwon YM, Lombardi AV, **Jacobs JJ**, Fehring TK, Lewis CG, Cabanela ME. Risk stratification algorithm for management of patients with metal-on-metal hip arthroplasty: consensus statement of the American Association of Hip and Knee Surgeons, the American Academy of Orthopaedic Surgeons, and the Hip Society. *J Bone Joint Surg Am*. 2014;96(1):e4.
- Landgraeber S, Jäger M, **Jacobs JJ**, Hallab NJ. The pathology of orthopedic implant failure is mediated by innate immune system cytokines. *Mediators Inflamm*. 2014;2014:185150.
- Lattermann C, Gomoll AH, **Cole BJ**. Arthroscopic partial meniscectomy for degenerative meniscal tear. *N Engl J Med*. 2014;370(13):1260.
- LeBeau RT, **Nho SJ**. The use of manual therapy post-hip arthroscopy when an exercise-based therapy approach has failed: a case report. *J Orthop Sports Phys Ther*. 2014;44(9):712-721.
- Lee S, Shin JJ, Haro MS, Song SH, **Nho SJ**. Evaluating the quality of Internet information for femoroacetabular impingement. *Arthroscopy*. 2014;30(10):1372-1379.
- Lenart BA, Freedman R, Van Thiel GS, Dhawan A, McGill KC, Basu S, Meyer JR, Provencher CM, **Cole BJ**, **Romeo AA**, **Verma NN**. Magnetic resonance imaging evaluation of normal glenoid length and width: an anatomic study. *Arthroscopy*. 2014;30(8):915-920.
- Leroux T, Wasserstein D, Dwyer T, Ogilvie-Harris DJ, Marks PH, **Bach BR Jr**, Townley JB, Mahomed N, Chahal J. The epidemiology of revision anterior cruciate ligament reconstruction in Ontario, Canada. *Am J Sports Med*. 2014;42(11):2666-2672.
- Levine B**, **Rosenberg AG**. The simple unicondylar knee: extramedullary technique. *Clin Sports Med*. 2014;33(1):77-85.
- Levine BR**, Haughom B, Strong B, Hellman M, Frank RM. Blood management strategies for total knee arthroplasty. *J Am Acad Orthop Surg*. 2014;22(6):361-371.
- Levine BR**, Haughom BD, Belkin MN, Goldstein ZH. Weighted versus uniform dose of tranexamic acid in patients undergoing primary, elective knee arthroplasty: a prospective randomized controlled trial. *J Arthroplasty*. 2014;29(suppl 9):186-188.
- Lombardi AV Jr, Nunley RM, Berend KR, Ruh EL, Clohisy JC, Hamilton WG, **Della Valle CJ**, Parvizi J, Barrack RL. Do patients return to work after total knee arthroplasty? *Clin Orthop Relat Res*. 2014;472(1):138-146.
- Lorio MP, Polly DW Jr, Ninkovic I, Ledonio CG, Hallas K, **Andersson G**. Utilization of minimally invasive surgical approach for sacroiliac joint fusion in surgeon population of ISASS and SMISS membership. *Open Orthop J*. 2014;8:1-6.
- Louie PK, Hassanzadeh H, **Singh K**. Epidemiologic trends in the utilization, demographics, and cost of bone morphogenetic protein in spinal fusions. *Curr Rev Musculoskelet Med*. 2014;7(3):177-181.
- Lozano-Calderon SA, **Colman MW**, Raskin KA, Hornicek FJ, Gebhardt M. Use of bisphosphonates in orthopedic surgery: pearls and pitfalls. *Orthop Clin North Am*. 2014;45(3):403-416.
- Lu Y, **Gitelis S**, Lei G, Ding M, **Maki C**, Mira RR, **Zheng Q**. Research findings working with the p53 and Rb1 targeted osteosarcoma mouse model. *Am J Cancer Res*. 2014;4(3):234-244.
- Lubowitz JH, **Verma NN**, Tokish JM, Goradia VK, McNeil JW II, Provencher MT. Risks, benefits, and evidence-based recommendations for improving anterior cruciate ligament outcomes. *Instr Course Lect*. 2014;63:369-382.
- Lundberg HJ**, Swanson A, Knowlton C, **Inoue N**, **Wimmer MA**. Methods for locating the tibio-femoral contact pathway in total knee replacements using marker-based gait analysis and standard radiography. *Iowa Orthop J*. 2014;34:94-101.
- Ma X, **An HS**, **Zhang Y**, Brown NM, Chen Z, Zhang G, Xiang H, Hu Y, Chen B. A radical procedure of circumferential spinal cord decompression through a modified posterior approach for thoracic myelopathy caused by severely impinging anterior ossification. *Spine J*. 2014;14(4):651-658.
- Mall NA, Abrams GD, Azar FM, Traina SM, Allen AA, Parker R, **Cole BJ**. Trends in primary and revision anterior cruciate ligament reconstruction among National Basketball Association team physicians. *Am J Orthop (Belle Mead NJ)*. 2014;43(6):267-271.
- Mall NA, Chalmers PN, Moric M, Tanaka MJ, **Cole BJ**, **Bach BR Jr**, Paletta GA Jr. Incidence and trends of anterior cruciate ligament reconstruction in the United States. *Am J Sports Med*. 2014;42(10):2363-2370.
- Manning BT, Sankaranarayanan S, Hassanzadeh H, Nandyala SV, Marquez-Lara A, Naqvi A, Elboghady IM, Noureldin M, **Singh K**. The utility of obtaining routine hematological laboratory values following an anterior cervical discectomy and fusion. *Spine (Phila)*. 2014;39(20):E1228-1232.
- Marquez-Lara A, Nandyala SV, Fineberg SJ, **Singh K**. Cerebral vascular accidents after lumbar spine fusion. *Spine (Phila)*. 2014;39(8):673-677.
- Marquez-Lara A, Nandyala SV, Fineberg SJ, **Singh K**. Current trends in demographics, practice, and in-hospital outcomes in cervical spine surgery: a national database analysis between 2002 and 2011. *Spine (Phila)*. 2014;39(6):476-481.
- Marquez-Lara A, Nandyala SV, Fineberg SJ, **Singh K**. Incidence, outcomes, and mortality of reintubation after anterior cervical fusion. *Spine (Phila)*. 2014;39(2):134-139.
- Marquez-Lara A, Nandyala SV, Hassanzadeh H, Noureldin M, Sankaranarayanan S, **Singh K**. Sentinel events in cervical spine surgery. *Spine (Phila)*. 2014;39(9):715-720.
- Marquez-Lara A, Nandyala SV, Sankaranarayanan S, Noureldin M, **Singh K**. Body mass index as a predictor of complications and mortality after lumbar spine surgery. *Spine (Phila)*. 2014;39(10):798-804.
- Mascarenhas R, Chalmers PN, Sayegh ET, Bhandari M, **Verma NN**, **Cole BJ**, **Romeo AA**. Is double-row rotator cuff repair clinically superior to single-row rotator cuff repair: a systematic review of overlapping meta-analyses. *Arthroscopy*. 2014;30(9):1156-1165.
- Mascarenhas R, Rusen J, Saltzman BM, Leiter J, Chahal J, **Romeo AA**, MacDonald P. Management of humeral and glenoid bone loss in recurrent glenohumeral instability. *Adv Orthop*. 2014;2014:640952.
- Mascarenhas R, Simon D, **Forsythe B**, Harner CD. ACL reconstruction in a teenage athlete with fibular hemimelia. *Knee*. 2014;21(2):613-616.
- Mascarenhas R, **Yanke AB**, Frank RM, Butty DC, **Cole BJ**. Meniscal allograft transplantation: preoperative assessment, surgical considerations, and clinical outcomes. *J Knee Surg*. 2014;27(6):443-458.
- McCarrel TM, Mall NA, Lee AS, **Cole BJ**, Butty DC, Fortier LA. Considerations for the use of platelet-rich plasma in orthopedics. *Sports Med*. 2014;44(8):1025-1036.
- McCormick F, Bhatia S, Chalmers P, Gupta A, **Verma N**, **Romeo AA**. The management of type II superior labral anterior to posterior injuries. *Orthop Clin North Am*. 2014;45(1):121-128.

- McCormick F, Gupta A, Bruce B, Harris J, Abrams G, Wilson H, Hussey K, **Cole BJ**. Single-row, double-row, and transosseous equivalent techniques for isolated supraspinatus tendon tears with minimal atrophy: a retrospective comparative outcome and radiographic analysis at minimum 2-year followup. *Int J Shoulder Surg*. 2014;8(1):15-20.
- McCormick F, Harris JD, Abrams GD, Hussey KE, Wilson H, Frank R, Gupta AK, **Bach BR Jr, Cole BJ**. Survival and reoperation rates after meniscal allograft transplantation: analysis of failures for 172 consecutive transplants at a minimum 2-year follow-up. *Am J Sports Med*. 2014;42(4):892-897.
- McCormick F, Slikker W III, Harris JD, Gupta AK, Abrams GD, Frank J, **Bach BR Jr, Nho SJ**. Evidence of capsular defect following hip arthroscopy. *Knee Surg Sports Traumatol Arthrosc*. 2014;22(4):902-905.
- Meermans G, Perez J, Ploegmakers JJ, **Rosenberg A**, C Simpfendorfer, Thomas P, Tohtz S, Villafuerte JA, Wahl P, Wagenaar FC, Witzo E. Diagnosis of periprosthetic joint infection. *J Orthop Res*. 2014;32(suppl 1):S98-107.
- Mihalko WM, **Wimmer MA**, Pacione CA, **Laurent MP**, Murphy RF, Rider C. How have alternative bearings and modularity affected revision rates in total hip arthroplasty? *Clin Orthop Relat Res*. 2014;472(12):3747-3758.
- Moran CJ, Pascual-Garrido C, Chubinskaya S, Potter HG, Warren RF, **Cole BJ**, Rodeo SA. Restoration of articular cartilage. *J Bone Joint Surg Am*. 2014;96(4):336-344.
- Nandyala SV, Elboghdady IM, Marquez-Lara A, Noureldin MN, Sankaranarayanan S, **Singh K**. Cost analysis of incidental durotomy in spine surgery. *Spine (Phila)*. 2014;39(17):E1042-1051.
- Nandyala SV, Fineberg SJ, Pelton M, **Singh K**. Minimally invasive transforaminal lumbar interbody fusion: one surgeon's learning curve. *Spine J*. 2014;14(8):1460-1465.
- Nandyala SV, Marquez-Lara A, Fineberg SJ, Hassanzadeh H, **Singh K**. Complications after lumbar spine surgery between teaching and nonteaching hospitals. *Spine (Phila)*. 2014;39(5):417-423.
- Nandyala SV, Marquez-Lara A, Fineberg SJ, Pelton M, **Singh K**. Prospective, randomized, controlled trial of silicate-substituted calcium phosphate versus rhBMP-2 in a minimally invasive transforaminal lumbar interbody fusion. *Spine (Phila)*. 2014;39(3):185-191.
- Nandyala SV, Marquez-Lara A, Fineberg SJ, **Singh K**. Comparison between cervical total disc replacement and anterior cervical discectomy and fusion of 1 to 2 levels from 2002 to 2009. *Spine (Phila)*. 2014;39(1):53-57.
- Nandyala SV, Marquez-Lara A, Fineberg SJ, **Singh K**. Comparison of revision surgeries for one- to two-level cervical TDR and ACDF from 2002 to 2011. *Spine J*. 2014;14(12):2841-2846.
- Nandyala SV, Marquez-Lara A, Fineberg SJ, **Singh K**. Perioperative characteristics and outcomes of patients undergoing anterior cervical fusion in July: analysis of the "July effect." *Spine (Phila)*. 2014;39(7):612-617.
- Nandyala SV, Marquez-Lara A, Fineberg SJ, Singh R, **Singh K**. Incidence and risk factors for perioperative visual loss after spinal fusion. *Spine J*. 2014;14(9):1866-1872.
- Nandyala SV, Marquez-Lara A, Park DK, Hassanzadeh H, Sankaranarayanan S, Noureldin M, **Singh K**. Incidence, risk factors, and outcomes of postoperative airway management after cervical spine surgery. *Spine (Phila)*. 2014;39(9):E557-563.
- Nicholson GP**. CORR Insights®: assessing shoulder motion in children: age limitations to Mallet and ABC Loops. *Clin Orthop Relat Res*. 2014;472(2):749.
- Novak CC, Hsu AR, **Della Valle CJ, Skipor AK**, Campbell P, Amstutz HC, Jiranek WA, Onyike A, Pombar XF, **Jacobs JJ**. Metal ion levels in maternal and placental blood after metal-on-metal total hip arthroplasty. *Am J Orthop (Belle Mead NJ)*. 2014;43(12):E304-308.
- O'Keefe JA, **Espinoza Orías AA**, Khan H, **Hall DA**, Berry-Kravis E, **Wimmer MA**. Implementation of a markerless motion analysis method to quantify hyperkinesia in males with fragile X syndrome. *Gait Posture*. 2014;39(2):827-830.
- Panigrahi P, Liao Y, **Mathew MT, Fischer A, Wimmer MA, Jacobs JJ**, Marks LD. Intergranular pitting corrosion of CoCrMo biomedical implant alloy. *J Biomed Mater Res B Appl Biomater*. 2014;102(4):850-859.
- Parvizi J, Erkokoc OF, **Della Valle CJ**. Culture-negative periprosthetic joint infection. *J Bone Joint Surg Am*. 2014;96(5):430-436.
- Parvizi J, Nunley RM, Berend KR, Lombardi AV Jr, Ruh EL, Clohisy JC, Hamilton WG, **Della Valle CJ**, Barrack RL. High level of residual symptoms in young patients after total knee arthroplasty. *Clin Orthop Relat Res*. 2014;472(1):133-137.
- Plummer DR, Haughom BD, **Della Valle CJ**. Dual mobility in total hip arthroplasty. *Orthop Clin North Am*. 2014;45(1):1-8.
- Pope D, Blankenship S, Jones G, Robinson BS, Maloney WJ, **Paprosky WG**, Ries MD, Saleh KJ. Maximizing function and outcomes in acetabular reconstruction: segmental bony defects and pelvic discontinuity. *Instr Course Lect*. 2014;63:187-197.
- Porter DA, **Urban RM, Jacobs JJ**, Gilbert JL, Rodriguez JA, Cooper HJ. Modern trunnions are more flexible: a mechanical analysis of THA taper designs. *Clin Orthop Relat Res*. 2014;472(12):3963-3970.
- Porter DA, **Urban RM, Jacobs JJ**, Gilbert JL, Rodriguez JA, Cooper HJ. Modern trunnions are more flexible: a mechanical analysis of THA taper designs. *Clin Orthop Relat Res*. 2014;472(12):3963-3970.
- Provencher MT, Frank RM, Scuderi MG, Solomon DJ, Ghodadra NS, **Bach BR**, McCarty E, **Romeo AA**. General and disease-specific use of outcomes scores for the shoulder: a survey of AOSSM, AANA, and ISAKOS members. *Phys Sportsmed*. 2014;42(3):120-130.
- Qasim M, **Natarajan RN, An HS, Andersson GB**. Damage accumulation location under cyclic loading in the lumbar disc shifts from inner annulus lamellae to peripheral annulus with increasing disc degeneration. *J Biomech*. 2014;47(1):24-31.
- Reddy A, Caicedo MS, Samelko L, **Jacobs JJ, Hallab NJ**. Implant debris particle size affects serum protein adsorption which may contribute to particle size-based bioreactivity differences. *J Long Term Eff Med Implants*. 2014;24(1):77-88.
- Riff AJ, Sah AP, **Della Valle CJ**. Outcomes and complications of unicondylar arthroplasty. *Clin Sports Med*. 2014;33(1):149-160.
- Rosenthal BD, Hulst JB, Moric M, **Levine BR, Sporer SM**. The effect of payer type on clinical outcomes in total knee arthroplasty. *J Arthroplasty*. 2014;29(2):295-298.
- Royhman D, Radhakrishnan R, Yuan JC, **Mathew MT**, Mercuri LG, Sukotjo C. An electrochemical investigation of TMJ implant metal alloys in an artificial joint fluid environment: the influence of pH variation. *J Craniomaxillofac Surg*. 2014;42(7):1052-1061.
- Ruel N, Markova DZ, Adams SL, Scanzello C, Cs-Szabo G, Gerard D, Shi P, Anderson DG, Zack M, **An HS**, Chen D, **Zhang Y**. Fibronectin fragments and the cleaving enzyme ADAM-8 in the degenerative human intervertebral disc. *Spine (Phila)*. 2014;39(16):1274-1279.

- Saccomanno MF, Shin JJ, Mascarenhas R, Haro M, **Verma NN, Cole BJ, Bach BR Jr.** Clinical and functional outcomes after anterior cruciate ligament reconstruction using cortical button fixation versus transfemoral suspensory fixation: a systematic review of randomized controlled trials. *Arthroscopy*. 2014;30(11):1491-1498.
- Salata MJ, Bailey JR, Bell R, Frank RM, McGill KC, Lin EC, Kercher JS, **Wang VM, Provencher MT, Mazzocca AD, Verma NN, Romeo AA.** Effect of interference screw depth on fixation strength in biceps tenodesis. *Arthroscopy*. 2014;30(1):11-15.
- Saltzman BM, Chalmers PN, Gupta AK, **Romeo AA, Nicholson GP.** Complication rates comparing primary with revision reverse total shoulder arthroplasty. *J Shoulder Elbow Surg*. 2014;23(11):1647-1654.
- Saltzman BM, Chalmers PN, Mascarenhas R, **Cole BJ, Romeo AA.** Upper extremity physeal injury in young baseball pitchers. *Phys Sportsmed*. 2014;42(3):100-111.
- Saltzman BM, Haughom B, Oni JK, **Levine BR.** Chronic infection leading to failure of a composite femoral stem: a report of two cases. *HSS J*. 2014;10(2):180-185.
- Sayegh ET, Mascarenhas R, Chalmers PN, **Cole BJ, Verma NN, Romeo AA.** Allograft reconstruction for glenoid bone loss in glenohumeral instability: a systematic review. *Arthroscopy*. 2014;30(12):1642-1649.
- Senoo I, **Espinoza Orías AA, An HS, Andersson GB, Park DK, Triano JJ, Inoue N.** In vivo 3-dimensional morphometric analysis of the lumbar foramen in healthy subjects. *Spine (Phila)*. 2014;39(16):E929-935.
- Sershon RA, Van Thiel GS, Lin EC, McGill KC, **Cole BJ, Verma NN, Romeo AA, Nicholson GP.** Clinical outcomes of reverse total shoulder arthroplasty in patients aged younger than 60 years. *J Shoulder Elbow Surg*. 2014;23(3):395-400.
- Shin JJ, Mellano C, Cvetanovich GL, Frank RM, **Cole BJ.** Treatment of glenoid chondral defect using micronized allogeneic cartilage matrix implantation. *Arthrosc Tech*. 2014;3(4):e519-522.
- Siemionow K, Sundberg E, Tyrakowski M, Nandyala SV, **Singh K.** Point-counter-point debate: the association between recombinant human bone morphogenetic protein utilization and complications in spine surgery. *Curr Rev Musculoskelet Med*. 2014;7(3):200-207.
- Silverton CD, **Jacobs JJ, Devitt JW, Cooper HJ.** Midterm results of a femoral stem with a modular neck design: clinical outcomes and metal ion analysis. *J Arthroplasty*. 2014;29(9):1768-1773.
- Singh K, Ahmadinia K, Park DK, Nandyala SV, Marquez-Lara A, Patel AA, Fineberg SJ.** Complications of spinal fusion with utilization of bone morphogenetic protein: a systematic review of the literature. *Spine (Phila)*. 2014;39(1):91-101.
- Singh K, Nandyala SV, Marquez-Lara A, Fineberg SJ, Oglesby M, Pelton MA, Andersson GB, Isayeva D, Jegier BJ, Phillips FM.** A perioperative cost analysis comparing single-level minimally invasive and open transforaminal lumbar interbody fusion. *Spine J*. 2014;14(8):1694-1701.
- Singh K, Nandyala SV, Marquez-Lara A, Fineberg SJ.** Epidemiological trends in the utilization of bone morphogenetic protein in spinal fusions from 2002 to 2011. *Spine (Phila)*. 2014;39(6):491-496.
- Strauss EJ, Salata MJ, Sershon RA, Garbis N, Provencher MT, **Wang VM, McGill KC, Bush-Joseph CA, Nicholson GP, Cole BJ, Romeo AA, Verma NN.** Role of the superior labrum after biceps tenodesis in glenohumeral stability. *J Shoulder Elbow Surg*. 2014;23(4):485-491.
- Strauss EJ, **Verma NN, Salata MJ, McGill KC, Klifto C, Nicholson GP, Cole BJ, Romeo AA.** The high failure rate of biologic resurfacing of the glenoid in young patients with glenohumeral arthritis. *J Shoulder Elbow Surg*. 2014;23(3):409-419.
- Sundman EA, **Cole BJ, Karas V, Della Valle C, Tetreault MW, Mohammed HO, Fortier LA.** The anti-inflammatory and matrix restorative mechanisms of platelet-rich plasma in osteoarthritis. *Am J Sports Med*. 2014;42(1):35-41.
- Tannoury CA, **An HS.** Complications with the use of bone morphogenetic protein 2 (BMP-2) in spine surgery. *Spine J*. 2014;14(3):552-559.
- Tetreault MW, Shukla SK, Yi PH, **Sporer SM, Della Valle CJ.** Are short fully coated stems adequate for "simple" femoral revisions? *Clin Orthop Relat Res*. 2014;472(2):577-583.
- Tetreault MW, Wetters NG, Aggarwal V, Mont M, Parvizi J, **Della Valle CJ.** The Chitranjan Ranawat Award: Should prophylactic antibiotics be withheld before revision surgery to obtain appropriate cultures? *Clin Orthop Relat Res*. 2014;472(1):52-56.
- Tetreault MW, Wetters NG, Moric M, Gross CE, **Della Valle CJ.** Is synovial C-reactive protein a useful marker for periprosthetic joint infection? *Clin Orthop Relat Res*. 2014;472(12):3997-4003.
- Vasarhelyi EM, MacDonald SJ, **Della Valle CJ, Vail TP.** Let's do a revision total knee arthroplasty. *Instr Course Lect*. 2014;63:239-251.
- Yamaguchi T, **Inoue N, Sah RL, Lee YP, Taborek AP, Williams GM, Moseley TA, Bae WC, Masuda K.** Micro-computed tomography-based three-dimensional kinematic analysis during lateral bending for spinal fusion assessment in a rat posterolateral lumbar fusion model. *Tissue Eng Part C Methods*. 2014;20(7):578-587.
- Yanke AB, Chalmers PN, Frank RM, Friel NA, Karas V, Cole BJ.** Clinical outcome of revision meniscal allograft transplantation: minimum 2-year follow-up. *Arthroscopy*. 2014;30(12):1602-1608.
- Yanke AB, Cole BJ.** Microfracture: dead or the future? *Orthopedics*. 2014;37(12):798-800.
- Yanke AB, Wuerz T, Saltzman BM, Butty D, Cole BJ.** Management of patellofemoral chondral injuries. *Clin Sports Med*. 2014;33(3):477-500.
- Yi PH, Cross MB, Moric M, **Sporer SM, Berger RA, Della Valle CJ.** The 2013 Frank Stinchfield Award: Diagnosis of infection in the early postoperative period after total hip arthroplasty. *Clin Orthop Relat Res*. 2014;472(2):424-429.
- Zhang Y, Lenart BA, Lee JK, Chen D, Shi P, Ren J, Muehleman C, Chen D, An HS.** Histological features of endplates of the mammalian spine: from mice to men. *Spine (Phila)*. 2014;39(5):E312-317.
- Zmistowski B, **Della Valle C, Bauer TW, Malizos KN, Alavi A, Bedair H, Booth RE, Choong P, Deirmengian C, Ehrlich GD, Gambir A, Huang R, Kissin Y, Kobayashi H, Kobayashi N, Krenn V, Lorenzo D, Marston SB, Meermans G, Perez J, Ploegmakers JJ, Rosenberg A, Simpendorfer C, Thomas P, Tohtz S, Villafuerte JA, Wahl P, Wagenaar FC, Witzo E.** Diagnosis of periprosthetic joint infection. *J Arthroplasty*. 2014;29(Suppl 2):77-83. ○

Six Degrees of Collaboration

A roundtable discussion about the role of translational research in medicine, and the collaboration between physician-researchers and basic scientists at Rush



TALKING HEADS. Clockwise from left: Brian J. Cole, MD, MBA, director, Rush Cartilage Restoration Center; Nozomu Inoue, MD, PhD, professor and scientist, Spine Research Laboratory; Howard S. An, MD, director, Division of Spine Surgery; Susan Chubinskaya, PhD, CIBA-Geigy Chair of Biochemistry; and Markus A. Wimmer, PhD, associate chairman for research, Department of Orthopedic Surgery (not pictured, Craig J. Della Valle, MD, director, Section of Research, Division of Adult Reconstructive Surgery).



What do a spine surgeon, a sports medicine surgeon, a joint-replacement surgeon, and scientists in spine biomechanics, motion analysis, tribology, and biochemistry all have in common?

Despite having different areas of expertise, training, and backgrounds, Howard S. An, MD, Brian J. Cole, MD, MBA, Craig J. Della Valle, MD, Nozomu Inoue, MD, PhD, Markus A. Wimmer, PhD, and Susan Chubinskaya, PhD, are actually a lot alike.

As the *Rush Orthopedics Journal's* first ever roundtable discussion gets under way, it quickly becomes clear that one of the most significant things they share is a commitment to advancing orthopedic care, and that their mutual passion for research has led to a number of fruitful collaborations over the years.

Chubinskaya and Wimmer are both part of the Rush Cartilage Restoration Center, led by Cole, where they partner on cutting-edge cartilage research. As head of both the motion analysis and tribology labs, Wimmer has also worked with Della Valle on joint implant studies, and his labs are involved in spine kinematics studies.

Speaking of the spine, An and Inoue are co-investigators on numerous studies related to intervertebral disc degeneration and biologic regeneration, which they hope will ultimately lead to more effective nonsurgical treatments for this prevalent problem.

These connections, just a few among many in orthopedics at Rush, have produced some eye-opening, award-winning publications. It's not the recognition, however, that drives translational research and makes it so rewarding for the 6 roundtable participants.

As they explain, it's the relationships, the challenges, the thrill of discovery, and—most important—the ability to quite literally transform patients' lives.

AN: Perhaps the logical place to begin is by explaining the process of translational research. Dr Inoue, maybe you can explain the steps involved, and the roles physicians and researchers each play at the various stages?

INOUE: There are several steps needed for any project: development of a new concept, proof of the concept, feasibility and efficacy studies, and safety studies. Although clinicians could be involved in all of the

steps, development of a new concept, proof of the concept, and the feasibility study are primarily performed by basic researchers.

The efficacy study—which determines dose effects and application, for example—definitely needs clinical input. Because the size and geometry of bones, ligaments, and tendons vary significantly both within an individual and from patient to patient, improvement of efficacy of the treatment is still necessary even after the treatment modality has been approved for clinical application.

Orthopedic surgeons often find better application methods or ideas in the clinic, during surgery, or during rehabilitation to improve a treatment modality. However, to refine, materialize, justify, and disseminate the new method or idea, basic research is usually required in addition to clinical outcomes research.

AN: You bring up an excellent point. In health care, we often talk about this concept of “bench to bedside.” But I think a lot of research at Rush comes about because something we see at the bedside or in the operating room (OR) prompts us to ask questions of the scientists and find those

“There are only so many patients you directly can treat, even over a lifetime. But if you understand things, and discover things, and teach other people things, you can really influence so many more people.”

– Craig J. Della Valle, MD

answers through research. So often, the research actually goes from bedside to bench.

For example, I do a lot of reconstructions of the spine. Sometimes a screw can loosen, or maybe a reconstruction is not healing as well as we'd like. We look at the problem, and then we might partner with our spine biomechanics experts like Dr Inoue to uncover the reason for the problem.

Another area that comes to mind is degenerative disc disease. Spine surgeons have some ways to tackle that problem, including fusion and minimally invasive procedures, but the outcomes are not as good as we would like.

So my colleagues and I started asking, what other ways might there be to treat that disease? Those discussions, years ago, led to a lot of the research we have done—and continue to do—looking at the pathogenesis, cellular mechanisms, and biological ways to rejuvenate or regenerate discs.

DELLA VALLE: As is the case in spine surgery, most of the research we do in joint replacement is in response to specific clinical scenarios or challenges that we face.

Because Rush is a tertiary care center, we see a lot of complex problems—and that's true for all of the orthopedic specialties, not just reconstructive surgery. This includes patients who had standard treatments at other hospitals that, for whatever reason, have failed. In some situations, there simply is not a good solution that we know of.

We're fortunate at Rush because we have the luxury of being able to subspecialize, and that often gives you more time to think about clinical problems.

In a given year, I might see 300-400 patients who need knee replacement and

another 300-400 who need their hips replaced. When I come across things that challenge me, or where I'm struggling to make the right decision, those are the areas where I might feel compelled to do research.

WIMMER: Down in the lab, we don't always know where this trail begins. Can you give an example?

DELLA VALLE: Well, we had a patient come in a couple of years ago about 4 to 5 weeks after knee replacement because there was concern that her knee was infected. I saw her with one of our fellows. I thought the wound looked fine. The patient's family, however, was concerned that there was an infection; another health care provider said it looked infected. So I aspirated the patient's knee, and we drew fluid, which is one of the standard ways we evaluate for infection.

When we get the fluid, we look at both the number and type of white blood cells. The

number we typically use to define infected is about 3000 white blood cells. For this patient, the fluid came back and had about 7000 white blood cells.

My fellow asked, "When are we bringing her back to the OR?" I asked why he wanted to do that, and he said, "There are 7000 white blood cells." I responded that it had been only a couple of weeks since surgery, and the fellow said, "So at what number *should* we take her back to the OR?" I said, "I don't know, but I don't think it's 7000."

My fellow then asked, "When I go out to practice in a couple of months, what number should I use?" Well, it was a really good question. Unfortunately, there was not a good answer. So that inspired us to look at the diagnosis of infection in the early postoperative period following both hip and knee replacement.

We did those 2 projects about 2 years apart, and both won clinical research awards, one



Craig J. Della Valle, MD.

from The Hip Society, one from The Knee Society. As usual, we found things along the way that we really didn't expect.

One of our most surprising findings had to do with a simple blood test we use to evaluate for infections, called a C-reactive protein. I never thought it would be a useful marker for infection early after surgery, but it turned out to be an extraordinarily good test for differentiating infected from non-infected. It provides an easy way for any orthopedic surgeon to get the information to *then* decide whether or not to draw fluid from the knee.

Patients don't like having a needle stuck in their knee, and there's always a small risk of creating a problem when you do a procedure like that. That blood test really helps us figure out when to draw fluid. Then, if we do draw fluid, we now have pretty good parameters for identifying whether or not the person needs to be treated for infection.

WIMMER: What did you discover was the *actual* white blood cell count to indicate infection?

DELLA VALLE: Ten thousand. And in terms of the type of white blood cells, we look at polymorphonuclear leukocytes, immune cells that help fight infection. A low level of these cells is generally an indicator of

acute inflammation and infection.

So if you're below 10 000 white blood cells and below 90% polymorphonuclear leukocytes, those are good indicators that everything is OK. If you're above those levels, you start getting concerned that there's infection.

COLE: Another goal of translational research is to assess whether a specific therapy is something we should be using at all. In sports medicine, we've come across a number of treatments that have actually had adverse effects on outcomes. So we dug deeper and looked at why. In some cases, we ended up eliminating technologies or procedures because we found they were unsafe or unpredictable.

One area that comes to mind is orthobiologics. Nonsurgical management of sports injuries has been popularized in the media and lay press, but a lot of the nonsurgical therapies have not been validated. We've investigated a number of technologies that have not yet been clinically adopted—that are not yet ready for prime time, so to speak—to try to determine their efficacy.

That has been the case with platelet-rich plasma. We're also doing some stem cell research now because it's becoming quite popular for various ailments—osteoarthritis, tendon problems, and so on.

But the reality is the research that's been done with stem cells is, in general, quite limited from both a clinical and a basic science perspective.

When all is said and done, we may find that stem cells are not as effective as other treatments, or that they work for some conditions but not others.

AN: I'd like to switch gears a bit and talk about one of the biggest hurdles to this type of research, something we are all dealing with—funding. In the old days, we relied primarily on National Institutes of Health grants. But NIH funding has been reduced, and it has become so competitive.

WIMMER: It's a huge challenge. Far more people are applying for NIH funding these days, so the rejection rate has just gone through the roof.

INOUE: Obtaining government funding now tends to require addressing fundamental research questions, rather than the clinical questions that orthopedic surgeons face in their daily clinical practice.

AN: So now we have to be more resourceful to get our projects funded.

INOUE: Yes, most of us have to rely on a combination of government grants and funding from other sources, such as industry, clinical societies, and philanthropy. We have always had these alternative sources, but today they represent a larger percentage of our total funding.

COLE: It used to be that we could spend a fair amount of time to secure large government grants and then focus on our work. Now, we spend more time getting small grants, which takes investigators away from what they do best. So we've become less efficient in trying to get funding. The sources have not dried up; but they have changed, and they are smaller in number.

WIMMER: And now the NIH wants to fund only research that is clinically meaningful. For example, our research in joint replacement, our metal-on-metal research, has been at a very high level scientifically. We've published in *Science*. This is important research.



But I couldn't convince the NIH that we should further this research, because clinically, these metal-on-metal joints had a bad track record. Although we'd love to continue this cutting-edge scientific research, it doesn't make any sense financially because we haven't secured the funding.

COLE: Fortunately, in many areas of orthopedics, grateful patients are often very forthcoming in helping support our research. They see that the decisions that were made in their care influenced their outcomes. So patient giving is really a win-win. Their gifts enable us to improve treatments, and they are the ones who stand to benefit most directly from our improved capabilities.

We're also able to get some smaller grants from the American Academy of Orthopaedic Surgeons, the governing body of orthopedics, as well as from a number of specialty societies.

Finally, there is industry. The challenge there is maintaining our independence—exploring issues that are meaningful to us personally—while coming up with projects that contribute to the literature. That said, industry funding has really enabled us to continue research efforts into devices and biologics that I think we otherwise wouldn't have been able to achieve.

DELLA VALLE: As much as industry funding is important and helpful, it's also nice to have those other sources, like philanthropy, because it gives us complete freedom to use the funds the way we think is best. We can have staff devote all of their energy to answering clinically relevant questions that we can then use to improve outcomes.

For instance, I had a very young woman who came into my office with a crippling problem that stemmed from an inherited immunodeficiency disorder. The woman and her family said that if our team thought there was a way to fix the problem, they wanted us to move ahead. So we did surgery on her. She had some hiccups along the way, but it went well.

About a year later, I got a message from the patient's dad. He said, "I can't believe how



well my daughter is doing. What can I do for you?" I told him we do a lot of research, and that I'd love to tell him more about our work.

That family has been extremely generous and has funded us for the last 5 to 6 years; their gifts have probably enabled my team to publish 30 papers, and about one-third of those papers have won some type of research award. A lot of people tend to read those award papers. So then that hopefully leads to more physicians being able to care for their patients better.

Industry and NIH funding come with strings attached. Philanthropic gifts give us the artistic freedom to work on what we want to work on and try to answer questions we think are clinically relevant.

WIMMER: For me, a big problem is that we have less preliminary funding. In the past, we would have been able to spend a lot more time on these projects in the early stages and, as a result, had more pilot data that we could use to then apply for NIH funding. Now we have to go to the NIH earlier, and our applications are less solid.

CHUBINSKAYA: That's true. For instance, when you're doing research with human samples, whether it's cadaveric samples or patient samples, it's very challenging because the population is very heterogeneous. So you need to have the right number of samples to achieve statistical significance, and you would need to do a lot of repeats of experiments. But if funding is limited, that's not possible.

COLE: That's where some of the society awards can help, like the Kappa Delta Awards and Orthopaedic Research and Education Foundation Clinical Research Awards that AAOS gives annually.

Although they are relatively small, they can enable an investigator to do the preliminary work to become more competitive for NIH funding.

AN: I have to say, though, that despite the increased funding challenges, I'm very proud of how productive we are in our department.

We can't predict or control what industry or the government will do. But it's because of the collaboration between scientists and clinicians that we're able to achieve a lot of answers and continue to advance orthopedic care. I think that's an important point to make.

COLE: That's so true. As a clinician—and especially as a surgeon—it would be easier in terms of the demands on your time to *not* have an interest in research and *not* prioritize it. Because you can't just come up with an idea and hand it off. The kind of research we do requires active delegation and participation.

I think that's why we've been so successful here. Most of the clinicians in our department are willing to dedicate their time and energy to research. And both clinicians and researchers are willing to meet face to face, walk through problems, and work together to figure out solutions.

We are like minded, have similar goals, and collaborate extremely well.

CHUBINSKAYA: Driving in to work today, I was thinking about my professional relationship with Dr Cole. How old is your daughter, Brian?

COLE: She's 10.

CHUBINSKAYA: She just turned 10 in August, right?

COLE: Right.

CHUBINSKAYA: That's when we started working together: a decade ago.


COLE: It's pretty amazing. If you look at all of the different sections within the Department of Orthopedic Surgery and asked how many research projects are partnerships between physicians and basic scientists, it's got to be at least half the publications.

We do a lot of clinical research, but the best research we do is the collaborative research. That's what gets the most attention, but more important, it's what has the most significant impact on patient care.

DELLA VALLE: I work a lot with the Robbins and Jacobs Family Biocompatibility and Implant Pathology Laboratory and the Biomaterials Laboratory. A big part of my practice is revisions, and we take very seriously that the scientists need those clinical samples, those retrievals from the OR, to evaluate.

Whenever I'm revising a failed hip that has an interesting pathology, we try to get samples of that tissue and fluid, as well as the implants themselves, to Bob Urban, who heads up the biocompatibility and implant pathology lab, and Nadim Hallab, director the biomaterials lab. They've been able to use those tissues to better understand some interesting modes of implant failure.

Of course, it would be difficult for me to leave the OR to bring them that sample. But I have a full-time research fellow who comes to the OR, and we give him the samples hot off the press. He takes them



directly to the basic scientists so they can process, store, and study.

CHUBINSKAYA: Providing samples is only part of your involvement with research, though. It's an important part. But unlike many other institutions where clinicians give a specimen to researchers and say, "Do whatever you want with it" without contributing intellectually, here clinicians and scientists have harmonious relationships on multiple levels.

We [clinicians and scientists] really are equal contributors to many, many projects. The clinician does not simply identify a problem and then just hand it off. So that is unique.

DELLA VALLE: That's true. I'm very hands on, and all of the research I do is clinically relevant. I'm looking for answers to problems I see with my patients, either in the operating room or the clinic. If I'm seeing these problems and struggling with these decisions, I'm sure there are other surgeons who are in the same boat. And we try to tackle those problems.

Often, people ask why I study all these complications and infections, stuff most surgeons don't want to investigate. It's because it's challenging to me that things are difficult. Trying to understand these types of problems and come up with better ways to identify and treat them, it helps me. And if it helps me, it should help other doctors and their patients.

CHUBINSKAYA: We are invested in each other's careers and success. We are not just colleagues; over the years, we have become friends.

INOUE: I agree we have an excellent team here, and that's quite rare. And you know, what is also unique is how many research specialists we have here.

I have experienced both the clinical and basic research sides of orthopedic surgery, so that gives me a somewhat unique perspective. I spent 11 years as division chief of the fracture service at a university hospital in Kyoto before I moved to Johns Hopkins in 1992 to be a researcher, which is also my role at Rush.

At Johns Hopkins, I used to have to work in many different areas—mechanical testing, imaging, animal studies, and even histology—because there was a limited number of specialists in biomechanics. Here, I don't need to work on histology because there are histology specialists. With so many research specialists, I can concentrate on only what I'm interested in.

COLE: You get to do what you do best.

INOUE: Right. And all of the laboratories are on the same floor, so all of the scientists can communicate very easily. But just as important, the clinicians are also in the same building. They are right upstairs, so it's easy if I have a question for them,

“In health care, we often talk about the concept of ‘bench to bedside.’ But I think a lot of research at Rush comes about because something we see at the bedside or in the operating room prompts us to ask questions of the scientists and find those answers through research.”

– Howard S. An, MD

or they have one for me. We can meet face to face without having to travel across campus.

WIMMER: It seems the department as a whole has more of a matrix structure rather than just being divided up by area.

We do have the clinical subspecialties: sports medicine; adult reconstructive surgery; pediatric orthopedic surgery; orthopedic oncology; foot and ankle; hand, wrist and elbow; hip and knee; and spine. But there is a lot of overlap, and then the researchers are somewhat spread throughout.

I, for instance, don't just belong to hip and knee replacement. My labs also do cartilage work and kinematic studies in the spine. I think having the specialties linked to some extent—clinically and especially on the research side—makes the department stronger.

AN: I agree. What's nice is that we hold weekly spine section meetings, but then we also have weekly grand rounds that include all of the orthopedic subspecialties, and all

of the section directors meet monthly. So we interact with each other quite a bit on a regular basis. My fellow spine surgeons and I have opportunities to see what our colleagues in other areas are working on, and they get to hear what's new in spine surgery.

DELLA VALLE: And it's not just interacting in meetings. When I'm facing a clinical problem or have an idea, I know there are many people within our department I can go to for feedback. That includes the other surgeons within my section, my colleagues from other orthopedic specialties, and our basic scientists.

All three of those avenues can lead to significant changes in patient care, where we actually find a novel solution or even start to go in a different direction, down another pathway that enables us to treat the problem even more effectively.

COLE: That's definitely a huge benefit, and being in close proximity is really important. But also having clinicians who are willing

to stop what they're doing and address research-related issues almost on the fly makes a big difference. Sometimes, research questions truly can't wait. And I think our physicians do a good job of prioritizing our research and clinical obligations.

AN: Our department leadership has always emphasized the importance of research. Our chairmen, both past and present, not only enable but encourage our faculty to make research a high priority. That is one of the reasons we are able to devote so much time and energy to it.

COLE: It's not always easy, and it's not a knock on those who choose not to focus on research. The time a physician spends on research is uncompensated. And if you look at the pressures on clinicians, while many have the aspirations to be engaged in research, they may be hampered by the demands of their practices. Or, often, their institutions simply don't afford them the ability to do so.


DELLA VALLE: Many of us chose to practice here in part because we wanted to do research, not just operate.

CHUBINSKAYA: The research is an intellectual challenge. It's what makes it exciting to come to work. I'm not saying surgery isn't intellectually challenging—

COLE: It is. But performing operations is a commodity. It's the other stuff that differentiates you as an orthopedic surgeon. It's decision making.

I can tell you that most of the research I've done has helped my decision making in the office, when I'm talking to patients. They ask what they can expect, and I can tell them, “Well, this is what you can expect because we've looked at the clinical outcomes.” I can tell them what something looks like histologically. I can tell them





what it will look like biomechanically, with some degree of predictability. Not every surgeon has the resources to do this.

People will ask me, “Why do you spend so much time doing research?” I think it makes me a far better clinician because I’m more engaged. And I think most of my partners feel the same way. It helps create a life balance. We can always be better physicians, but the ability to have this kind of balance is not something you can find everywhere.

DELLA VALLE: My uncle was a basic science guy. He knew when I was in high school that I liked science. When I was in college, I did some research in a lab, and then I worked with both physicians and PhDs.

When I told my uncle I was thinking about going into medicine, he said, “Going to medical school and being a doctor is fine. But if you *really* want to help people, remember to do research. There are only so many patients you directly can treat, even over a lifetime. But if you understand things, and discover things, and teach other people things, you can really influence health care and help so many more people.”

That’s why I spend so much of my time doing research. It’s important, and it has the potential to improve care not only for our patients at Rush, but for patients around the country and around the globe.

CHUBINSKAYA: We see examples all the time of how our research is actually helping people, making their lives better. We just

had an experience several months ago with one of Dr Cole’s patients. This young girl went through so much suffering, and now she’s doing great.


COLE: She had an osteochondral allograft implantation. Her story is really compelling.

CHUBINSKAYA: We were trying to explain to her the specific research we are doing with allografts, and how what we learned tied into the procedure that was done to her. I don’t know how much she understood, but you could see the sparks and excitement. I wouldn’t be surprised if she ends up pursuing a career in orthopedics because of her experience.

COLE: I have dozens of young people who end up going into medicine because of their experiences with injuries or health conditions in their youth. This girl was only 18 when she first came to see me, but she’d already had 20 surgical procedures. She had given up sports and exercise. It was heartbreaking.

WIMMER: The point is not just that we were able to treat her, or that she had an excellent outcome. It is how much translational research—how many different studies—led up to the 45-minute operation Dr Cole performed to implant an osteochondral allograft in this patient.

COLE: The procedure itself was relatively routine. But that was not the case with making the decision to do it: Why did we decide to use this procedure vs. another? Because we had data that showed it was the best option for her; we’ve shown there’s a 72% graft survival rate at 10 years.

Echoing what Dr Wimmer just said: When you consider the scope of research that ends up going into not just this case, but every case, how many people are involved? To be honest, the most trivial part is surgically implanting the graft. 

See the article on page 12 to read more of how 10 years of translational research at Rush helped give this young patient her life back.



“Midwest Orthopaedics at Rush specialists are leading the way in the development and refinement of cutting-edge treatments that benefit patients at Rush—and around the globe.”



A Tradition of Excellence

Midwest Orthopaedics at Rush (MOR) is a private practice medical group whose fellowship-trained physicians are on the faculty of Rush University Medical Center in Chicago. With MOR based primarily at Rush, our renowned surgeons and physicians have access to all the resources of a world-class academic medical center, including the state-of-the-art operating rooms in Rush's new hospital.

Throughout MOR's history, our surgeons and physicians have been on the cutting edge of orthopedic care, pioneering a number of the procedures and therapies

used to treat patients today—from cementless implants, to minimally invasive surgery for spinal deformities and degenerative disk disease, to expandable prosthetics that help children with bone cancers avoid amputation. That spirit of innovation continues today, as MOR specialists are leading the way in the development and refinement of advanced treatments that benefit patients at Rush—and around the globe.

Physicians from MOR also hold key leadership positions in national societies and organizations. An example is Joshua

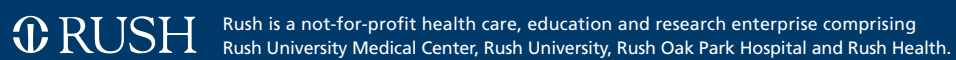
J. Jacobs, MD, who is the 2013-14 past president of the American Academy of Orthopaedic Surgeons. MOR physicians also serve as the team physicians for a variety of professional, collegiate, and high school teams and clubs, such as the Chicago Bulls, Chicago White Sox, Chicago Fire, and DePaul University.

These impressive clinical, research, and administrative activities distinguish the orthopedics program at Rush as one of America's best. In 2015, *U.S. News & World Report* ranked our program No. 6 in the nation.



Midwest Orthopaedics at Rush

Chicago, IL • Oak Park, IL • Westchester, IL • Winfield, IL
(877) MD-BONES (632-6637) / www.rushortho.com



PLEASE NOTE: All physicians featured in this publication are on the medical faculty of Rush University Medical Center. Many of the physicians featured are in the private practice Midwest Orthopaedics at Rush and, as independent practitioners, are not agents or employees of Rush University Medical Center.